

Central Lancashire Online Knowledge (CLoK)

Title	Hyperkeratosis in potentially malignant disorder management - 'guilty... until proven innocent!'
Type	Article
URL	https://clock.uclan.ac.uk/29083/
DOI	https://doi.org/10.1308/rcsfdj.2019.103
Date	2019
Citation	Crean, Stjohn and Thomson, Peter (2019) Hyperkeratosis in potentially malignant disorder management - 'guilty... until proven innocent!'. Faculty Dental Journal, 10 (3). pp. 103-108. ISSN 2042-6852
Creators	Crean, Stjohn and Thomson, Peter

It is advisable to refer to the publisher's version if you intend to cite from the work.
<https://doi.org/10.1308/rcsfdj.2019.103>

For information about Research at UCLan please go to <http://www.uclan.ac.uk/research/>

All outputs in CLoK are protected by Intellectual Property Rights law, including Copyright law. Copyright, IPR and Moral Rights for the works on this site are retained by the individual authors and/or other copyright owners. Terms and conditions for use of this material are defined in the <http://clock.uclan.ac.uk/policies/>

Hyperkeratosis in Potentially Malignant Disorder Management - ‘Guilty...until Proven Innocent!’

StJohn Crean

Pro Vice Chancellor (Clinical and Health), Professor of Medicine in Dentistry,
University of Central Lancashire, Preston PR1 2HE

Peter Thomson

Clinical Professor in Oral & Maxillofacial Surgery, Faculty of Dentistry,
The University of Hong Kong, Hong Kong SAR, China

E: thomsonp@hku.hk

Keywords: Oral Potentially Malignant Disorders, Diagnosis, Hyperkeratosis

Introduction

Oral potentially malignant disorders (PMD) are clinically recognisable mucosal abnormalities that share an increased risk of squamous cell carcinoma (SCC) development. Although comprising both localized lesions and more generalized conditions, the majority present clinically as oral leukoplakia at ventro-lateral tongue, floor of mouth and buccal mucosal sites¹. Confusion and potential inaccuracy in using clinically descriptive terms such as leukoplakia to establish PMD diagnosis is an increasingly recognised problem, however². In general, PMD are characterised microscopically by the presence of variably disorganised epithelial tissue change, varying from initial hyperplasia through to more significant dysplasia graded into increasingly severe categories; Table 1^{1,3}. Whilst it is generally assumed that the risk of malignant transformation (MT) is highest for more severely dysplastic tissue, this is not exclusively so and SCC can arise in lesions with minimal or even no pre-existing dysplastic change^{1,4}.

Risk assessment for individual patients presenting with PMD remains challenging in clinical practice. Whilst highly variable MT rates are quoted in the literature, systematic review has suggested an overall SCC development risk of 12% although this is mostly applicable to lesions exhibiting dysplasia⁵. As the natural history of PMD remains unpredictable, contemporaneous PMD management is based upon incision biopsy for provisional histological assessment and dysplasia grading followed by surgical excision to facilitate definitive diagnosis and treatment of lesions deemed 'high-risk'^{3,6,7}.

Whilst this treatment approach has proved both reliable and efficacious³, the authors of this paper remain concerned about those clinically suspicious oral lesions initially deemed innocuous by incision biopsy that subsequently progress to invasive SCC. This can only be considered a significant and potentially life-threatening failure in PMD management. Although for many years an alarming yet anecdotal observation, this scenario was specifically confirmed in a paper by Goodson et al⁴ which demonstrated that the majority of previously recognised precursor lesions progressing to SCC showed no histopathological evidence of dysplasia on incision biopsy, with 23 out of the 58 transforming lesions (40%) exhibiting only hyperkeratosis or lichenoid inflammation (LI).

How significant then should one regard a histopathological diagnosis of hyperplasia, hyperkeratosis or LI during PMD diagnosis and management? Strictly speaking, hyperplasia refers to epithelial thickening caused by an increase in the number of component cells due to an enhanced proliferation rate, whilst hyperkeratosis describes the histological appearance resulting from excessive, superficial keratin accumulation. Often these occur concurrently, and may be caused by genetic, physiological, inflammatory or dysmaturation processes. Whilst reactive lesions are most common, and their aetiological factors can be recognized and addressed, clinical examination alone is inadequate to distinguish a benign, reactive process from early dysplastic change⁸. Figure 1 illustrates the clinical appearance of hyperkeratosis due to local frictional irritation and contrasts this with leukoplakia resulting from an underlying epithelial dysplasia. Adding to the diagnostic confusion are solitary oral lichenoid lesions (OLL), characterized by the presence of lichenoid inflammatory change subjacent to hyperplastic or dysplastic epithelium, and multi-focal white lesions exhibiting both verrucous epithelial hyperkeratosis and LI forming part of the spectrum of proliferative verrucous leukoplakia (PVL)⁹.

In a previous study of 590 PMD patients undergoing standardised interventional treatment, we documented incision and excision biopsy diagnoses and compared the results with clinical outcome data to try to determine the reliability of pre-operative histopathological assessment⁷. Importantly, in 220 cases (36.1%) excision specimens had to be 'up-graded' from their initial incision biopsy diagnosis because of the identification of more severe dysplasia (n = 121, 19.9%) or SCC (n = 99, 16.2%)⁷. The specific aim of this current paper was to re-visit these original data, and to review the histopathology and clinical course for PMD lesions initially diagnosed as 'simple' hyperkeratosis.

Method

Initial Caldicott Approval from Newcastle University / Newcastle upon Tyne Hospitals NHS Foundation Trust facilitated anonymized, retrospective data collection from medical records, operating books and original pathology reports from PMD patients treated by CO₂ laser surgery by one of the authors (PJT) at the Royal Victoria Infirmary Maxillofacial Unit between August 1996 and December 2014. Inclusion criteria

required new patients who presented with single-site disease. Recorded demographic and clinico-pathological data included: patient age and sex, appearance and site of presenting PMD, and both incision and excision biopsy histopathology diagnoses. Clinical outcome was classified as: disease free, presence of further PMD disease or MT at the study census date (31.12.14).

All biopsies and CO₂ laser surgeries were carried out by PJT, or colleagues working under direct supervision, to established guidelines and within 6 to 12 weeks of initial presentation to prevent the risk of disease progression. Formalin-fixed tissue specimens were assessed via standardized histopathology examination by specialist oral pathologists, using agreed diagnostic criteria, peer review and consensus grading. The World Health Organization (WHO) system was used and dysplasia classified as mild, moderate and severe or carcinoma-in-situ. Diagnoses of hyperkeratosis, LI, and PVL were made as appropriate¹⁰.

The 590 PMD cohort database was used to identify all patients initially characterised by incision biopsy diagnosis as hyperkeratosis (with no evident dysplasia) and their detailed clinico-pathological profile reviewed.

Results

In total, 58 of the 590 PMD patient cohort (9.8%) met the study criteria: 17 (2.9%), comprising 9 male and 8 female patients with a mean age of 60.9 years, were diagnosed as hyperkeratosis following incision biopsy, with a further 41 patients (6.9%), 15 male and 26 female (mean age 59.4 years), designated as hyperkeratosis with additional features of LI; full demographic and definitive diagnostic data for these cases are listed in Tables 2 and 3. All lesions initially presented as leukoplakia, and their anatomical site origins are summarized in Table 4; hyperkeratosis was identified at ventro-lateral tongue and floor of mouth sites in 9 patients (52.9%), whilst buccal mucosa, labial commissure, alveolus and gingiva were more frequently the site of hyperkeratotic lesions with lichenoid inflammatory features (26 cases or 63.4%).

By listing definitive histopathological diagnoses from surgical excision biopsies against their initial incision biopsy data, Table 5 demonstrates that only 7 of the 17 cases

(41.2%) of hyperkeratosis were subsequently confirmed, with 10 requiring up-grading to more significant disease including 5 dysplasia (29.4%) and 2 SCC (11.8%); 5 of the 7 cases (71.4%) arose on the ventro-lateral tongue and the floor of the mouth. Table 6 similarly highlights that 25 out of 41 hyperkeratosis with LI cases (61%) were confirmed upon definitive diagnosis, whilst 14 exhibited dysplasia or carcinoma-in-situ (34.1%) and 1 SCC (2.4%); 10 of the 15 (66.6%) arose at ventro-lateral tongue or floor of mouth sites.

Table 7 summarizes clinical outcome data, showing that in total 44 patients (75.9%) were rendered disease free following laser treatment with only 3 instances of MT (5.2%), consistent with previous reports of treatment efficacy and similar for both categories of hyperkeratoses^{7,11}. The only notable difference in outcome was the higher incidence of further PMD disease affecting 10 patients (24.4%) with lichenoid inflammatory lesions, compared to 1 (5.9%) with hyperkeratosis only.

Discussion

Oral carcinogenesis is a complex and multi-step process, based fundamentally upon an increase in cellular proliferation and tissue hyperplasia, resistance to growth inhibition and apoptosis, and ultimate progression towards an invasive and metastatic phenotype¹. It seems clear from the results of this investigation that a diagnosis of hyperkeratosis or hyperplasia, taken from incision biopsy sampling of a clinically suspicious PMD lesion, cannot exclude progression to subsequent MT. This is a significant observation, particularly as 'epithelial hyperkeratosis' is known to be one of the commonest diagnoses made within specialist oral medicine practice⁸. Whilst it is recognised that dysplasia grading can be subjective and imprecise, and that non-representative biopsies and a change in dysplasia severity over time may confound diagnostic accuracy, these factors alone are insufficient to explain the results of the 58 standardized cases analysed in this paper in which initial biopsies clearly underestimated both severity and progress of existing PMD disease.

It has been suggested that up to half of clinically apparent leukoplakias may not exhibit dysplasia on biopsy and are often diagnosed as 'non-specific' or 'simple'

hyperplasia¹². SCC development from non-dysplastic leukoplakia or 'benign' hyperkeratosis has been reported before, albeit somewhat anecdotally in a number of studies, affecting between 2 to 30% of cases¹³. The dilemma for clinicians is whether such lesions represent the initial stage of a progressive dysmaturation process that inevitably leads to carcinogenesis. On the basis of the evidence presented in this study, this must be considered the most likely scenario, especially in the absence of clinically demonstrable external irritants.

In general, optimal patient assessment and accurate PMD diagnoses require careful consideration of both clinical and histopathological data. There is no substitute for clinical experience, acumen and a high level of suspicion during individual lesion assessment, and detailed communication between clinicians and pathologists is mandatory to assimilate these data fully and inform management decisions¹³. Despite inherent limitations, oral epithelial dysplasia grading remains the 'reference' investigation in contemporary patient management, and is one of very few agreed assessment tools in estimating MT risk^{6,12}.

Oral premalignant conditions are associated with a number of molecular alterations. Included in these are genetic changes associated with, amongst many others, chromosomes 3p and 9p (short arms). These sub cellular changes have the potential to act as relevant indicators/biomarkers when aligning histopathological changes, such as hyperkeratosis and hyperplasia, to long term outcomes and whether they reflect predictable changes toward a more aggressive endpoint.

Changes on chromosome 3p, have been the focus of a number of studies involving PMLs. Interest has arisen due to their identification, not only in invasive SCCs but also within low grade lesions deemed at risk of progression¹⁴. Alterations (losses or additions) in as many as six regions of 3p have been demonstrated including the loss of the FHIT gene, proposed as a tumour suppressor gene, whose loss is associated strongly with development and prognosis of head and neck cancers¹⁵. The alterations in chromosome 3p loci have been shown to be shared not only between high grade oral dysplastic tissue and carcinoma, but also with low grade histologically altered tissues that subsequently progressed to higher grade lesions. These 6 regions of alterations have been shown to contain up to 141 genes of which 9 have identified tumour suppressor activity¹⁴.

Similarly, chromosome 9p changes have also been associated with premalignant tissue such as leucoplakia. Whilst the “journey” from non-malignant to malignant change has been difficult to confirm with confidence, the associations with the loss of genetic material (allelic loss) and loss of heterozygosity, are indicative of the likelihood of histologic progression from a premalignant status ¹⁶.

A range of cyto/molecular changes have been associated with PMLs, including insertion or deletion of microsatellite base pairs (microsatellite Instability MSI), chromosomal aneuploidy e.g. trisomy of chromosome 9 (although a less certain prognostic indicator as once previously thought), increased telomerase activity, P53 alterations, a possible role for mitochondrial DNA changes and epigenetic alterations such as hyper-methylation of key promoter regions ¹⁶.

Which of these factors plays an upstream role and under which circumstances, is the focus of ongoing research, but it is clear that receiving a diagnosis of hyperplasia and/or hyperkeratosis, needs to be referenced against an activation of a range of sub cellular changes, in response to known risk factors, that may indicate further progression towards a more sinister outcome.

Until the “biomarker” led indicators can help us with accurate prognostic indicators then patient observational studies such as this one, therefore, offers some of the best currently available insights into the natural history of PMD¹⁷.

Despite the identification of significant dysplasia and occult SCC within presenting PMD in this study, it is encouraging to note that 75% of patients were disease free at the study census date; this observation is probably a testimony to the efficacy of interventional laser surgery, which has been demonstrated to improve diagnostic accuracy and deliver reliable PMD treatment^{7,11,18,19}. There is probably no more important issue in PMD diagnosis and management, however, than the development of invasive SCC, and MT was seen in 3 patients (5.2%) during this study. Whilst the implications of SCC development can be devastating, we have previously demonstrated significant benefit, in terms of improved long-term prognosis and disease-free survival, when early invasive SCCs were fortuitously removed during the laser excision of PMD²⁰.

Despite controversies in diagnosis and terminology, up to 29% of PMD have been shown to exhibit features of LI or PVL on histopathological assessment, with such

lesions appearing primarily as leukoplakia on the ventro-lateral tongue, floor of mouth, labio-buccal mucosa and gingiva^{7,9}. Whether OLL and PVL are discrete examples of PMD or represent a progressive disease continuum is unclear, but a high MT risk has been reported for both multi-focal PVL and isolated tongue OLL, usually in the absence of pre-existing dysplasia²¹.

Conclusions

A provisional diagnosis of hyperkeratosis or LI from incision biopsy sampling of a clinically suspicious PMD lesion is not an 'innocent' finding, and lesions should not be considered 'benign'. Clinician experience and judgement, together with effective communication with specialist pathologists, remain fundamental for accurate assessment and effective management of newly presenting PMD. Formal excision biopsy of oral mucosal lesions is therefore recommended to facilitate both definitive diagnosis and effective treatment.

References

1. Thomson PJ. Oral Carcinogenesis. In: PJ Thomson (ed) *Oral Precancer – Diagnosis and Management of Potentially Malignant Disorders*. Chichester: Wiley-Blackwell; 2012. p31-47.

2. Thomson PJ. Oral potentially malignant disorders- What's in a name? *Faculty Dental Journal* 2019 (In Press).
3. Thomson PJ. Potentially Malignant Disorders – The Case for Intervention. *Journal of Oral Pathology & Medicine* 2017 **46**: 883-887.
4. Goodson ML, Sloan P, Robinson CM, Cocks K, Thomson PJ. Oral Precursor Lesions and Malignant Transformation – Who, Where, What and When? *British Journal of Oral & Maxillofacial Surgery* 2015 **53**: 831-835.
5. Mehanna HM, Rattay T, Smith J, McConkey CC. Treatment and follow-up of oral dysplasia – a systematic review and meta-analysis. *Head & Neck* 2009 **31**: 1600-1609.
6. Thomson PJ. Managing oral potentially malignant disorders: A question of risk. *Faculty Dental Journal* 2015 **6**: 186-191.
7. Thomson PJ, Goodson ML, Cocks K, Turner JE. Interventional laser surgery for oral potentially malignant disorders: a longitudinal patient cohort study. *International Journal of Oral & Maxillofacial Surgery* 2017 **46**: 337-342.
8. Farah CS, Simanovic B, Savage NW. Scope of practice, referral patterns and lesion occurrence of an oral medicine service in Australia. *Oral Diseases* 2008 **14**: 367-375.
9. Thomson PJ, Goodson ML, Smith DR. Potentially Malignant Disorders Revisited – The Lichenoid Lesion / Proliferative Verrucous Leukoplakia Conundrum. *Journal of Oral Pathology & Medicine* 2018 **47**: 557-565.
10. Sloan P. Pathological aspects of oral precancer. In P J Thomson (Ed) *Oral Precancer – Diagnosis and Management of Potentially Malignant Disorders*. Wiley-Blackwell 2012. p93-106. ISBN 978-1-4443-3574-3.
11. Diajil AR, Robinson CM, Sloan P, Thomson PJ. Clinical outcome following oral potentially malignant disorder treatment: a 100 patient cohort study. *International Journal of Dentistry* 2013 Article ID 809248, 8 pages <http://dx.doi.org/10.1155/2013/809248>.
12. Speight PM. Update on oral epithelial dysplasia and progression to cancer. *Head and Neck Pathology* 2007 **1**: 61-66.
13. Farah CS, Woo S, Zain RB, Sklavounou A, McCullough MJ, Lingen M. Oral cancer and potentially malignant disorders. *International Journal of Dentistry* 2014 Article ID 853479, 6 pages <http://dx.doi.org/10.1155/2014/853479>.
14. Tsui IF, Rosin MP, Zhang L, Ng RT, Lam WL. Multiple aberrations of chromosome 3p detected in oral premalignant lesions. *Cancer Prev Res (Phila)*. 2008;1(6):424-9.
15. Lee JI, Soria JC, Hassan K, et al. Loss of Fhit expression is a predictor of poor outcome in tongue cancer. *Cancer Res*. 2001;61:837–41.

16. Mithani SK, Mydlarz WK, Grumbine FL, Smith IM, Califano JA. Molecular genetics of premalignant oral lesions. *Oral Dis.* 2007 Mar;13(2):126-33. Review. PubMed PMID: 17305612.
17. Thomson PJ, Wylie J. Interventional laser surgery: an effective surgical and diagnostic tool in oral precancer management. *International Journal of Oral & Maxillofacial Surgery* 2002 **31**:145-153.
19. Thomson PJ. The role of interventional surgery in oral potentially malignant disorders. *Faculty Dental Journal* 2014 **5**: 84-89.
20. Thomson PJ, Goodson ML, Smith DR. Profiling Cancer Risk in Oral Potentially Malignant Disorders – A Patient Cohort Study. *Journal of Oral Pathology & Medicine* 2017 **46**: 888-895.
21. Thomson PJ, Goodson ML, Smith DR. Potentially Malignant Disorders Revisited – The Lichenoid Lesion / Proliferative Verrucous Leukoplakia Conundrum. *Journal of Oral Pathology & Medicine* 2018 **47**: 557-565.
15. Greaney L, Brennan PA, Kerawala C, Cascarini L, Godden D, Coombes D. Why should I follow up my patients with oral lichen planus and lichenoid reactions? *British Journal of Oral & Maxillofacial Surgery* 2014 **52**: 291-293.

TABLES

Table 1: Histopathological Classification of Epithelial Disorganisation in PMD

Grade	Epithelial Disorganisation
Hyperplasia	Hyperkeratosis, Epithelial Thickening, Normal Maturation
Mild Dysplasia	Primarily Basal Cell Hyperplasia affecting Lower 1/3 rd Epithelium
Moderate Dysplasia	Disordered Maturation spreading to Middle 1/3 rd Epithelium
Severe Dysplasia	Disordered Maturation reaching Upper 1/3 rd Epithelium
Carcinoma-in-Situ	Full Thickness Dysmaturation & Disorganisation

Table 2: Age, Sex, Site, Definitive Diagnoses & Outcome for PMD Patients initially diagnosed with 'Hyperkeratosis' (No = 17)

Age	Sex	Lesion Site	Definitive Diagnosis	Clinical Outcome
71	F	Buccal Mucosa	SCC	Malignant Transformation

69	M	Ventral Tongue	SCC	Malignant Transformation
63	M	Lateral Tongue	Proliferative Verrucous Leukoplakia	Disease Free
65	M	Floor of Mouth	Mild Dysplasia	Disease Free
51	F	Buccal Mucosa	Hyperkeratosis + Lichenoid Inflammation	Disease Free
57	M	Ventral Tongue	Mild Dysplasia	Disease Free
57	M	Palate	Mild Dysplasia	Disease Free
58	M	Labial Mucosa	Hyperkeratosis	Disease Free
77	F	Lateral Tongue	Hyperkeratosis	Disease Free
59	F	Palate	Hyperkeratosis	Further Disease
62	M	Ventral Tongue	Hyperkeratosis	Disease Free
49	F	Lateral Tongue	Mild Dysplasia	Disease Free
56	M	Floor of Mouth	Hyperkeratosis	Disease Free
57	F	Labial Commissure	Hyperkeratosis	Disease Free
67	M	Palate	Hyperkeratosis	Disease Free
64	F	Alveolus	Proliferative Verrucous Leukoplakia	Disease Free
53	F	Lateral Tongue	Moderate Dysplasia	Disease Free

Table 3: Age, Sex, Site, Definitive Diagnoses & Outcome for PMD Patients initially diagnosed with ‘Hyperkeratosis + Lichenoid Inflammation’ (No = 41)

Age	Sex	Lesion Site	Definitive Diagnosis	Clinical Outcome
42	F	Alveolus	Hyperkeratosis + Lichenoid Inflammation	Further Disease

65	M	Buccal Mucosa	Hyperkeratosis + Lichenoid Inflammation	Disease Free
44	M	Lateral Tongue	Severe Dysplasia	Further Disease
68	F	Lateral Tongue	SCC	Malignant Transformation
70	M	Floor of Mouth	Mild Dysplasia	Disease Free
43	M	Floor of Mouth	Mild Dysplasia	Further Disease
65	F	Alveolus	Hyperkeratosis + Lichenoid Inflammation	Disease Free
56	M	Lateral Tongue	Mild Dysplasia	Disease Free
62	F	Ventral Tongue	Moderate Dysplasia	Disease Free
73	F	Lateral Tongue	Hyperkeratosis + Lichenoid Inflammation	Disease Free
50	F	Palate	Hyperkeratosis + Lichenoid Inflammation	Disease Free
54	F	Gingiva	Hyperkeratosis + Lichenoid Inflammation	Disease Free
60	M	Lateral Tongue	Moderate Dysplasia	Disease Free
51	F	Gingiva	Hyperkeratosis + Lichenoid Inflammation	Disease Free
55	F	Lateral Tongue	Hyperkeratosis + Lichenoid Inflammation	Disease Free
74	F	Gingiva	Hyperkeratosis + Lichenoid Inflammation	Disease Free
78	F	Buccal Mucosa	Hyperkeratosis + Lichenoid Inflammation	Disease Free
55	F	Lateral Tongue	Mild Dysplasia	Disease Free
65	F	Gingiva	Hyperkeratosis + Lichenoid Inflammation	Disease Free
49	M	Labial Commissure	Mild Dysplasia	Further Disease
57	F	Gingiva	Hyperkeratosis + Lichenoid Inflammation	Further Disease
62	M	Labial Commissure	Chronic Hyperplastic Candidosis	Disease Free
51	M	Buccal Mucosa	Hyperkeratosis + Lichenoid Inflammation	Further Disease
53	F	Gingiva	Hyperkeratosis + Lichenoid Inflammation	Disease Free
52	F	Palate	Mild Dysplasia	Disease Free
63	F	Gingiva	Hyperkeratosis + Lichenoid Inflammation	Disease Free
70	M	Buccal Mucosa	Mild Dysplasia	Further Disease
83	F	Buccal Mucosa	Hyperkeratosis + Lichenoid Inflammation	Further Disease
41	F	Buccal Mucosa	Hyperkeratosis + Lichenoid Inflammation	Disease Free
42	M	Floor of Mouth	Mild Dysplasia	Disease Free

63	F	Alveolus	Hyperkeratosis + Lichenoid Inflammation	Further Disease
60	F	Alveolus	Hyperkeratosis + Lichenoid Inflammation	Further Disease
79	F	Buccal Mucosa	Hyperkeratosis + Lichenoid Inflammation	Disease Free
64	F	Buccal Mucosa	Hyperkeratosis + Lichenoid Inflammation	Disease Free
60	F	Alveolus	Hyperkeratosis + Lichenoid Inflammation	Disease Free
61	F	Alveolus	Hyperkeratosis + Lichenoid Inflammation	Disease Free
50	F	Floor of Mouth	Hyperkeratosis + Lichenoid Inflammation	Disease Free
58	M	Lateral Tongue	Carcinoma-in-Situ	Disease Free
52	M	Labial Commissure	Hyperkeratosis + Lichenoid Inflammation	Disease Free
60	M	Buccal Mucosa	Mild Dysplasia	Disease Free
77	M	Buccal Mucosa	Mild Dysplasia	Disease Free

Table 4: Site of Presenting Lesion

Anatomical Site	Hyperkeratosis No (%)	Hyperkeratosis + Lichenoid Inflammation No (%)
Buccal/Labial Commissure	4 (23.5%)	13 (31.7%)

Ventral Tongue/Floor of Mouth	5 (29.4%)	5 (12.2%)
Lateral Tongue	4 (23.5%)	8 (19.5%)
Palate	3 (17.6%)	2 (4.9%)
Alveolus/Gingiva	1 (5.9%)	13 (31.7%)
TOTAL	17 (100%)	41 (100%)

Table 5: Definitive Histopathological Diagnoses for Hyperkeratosis following Laser Excision Biopsy (Total No = 17)

<i>Definitive Diagnosis</i>	<i>Number (%)</i>
Hyperkeratosis	7 (41.1%)
Hyperkeratosis + Lichenoid Inflammation	1 (5.9%)
PVL	2 (11.8%)
Mild Dysplasia	4 (23.5%)
Moderate Dysplasia	1 (5.9%)
Severe Dysplasia	0 (0%)
Carcinoma-in-Situ	0 (0%)
SCC	2 (11.8%)

Table 6: Definitive Histopathological Diagnoses for Hyperkeratosis + Lichenoid Inflammation following Laser Excision Biopsy (Total No = 41)

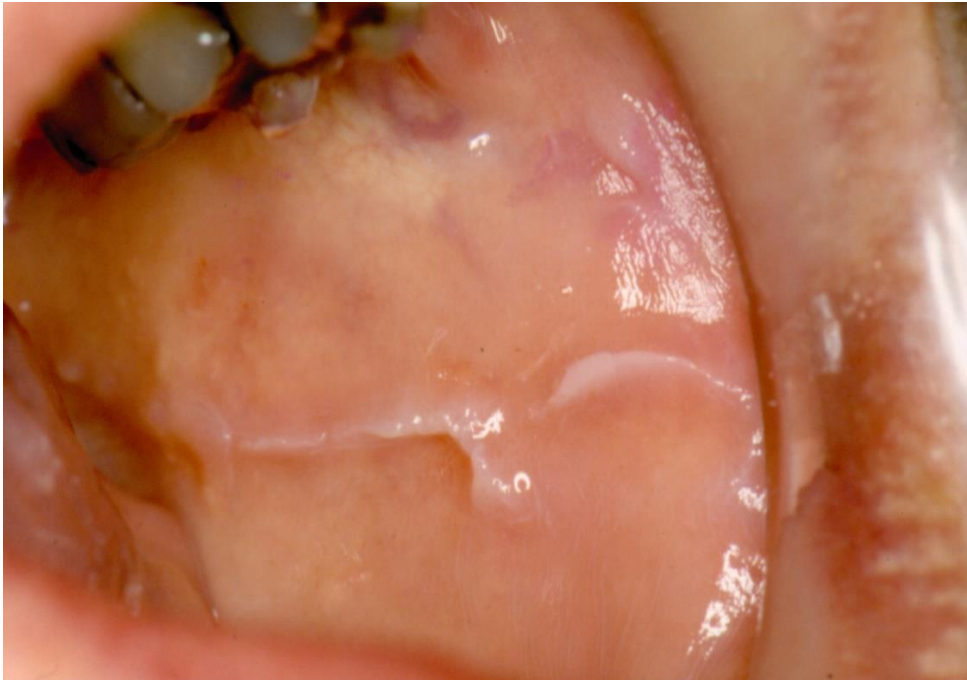<i>Definitive Diagnosis</i>	<i>Number (%)</i>
------------------------------------	--------------------------

Chronic Hyperplastic Candidosis	1 (2.4%)
Hyperkeratosis + Lichenoid Inflammation	25 (61.0%)
PVL	0 (0%)
Mild Dysplasia	10 (24.4%)
Moderate Dysplasia	2 (4.9%)
Severe Dysplasia	1 (2.4%)
Carcinoma-in-Situ	1 (2.4%)
SCC	1 (2.4%)

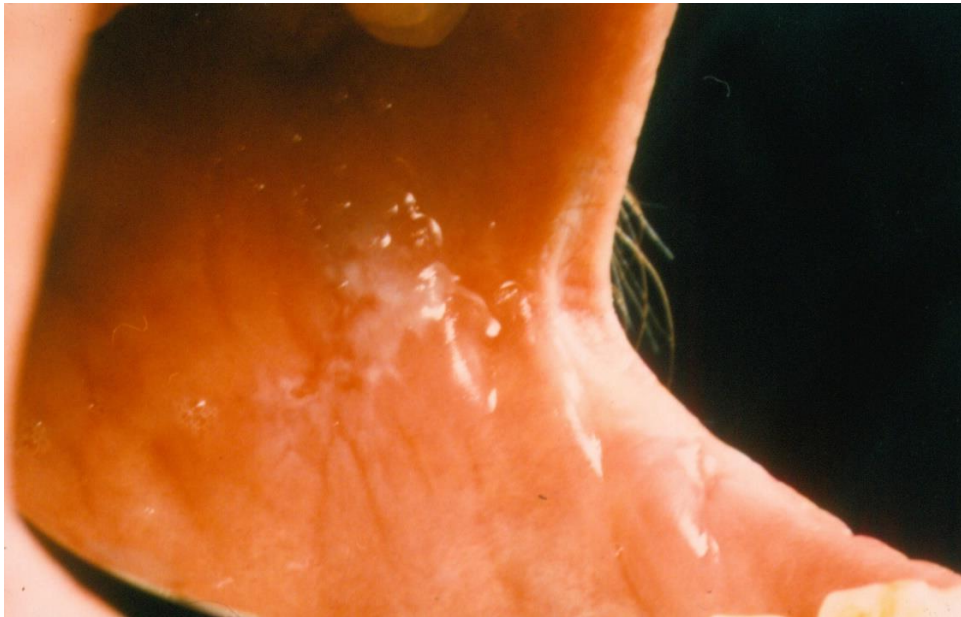
Table 7: Clinical Outcome Post-Laser Excision (Study Census Date 31.12.14)

Clinical Outcome	Hyperkeratosis	Hyperkeratosis + Lichenoid Inflammation
	Number (%)	Number (%)
Disease Free	14 (82.3%)	30 (73.2%)
Further Disease	1 (5.9%)	10 (24.4%)
Malignant Transformation	2 (11.8%)	1 (2.4%)

FIGURES



A



B

Figure 1: White mucosal lesions arising on the left buccal mucosa, showing (A) classic frictional hyperkeratosis secondary to repetitive occlusal irritation, and (B) leukoplakia which exhibited moderate dysplasia on incision biopsy.