



Article

Assessment of Left Ventricular Dyssynchrony after Permanent Cardiac Pacing by Using Two Dimensional Speckle Tracking Echocardiography

Teima, Sally Magdi, Bedier, Ahmed Ibrahim, Eladawy, Ahmed Hosny, Maaty, Abdul Razek Abdellatif, Singh, Jaipaul and Mahfouz, Essam Mohamed Elsayed

Available at <http://clock.uclan.ac.uk/35232/>

Teima, Sally Magdi, Bedier, Ahmed Ibrahim, Eladawy, Ahmed Hosny, Maaty, Abdul Razek Abdellatif, Singh, Jaipaul ORCID: 0000-0002-3200-3949 and Mahfouz, Essam Mohamed Elsayed (2020) Assessment of Left Ventricular Dyssynchrony after Permanent Cardiac Pacing by Using Two Dimensional Speckle Tracking Echocardiography. World Heart Journal, 12 (1). pp. 41-50. ISSN 1556-4002

It is advisable to refer to the publisher's version if you intend to cite from the work.

For more information about UCLan's research in this area go to <http://www.uclan.ac.uk/researchgroups/> and search for <name of research Group>.

For information about Research generally at UCLan please go to <http://www.uclan.ac.uk/research/>

All outputs in CLoK are protected by Intellectual Property Rights law, including Copyright law. Copyright, IPR and Moral Rights for the works on this site are retained by the individual authors and/or other copyright owners. Terms and conditions for use of this material are defined in the [policies](#) page.

Assessment of Left Ventricular Dyssynchrony after Permanent Cardiac Pacing by Using Two Dimensional Speckle Tracking Echocardiography

Sally Magdi Teima¹, MD,
Ahmed Ibrahim Bedier^{1,*}, MD,
Ahmed Hosny Eladawy¹, MD,
Abdul Razek Abdellatif Maaty¹, MD,
Jaipaul Singh², PhD, DSc,
and Essam Mohamed Elsayed
Mahfouz¹, MD

¹Mansoura University, Faculty of Medicine,
Cardiology Department, El-Gomhorya St,
El-Mansoura, Egypt

²Forensic and Applied Sciences, University
of Central Lancashire, Preston, UK

³Halberg Hospital and Research Institute,
Moradabad, India

Abstract

Background: Echocardiography is important in assessing left ventricular mechanical dyssynchrony (LVMD) and left ventricular (LV) function after implant of a permanent pacemaker. Global longitudinal strain (GLS) and Left ventricular dyssynchrony assessment enable clinicians to detect early signs of LV dysfunction after cardiac pacing. This study assessed LV mechanical asynchrony and LV function in different pacing modes after permanent cardiac pacing by using tissue Doppler imaging (TDI) and speckle tracking echocardiography (STE).

Patients and Methods: Seventy female (42) and male (28) patients were enrolled in this prospective observational case study (mean age 60.99 ± 13.77 years) at Mansoura Specialized Medical Hospital over a period of 1 year from April 2018 to April 2019. All the patients were assessed by thorough history taking, clinical examination, conventional Echocardiography, TDI and two-dimensional (2D) STE.

Results: Regarding parameters assessed by STE, there was a significant decrease in global longitudinal strain GLS ($P = 0.034^*$) while there was a significant increase in time to peak strain standard deviation (TP-SD) by STE ($P < 0.001^*$). Also, there was significant decrease in GLS ($P < 0.001^*$) and significant increase in TP-SD by STE ($P = 0.001^*$) in dual chamber pacemaker (DDD) group. Similarly, there was a significant decrease in GLS ($P < 0.001^*$) and a significant increase in TP-SD by STE ($P < 0.001^*$) in ventricular demanding pacing (VVI) group.

Conclusion: The results show that GLS by 2D STE can help in detection of subclinical left ventricular dysfunction (LVD) after permanent pacemaker implantation before appearance of clinical symptoms. In addition, cardiac pacing can still lead to LVMD irrespective of the degree of the pacing mode. However, this may need upgrading later on to cardiac resynchronization therapy (CRT).

Keywords: LVMD, GLS, speckle tracking echocardiography

* Corresponding Author: Dr Ahmed I Bedier, MD, Lecturer of Cardiology, Consultant of Interventional Cardiology. Mansoura University, Faculty of Medicine, Cardiology department. El-Gomhorya St, El-Mansoura, Egypt.
Email: dr.ahmedbedier@gmail.com

Introduction

The choice of an optimum pacing mode for the management of low heart rate is essential. In presence of disease in sino-atrial node dual chamber pacing is of choice [1]. The various pacing modes can lead to several problems due to some electrical changes leading to difference between timing in contraction of both ventricles in the heart which may cause cardiac failure and sudden cardiac death [2]. The artificial cardiac pacing via pacemaker alters the normal heart electrical activation when compared to the native activation resulting from atrioventricular (AV) nodal and His bundle system stimulation [3]. The pacing at the right ventricle causes abnormal contraction and decreased pump function. Right ventricular apical pacing can initiate asynchrony among LV interventricular septum (IVS) and free wall and also between right ventricle (RV) and LV [4]. It has also been showed that the existence of ventricular asynchrony is accompanied by a high risk of cardiac morbidity and death [5].

Echocardiography is essential in evaluating left ventricular asynchrony and function. Currently, real-time three dimensional echocardiography (RT3DE) and tissue Doppler imaging are of great sensitivity and frequently utilized procedures in order to quantify left ventricular mechanical asynchrony [6]. Speckle tracking echo-cardiography is recent modality depends on 2D grey scale imaging which helps in assessing left ventricular asynchrony. *Suffoletto et al.* [7] described the use of speckle tracking radial strain in quantifying asynchrony, which is the time difference in peak antero-septum to posterior wall strain more than or equal to 130 ms. Moreover, global longitudinal strain can help the cardiac clinicians to find out early signs of left ventricular dysfunction. Defining mechanisms of asynchrony will be useful for pacemaker programing choices in order to prevent further dysfunction of left ventricular [8]. The aim of this study was to evaluate left ventricular mechanical dyssynchrony and left ventricular function in various pacing modes after permanent cardiac pacing by using tissue Doppler imaging and speckle tracking echocardiography and to correlate these changes with other clinical, electrocardiographic and echocardiographic data.

Subjects and Methods

Ethics Statement

All procedures were performed as recommended by the guidelines as regard conventional and speckle tracking Echocardiography. The study was explained to all patients and they gave oral informed consent. Besides, the study was approved by the Ethics Committee of the Faculty of Medicine, Mansoura University. Informed consent was obtained from each individual participant involved in this study. This study was conducted in accordance with the 1964 Declaration of Helsinki and its subsequent amendments.

Study Population

Seventy (n = 70) patients were enrolled in this prospective observational case study, (mean age 60.99 ± 13.77 years, 28 males and 42 females), at Mansoura Specialized Medical Hospital over a period of 1 year from April 2018 to April 2019. Patients were enrolled into 2 groups. The first group had 30 patients with implanted single chamber pacemaker (Group A) while the second group had 40 patients with implanted Dual chamber pacemaker (Group B).

Methodology

All patients were assessed by thorough history taking including; age and gender, risk factors for coronary artery disease; hypertension, diabetes, dyslipidemia. Clinical examination included: blood pressure (BP), pulse, general examination and local cardiac examination. Investigations included: 12 lead surface electrocardiography (ECG), Echocardiography, TDI and 2D speckle tracking echocardiography.

Echocardiography

All of the patients had echocardiography using the General Electric Vivid E9 XD clear Dimensions ultrasound system (GE Healthcare, USA) using the

matrix M5Sc transducer. With more stress on the following pulsed wave Doppler (PWD), TDI, septal posterior wall motion delay (SPWMD) by M mode, aortic pre-ejection delay, inter-ventricular mechanical delay, tissue synchronization imaging (TSI) were done to assess septal to lateral delay, septal to posterior delay and SD-Ts. Similarly, 2D speckle tracking echocardiography was done to assess TP-SD and global longitudinal strain via the same machine.

Exclusion Criteria

Exclusion criteria include:

1. Cases with bad echocardiography window, cases with manifestations of obvious heart failure (HF), preceding heart operation, dilated cardiomyopathy, prosthetic valves and cases with preceding coronary artery disease (CAD) identified by proof of left ventricular wall motion aberrations at the echo or pathological Q waves in ECG, previous percutaneous coronary intervention (PCI) or coronary artery bypass grafting (CABG).
2. Previous implanted permanent pacemaker or implantable cardioverter defibrillator (ICD).
3. Frequent premature ventricular complexes (PVCs) in ECG
4. Patients with terminal co-morbidities such as end stage malignancy, end stage renal or liver diseases.

Statistical Analysis

The clinical and laboratory data were recorded on an "Investigation report form." These data were tabulated, coded then analyzed using the computer program SPSS (Statistical package for social science) version 25 to obtain the descriptive data.

In turn, the descriptive statistics data were calculated for the anthropometric measurements and laboratory data in the form of:

Mean \pm Standard deviation (SD).
Frequency (Number-percent)

Analytical Statistics

- In the statistical comparison between the different groups, the significance of difference was tested using the following test:
 - Student's t-test: Used to compare between mean of two groups of numerical (parametric) data. Inter-group comparison of categorical data was performed by using chi square test (X²-value).
 - Paired t-test was used for comparison within groups
 - Wilcoxon signed ranks test (Z) was used for comparison within group
 - A P value of < 0.05 was considered statistically significant and a P value of < 0.0001 was considered highly significant (HS) in all analyses.

Results

The study included 70 patients (mean age 60.99 \pm 13.77 years) who were divided into two groups. The first group A of patients (mean age 65.7 \pm 12.3 years) undergone pacing mode single chamber pacemaker VVI while the second group B of patients (57.45 \pm 13.89 years) had pacing mode dual chamber pacemaker. The mean demographic clinical characteristics and major risk factors of CAD of each group was assessed at 1 month and after 3 months of permanent pacemaker implantation (Table 1). The study recruited patients with the following risk factors of cardiovascular diseases (CVD). They included 11 patients (15.7%) who were smokers, 46 patients (65.7%) who were hypertensive, 9 patients (12.9%) who were dyslipidemic and 11 patients (15.7%) who were diabetic patients. Table 1 shows demographic clinical characteristics and major risk factors of CAD in the whole studied population while Table 2 demonstrates baseline criteria among the two studied groups.

Table 1. Baseline demographic, clinical characteristics and major risk factors of CAD among the 70 patients employed in the study

	All patients (n = 70)	
	No	%
Age		
<40y	6	8.6%
40-60y	28	40%
>60y	36	51.4%
Mean \pm SD	60.99 \pm 13.77	
Sex		
Male	28	40%
Female	42	60%
Hypertension	46	65.7%
Diabetes	11	15.7%
Smoking	11	15.7%
Dyslipidemia	9	12.9%
Beta blocker	10	14.3%
ACEI	38	54.3%
Diuretic	31	44.3%
Aspirin	13	18.6%
Warfarin	4	5.7%
Congested neck veins	18	25.7%
Edema L.L	29	41.4%
Dyspnea	18	25.7%

Abbreviations; ACEI: angiotensin converting enzyme inhibitor, L.L: lower limb.

SD: Standard Deviation.

Data are expressed in number abs as percentages.

Table 2. Baseline, clinical characteristics and major risk factors of CAD among the two studied groups (VVI versus DDD group) of patients

	Group B (n = 40)		Group A (n = 30)		χ^2	P
	No	%	No	%		
Hypertension	27	67.5%	19	63.3%	0.132	0.716
Diabetes	8	20%	3	10%	1.294	0.255
Smoking	10	25%	1	3.3%	6.076	0.014*
Dyslipidemia	6	15%	3	10%	0.383	0.536
Betablocker	8	20%	2	6.7%	2.489	0.115
ACEI	24	60%	14	46.7%	1.228	0.268
Diuretic	17	42.5%	14	46.7%	0.121	0.728
Aspirin	10	25%	3	10%	2.551	0.110
Warfarin	0	0%	4	13.3%	5.657	0.017*
Congested neck veins	10	25%	8	26.7%	0.025	0.875
Edema L.L	18	45%	11	36.7%	0.491	0.484
Dyspnea	12	30%	6	20%	0.897	0.343

Abbreviations; LL: lower limb, ACEI: angiotensin converting enzyme inhibitor, N: number, P: probability value, *: significant value > 0.05, X2: chi square, %: percentage.

Data are expressed as number and percentages with χ^2 and p values *P < 0.05.

Table 3. Comparative analysis of echocardiographic parameters after 1 and 3 months of permanent pacemaker implantation among the whole studied population of 70 patients.

	1 month (n = 70)	3 month (n = 70)	t	P
E DT	230.41 ± 79.65	228.31 ± 84.53	0.317	0.752
E/e' ratio	11.07 ± 4.4	9.24 ± 3.65	9.844	<0.001*
Tei index	0.69 ± 0.2	0.78 ± 0.22	5.113	<0.001*
LAD	3.97 ± 0.57	4.03 ± 0.56	3.308	0.001*
LVEDD	5.45 ± 0.61	5.67 ± 0.66	8.345	<0.001*
LVESD	3.75 ± 0.59	3.95 ± 0.66	7.415	<0.001*
EF	60.36 ± 8.39	56.3 ± 8.6	10.339	<0.001*
FS	32.53 ± 5.74	29.63 ± 5.74	8.887	<0.001*
APED	136.56 ± 27.97	151.11 ± 25.44	6.729	<0.001*
IVMD	30.04 ± 21.78	36.61 ± 21.58	4.416	<0.001*
SPWMD by M Mode	79.43 ± 36.6	93.71 ± 46.88	3.698	<0.001*
SD Ts by TSI	53.89 ± 19.14	59.8 ± 18.37	3.632	0.001*
Septal posterior delay by TSI	30.41 ± 74.11	25.7 ± 84.14	0.404	0.688
All segments Max delay by TSI	164.13 ± 54.2	174.99 ± 50.83	2.262	0.027*
Septal to lateral delay by TSI	23.63 ± 77.53	15.59 ± 88.07	0.634	0.528
GLS by STE	-15.96 ± 7.29	-14.25 ± 3.4	2.160	0.034*
TP SD by STE	35.04 ± 20.47	47.94 ± 23.92	5.522	<0.001*

Abbreviations; N: number, T: student t-test, P: probability value, *: significant value < 0.05, DT: deceleration time, LAD: left atrial dimension, LVEDD: left ventricular end diastolic dimension, LVESD: left ventricular end systolic dimension, EF: ejection fraction, FS: fractional shortening, APED: aortic pre-ejection delay, IVMD: inter-ventricular mechanical delay, SPWMD: septal posterior wall motion delay, TSI: tissue synchronization imaging, SD-Ts: standard deviation of time to peak systolic velocity, GLS: global longitudinal strain, STE: speckle tracking echocardiography, TP SD: standard deviation of time to peak strain.

Data are presents as mean ± SD with t and P values; *P < 0.001.

Table 4. Comparative analysis of different echocardiographic parameters after 1 and 3 months of pacemaker implantation in DDD group comprising of 40 patients

DDD	1 month (n = 40)	3 month (n = 40)	T	P
E DT	215.35 ± 69.74	225.28 ± 75.44	1.280	0.208
E/e' ratio	10.23 ± 3.85	8.58 ± 2.99	6.570	<0.001**
Tei index	0.73 ± 0.22	0.78 ± 0.21	3.668	0.001**
LAD	3.85 ± 0.52	3.92 ± 0.56	2.421	0.020*
LVEDD	5.47 ± 0.62	5.72 ± 0.66	6.520	<0.001**
LVESD	3.81 ± 0.63	4.01 ± 0.71	5.965	<0.001**
EF	58.93 ± 8.61	54.75 ± 8.84	7.318	<0.001**
FS	31.35 ± 5.74	28.7 ± 5.77	5.239	<0.001**
APED	133.63 ± 28.71	148.25 ± 27.01	5.689	<0.001**
IVMD	28.68 ± 22.72	36.35 ± 23.78	5.476	<0.001**
SPWMD by M Mode	73.75 ± 31.78	89.5 ± 44.43	3.348	0.002*
SD Ts by TSI	53.9 ± 19.16	59.4 ± 18.45	2.460	0.018*
Septal posterior delay by TSI	42.35 ± 70.63	28.35 ± 84.52	0.976	0.335
All segments Max delay by TSI	163.5 ± 53.47	172.1 ± 47.04	1.279	0.208
Septal to lateral delay by TSI	13.8 ± 74.53	3.48 ± 83.31	0.600	0.552
GLS by STE	-15.41 ± 3.88	-14.08 ± 3.93	6.058	<0.001*
TP SD by STE	37.7 ± 21.04	49.25 ± 25.75	3.719	0.001*

Abbreviations; N: number, T: student t-test, P: probability value, *: significant value > 0.05, DT: deceleration time, LAD: left atrial dimension, LVEDD: left ventricular end diastolic dimension, LVESD: left ventricular end systolic dimension, EF: ejection fraction, FS: fractional shortening, APED: aortic pre-ejection delay, IVMD: inter-ventricular mechanical delay, SPWMD: septal posterior wall motion delay, TSI: tissue synchronization imaging, SD-Ts: standard deviation of time to peak systolic velocity, GLS: global longitudinal strain, STE: speckle tracking echocardiography, TP SD: standard deviation of time to peak strain.

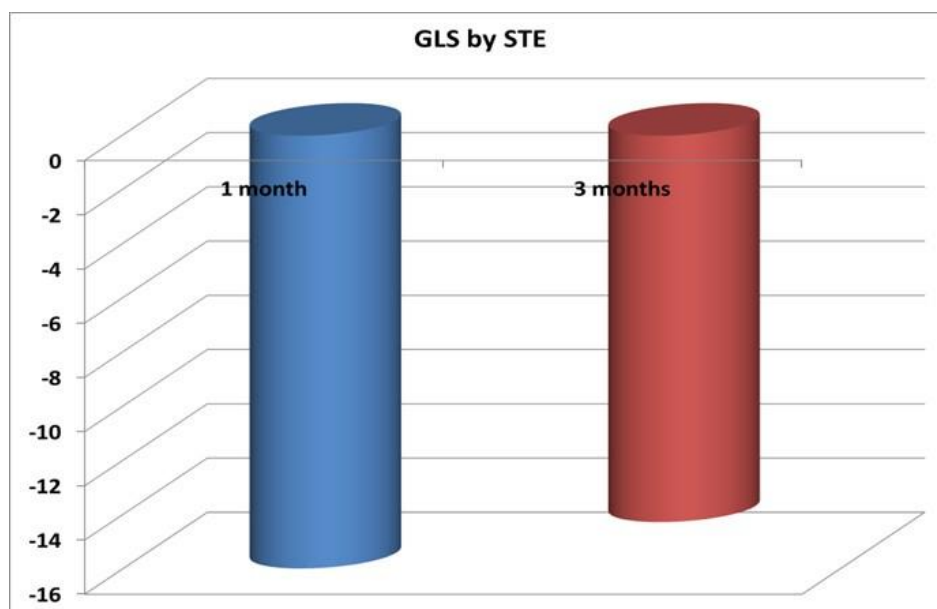
Data are expressed mean ± SD and with T and P values; *P < 0.05 and **P < 0.001.

Table 5. Comparative analysis of all echocardiographic parameters after 1 and 3 months of pacemaker implantation in group A of 30 patients

Group A	1 month (n = 30)	3 month (n = 30)	t	P
E DT	250.5 ± 88.45	232.37 ± 96.54	1.656	0.108
E/e' ratio	12.19 ± 4.88	10.12 ± 4.28	7.544	<0.001*
Tei index	0.65 ± 0.17	0.78 ± 0.24	3.830	0.001*
LAD	4.12 ± 0.59	4.17 ± 0.54	2.475	0.019*
LVEDD	5.41 ± 0.61	5.62 ± 0.66	5.162	<0.001*
LVEDS	3.67 ± 0.54	3.87 ± 0.6	4.434	<0.001*
EF	62.27 ± 7.82	58.37 ± 7.94	7.509	<0.001*
FS	34.1 ± 5.42	30.87 ± 5.56	9.119	<0.001*
APED	140.47 ± 26.95	154.93 ± 23.08	3.849	0.001*
IVMD	31.87 ± 20.7	36.97 ± 18.64	1.735	0.093
SPWMD by M Mode	87 ± 41.54	99.33 ± 50.17	1.883	0.070
SD Ts by TSI	53.88 ± 19.44	60.33 ± 18.56	2.701	0.011*
Septal posterior delay by TSI	14.5 ± 76.81	22.17 ± 84.93	0.394	0.697
All segments Max delay by TSI	164.97 ± 56.06	178.83 ± 56.09	2.037	0.051
Septal to lateral delay by TSI	36.73 ± 80.76	31.73 ± 92.99	0.263	0.794
GLS by STE	-17.11 ± 2.57	-14.15 ± 2.42	16.118	<0.001*
TP SD by STE	31.51 ± 19.47	46.18 ± 21.53	4.109	<0.001*

Abbreviations; N: number, T: student t-test, P: probability value, *: significant value < 0.05, DT: deceleration time, LAD: left atrial dimension, LVEDD: left ventricular end diastolic dimension, LVEDS: left ventricular end systolic dimension, EF: ejection fraction, FS: fractional shortening, APED: aortic pre-ejection delay, IVMD: inter-ventricular mechanical delay, SPWMD: septal posterior wall motion delay, TSI: tissue synchronization imaging, SD-Ts: standard deviation of time to peak systolic velocity, GLS: global longitudinal strain, STE: speckle tracking echocardiography, TP SD: standard deviation of time to peak strain.

Data are expressed mean ±SD and with T and P values; *P < 0.05 and **P < 0.00.



Data are expressed mean ±SD.

Figure 1. GLS by 2D STE among all studied cases after 1 and 3 months of pacemaker implantation.

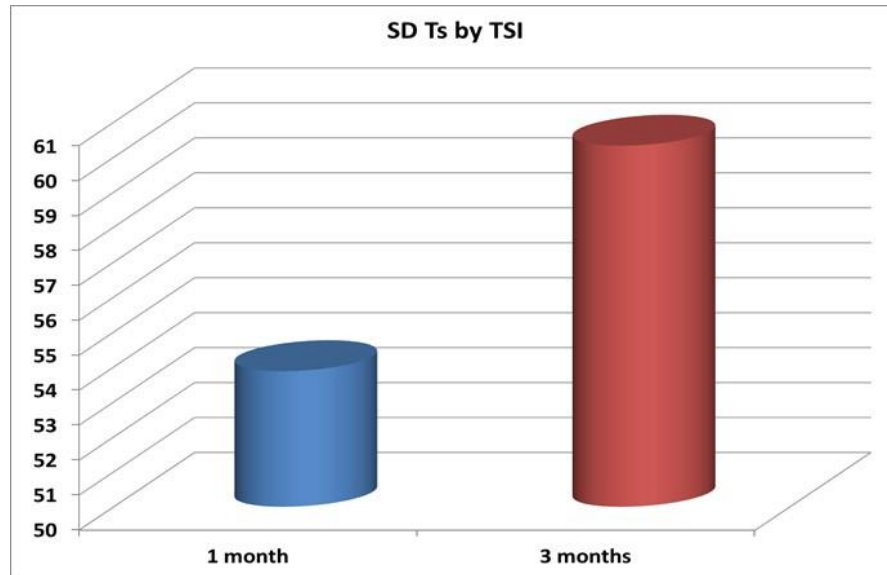


Figure 2. Standard deviation of time to peak systolic velocity by tissue synchronizing imaging after 1 and 3 months of dual chamber pacemaker implantation.

Comparative analysis of echocardiographic parameters after 1 and 3 months of PPM implantation among the 70 patients.

Regarding diastolic function by pulsed wave Doppler PWD, the results show no significant change in E wave deceleration time ($P = 0.752$) while there was a significant decrease in E/e' ratio ($P < 0.001^*$) and a significant increase in myocardial performance index Tei index ($P < 0.001^*$).

Regarding internal dimensions and systolic function, the data show that there was significant increase in the following: left atrial dimension (LAD) ($P = 0.001^*$), left ventricular end systolic dimension LVESD ($P < 0.001^*$) and left ventricular end diastolic dimension LVEDD ($P < 0.001^*$), while there was significant decrease in ejection fraction EF ($P < 0.001^*$) and fractional shortening FS ($P < 0.001^*$).

Regarding parameters of LV dyssynchrony, the results reveal that there was a significant increase in aortic pre-ejection delay APED ($P < 0.001^*$), interventricular mechanical delay ($P < 0.001^*$) and septal posterior wall motion delay SPWMD by M mode ($P < 0.001^*$).

Regarding parameters assessed by tissue synchronization imaging TSI, the findings show that there was significant increase in the following: SD-Ts ($P = 0.001^*$) and all segments max delay ($P = 0.027^*$), while there was no significant change in

the following: septal posterior delay ($P = 0.688$) and septal to lateral delay ($P = 0.528$).

Regarding parameters assessed by STE, the results reveal that there was significant decrease in global longitudinal strain GLS ($P = 0.034^*$), while there was a significant increase in TP-SD by STE ($P < 0.001^*$).

The data further show that in both group A and group B studied groups there was a significant increase in most of LV dyssynchrony parameters and a significant decrease in LV GLS by 2D STE after 1 and 3 months of pacemaker implantation.

Discussion

The major finding of our study is that in short-term follow up of left ventricular function after permanent cardiac pacing. The results of this study have revealed that there was subclinical LV dysfunction by 2D STE in most of cases, either single or dual chamber pacing which needs close observation of such patients and long-term follow up for fear of pacing induced cardiomyopathy and beginning of heart failure symptoms appearance. Cardiac pacing is the single efficient management for manifested sinus node disorders and it can enhance manifested chronotropic incompetence [9]. Furthermore, several research studies have revealed

enhancement in symptoms and function by cardiac pacing in cases with atrioventricular block [10].

Right ventricular (RV) pacing or left bundle branch block (LBBB) can lead to a left ventricular (LV) contraction shape which is dyssynchronous. Because of the out-of-phase contraction and relaxation of the LV septal and lateral walls, there is a loss of stroke work to internal power transmission from a contracting wall to the opposed wall that is in relaxation. Another result of the dyssynchronous LV contraction design is that the LV lateral wall contracts last resulting in overstretched and thus, accomplished a disproportionate fraction of the total stroke work [11].

The concept of 'pacing-induced' cardiomyopathy (CMP) has been applied to define the condition characterized by LV dilatation and hypokinesia which is frequently manifested with HF. In turn, this is accompanied with a high burden of RV pacing. However, pacing-induced CMP has not been especially involved in classification of cardiomyopathies [12].

Echocardiographic evaluation of LV dyssynchrony has been broadly utilized as it is noninvasive, extensively accessible and has no risk or complications. Currently, nearly all of the clinical evaluation modalities utilized tissue Doppler imaging (TDI) [13–14]. However, the most recent research study has employed the usage of speckle-tracking echocardiography (STE) and 3-dimensional (3D) echocardiography in tackling the clinical problems [15]. As such, this study evaluated LV mechanical dyssynchrony and LV function in different pacing modes after permanent cardiac pacing by using TDI and speckle tracking echocardiography. The study also showed that most of LV dyssynchrony parameters were affected (increased) after cardiac pacing whatever the pacing mode was either single or dual chamber pacing. In contrast, LV peak GLS was decreased after permanent pacemaker implantation after 1 and 3 months of implantation. The data also revealed that diastolic dysfunction seemed to be appeared among most of our patients.

The results of this study is in total agreement with those of Algazzar et al., [16] who found that mitral deceleration duration revealed marked changes among two modes of cardiac pacing in both group A and B, only at 6 month duration. Doppler designs to

investigate of mitral influx was able to reveal the pressure gradient among the left atrium and LV. The trans-mitral speeds were closely correlated with preload and inversely correlated with ventricular relaxation.

The results also reveal a significant ($P < 0.001^*$) increase in myocardial performance index Tei index which is in agreement with Algazzar et al., [16] who found elevation in myocardial performance index (MPI) in the both groups with marked changes among them up to 6 months. In the present study, there was a significant increase in left atrial dimension (LAD) ($P = 0.001^*$), left ventricular end systolic dimension (LVESD) ($P < 0.001^*$) and left ventricular end diastolic dimension (LVEDD) ($P < 0.001^*$) while there was a significant decrease in ejection fraction EF ($P < 0.001^*$) and fractional shortening FS ($P < 0.001^*$).

Lieberman et al., [17] studied a group of cases with conserved LV ejection fraction (LVEF) and they found that RV apical pacing caused a modest reduction in LVEF, while the LV the measurements were still unaffected. In the present study, there was a significant increase in aortic pre-ejection delay APED ($P < 0.001^*$), interventricular mechanical delay ($P < 0.001^*$) and septal posterior wall motion delay SPWMD by M mode ($P < 0.001^*$).

Alhous et al., [18] stated that in a study done on 25 cases, three showed SPWMD ≥ 130 ms at starting point. With right ventricular apical pacing to elevate SPWMD, the cases with intra-ventricular dyssynchrony utilizing such approach was elevated to six. Also, right ventricular pacing led to elevated IVMD compared to starting point, and in five cases IVMD was ≥ 40 ms. In the present study, there was a significant decrease in global longitudinal strain GLS ($P = 0.034^*$) while there was significant increase in TP-SD by STE ($P < 0.001^*$).

Moreover, our study revealed a significant increase in the following: SD-Ts ($P = 0.001^*$) and all segments with Max delay ($P = 0.027^*$). Our data are in complete agreement of those reported by Pastore et al., [19] who evaluated LV dyssynchrony by utilizing tissue Doppler echo at baseline and following at least one day of constant RV apical pacing. Employing total of 101 cases, their results showed marked LV dyssynchrony.

Dasgupta et al., [20] stated that myocardial deformation imaging may be a clinically useful tool for the prediction of a decline in LV systolic function following pacemaker implantation. Abnormalities in apical 4 chamber view (A4C) seem to appear before LVEF decline and as soon as 1-month post pacemaker implantation. On the contrary, El-Shabrawi et al., [21] found that chronic RV apical pacing in children after tetralogy of fallot repair was associated with better clinical status, preservation of RV systolic function, and prevention of progressive QRS prolongation.

In summary, it is of paramount importance to emphasize on the detection of subclinical left ventricular dysfunction after cardiac pacing which is so important on short and long term to recognize pacing- induced cardiomyopathy or ventricular dysfunction for possibility of upgrading conventional pacemaker to CRT to maintain LV function. Hence, the role of STE in measuring GLS became essential as it may detect LV dysfunction even with normal LVEF.

Conclusion

It is concluded that the new modalities in echocardiography as GLS and 2D STE can help in detection of subclinical left ventricular dysfunction after permanent pacemaker implantation before appearance of symptoms. Also, cardiac pacing can lead to LVMD whatever the pacing mode is which in turn may need later on upgrading to biventricular pacing.

Study Limitations

These include:

1. The small sample size was an important shortcoming of the current study. It should be noted that a limited number of patients met the inclusion criteria and were enrolled into the study. This small sample size could reduce the statistical power of our analyses. Short term follow up period.
2. Comparison of the different pacing modes only did not taking into consideration

different pacing sites (RV apical pacing; RV septal pacing either low, mid or high; His bundle pacing). Moreover, RT3DE and 3D STE needed for more evaluation. The need for correlation of study results regarding LV dyssynchrony with primary clinical end points as HF symptoms, the need for hospitalization and mortality.

Acknowledgment

The authors would like to thank Enago (www.enago.com) for the English language review.

Ethical Compliance

The authors have stated all possible conflicts of interest within this work. The authors have stated all sources of funding for this work. If this work involved human participants, informed consent was received from each individual. If this work involved human participants, it was conducted in accordance with the 1964 Declaration of Helsinki. If this work involved experiments with humans or animals, it was conducted in accordance with the related institutions' research ethics guidelines.

References

- [1] Sweeney MO, Hellkamp AS, Ellenbogen KA, Greenspon AJ, Freedman RA, Lee KL and Lamas GA : MDe Selection Trial [MOST] Investigators: Adverse effect of ventricular pacing on heart failure and atrial fibrillation among patients with normal baseline QRS duration in a clinical trial of pacemaker therapy for sinus node dysfunction. *Circulation* 107 [2003]: 2932–2937.
- [2] Tops LF, Suffoletto MS, Bleeker GB, Boersma E, van der Wall EE, Gorcsan J III, Schalij MJ & Bax JJ : Speckle-tracking radial strain reveals left ventricular dyssynchrony in patients with permanent right ventricular pacing. *J Am Coll Cardiol.*, 50, (12) 2007 :1180–1188.
- [3] Manolis AS: The deleterious consequences of right ventricular apical pacing: time to seek alternate site pacing. *Pacing Clin Electrophysiol*; 29 [2006] :298–315.

- [4] Tops LF, Schalij MJ, Holman ER, van Erven L, van der Wall EE, Bax JJ : Right ventricular pacing can induce ventricular dyssynchrony in patients with atrial fibrillation after atrioventricular node ablation. *J Am Coll Cardiol* ;48 [2006] :1642–1648.
- [5] Cho GY, Song JK, Park WJ : Mechanical dyssynchrony assessed by tissue Doppler imaging is a powerful predictor of mortality in congestive heart failure with normal QRS duration. *J Am Coll Cardiol*;46 [2005] :2237–2243.
- [6] Dai M, Lu J, Qian D, Cai J, Liu X, Wu X, Yang Z, Li X And Wang R: Assessment of left ventricular dyssynchrony and cardiac function in patients with different pacing modes using real-time three-dimensional echocardiography: Comparison with tissue Doppler imaging. *Experimental And Therapeutic Medicine* 6 [2013]: 1213-1219.
- [7] Suffoletto MS, Dohi K, Cannesson M, Saba S, Gorcsan J 3rd : Novel speckle-tracking radial strain from routine black-and-white echocardiographic images to quantify dyssynchrony and predict response to cardiac resynchronization therapy. *Circulation*;113 [2006] :960–968.
- [8] Baronaitė-Dūdonienė K, Vaškelytė J, Puodžiukynas A, Zabiela V, Kazakevičius T, Šakalytė G: Evaluation of left ventricular longitudinal function and synchrony after dual chamber pacemaker implantation. *medicina* 50 [2014] 340– 344.
- [9] Epstein AE, DiMarco JP, Ellenbogen KA, et al., ACC/AHA/HRS 2008 guidelines for device-based therapy of cardiac rhythm abnormalities: a report of the American College of Cardiology/American Heart Association Task Force on Practice Guidelines [Writing Committee to Revise the ACC/AHA/NASPE 2002 Guideline Update for Implantation of Cardiac Pacemakers and Antiarrhythmia Devices]. *J Am Coll Cardiol* [2008] ; 51:e1– 62.
- [10] Barold SS. Indications for permanent cardiac pacing in first-degree AV block: class I, II, or III? *Pacing Clin Electrophysiol* [1996] ; 19:747–751.
- [11] Kiehl EL, Makki T, Kumar R, et al., Incidence and predictors of right ventricular pacing-induced cardiomyopathy in patients with complete atrioventricular block and preserved left ventricular systolic function. *Heart Rhythm* [2016] ; 13:2272–2278.
- [12] McKenna WJ, Maron BJ, Thiene G. Classification, epidemiology, and global burden of cardiomyopathies. *Circ Res* [2017]; 121:722–730.
- [13] Cho GY, Kim HK, Kim YJ, et al., Electrical and mechanical dyssynchrony for prediction of cardiac events in patients with systolic heart failure. *Heart* [2010]; 96:1029-1032.
- [14] Wo HT, Chang PC, Chen TH, et al., Cardiac resynchronization therapy in patients with and without atrial fibrillation. *Acta Cardiol Sin* [2011] ;27:46-51.
- [15] Tanaka H, Nesser HJ, Buck T, et al., Dyssynchrony by speckle-tracking echocardiography and response to cardiac resynchronization therapy: results of the speckle tracking and resynchronization [STAR] study. *Eur Heart J* [2010] ; 31:1690-700.
- [16] Algazzar A S ,Moharram M A, Katta A A , Soltan G M, Abd ElAziz W F. Comparison of early effects of right ventricular apical pacing on left ventricular functions in single and dual chamber pacemakers. *The Egyptian Heart Journal* [2015] 67, 129–135.
- [17] Lieberman R, Padeletti L, Schreuder J, Jackson K, Michelucci A, Colella A, Eastman W, Valsecchi S, Hettrick DA. Ventricular pacing lead location alters systemic hemodynamics and left ventricular function in patients with and without reduced ejection fraction. *J Am Coll Cardiol*. [2006]; 48:1634 –1641.
- [18] Alhous M H, Small G R, Hannah A, Hillis G S, and Broadhurst P. Impact of temporary right ventricular pacing from different sites on echocardiographic indices of cardiac function. *Europace* [2011] 13, 1738–1746.
- [19] Pastore G, Noventa F, Piovesana P, et al., Left ventricular dyssynchrony resulting from right ventricular apical pacing: relevance of baseline assessment. *Pacing Clin Electrophysiol* [2008] ; 31:1456–1462.
- [20] Dasgupta S , Madani R , Figueroa J, Cox D, Ferguson E, Border W, Sachdeva R , Fischbach P, Whitehill R. Myocardial deformation as a predictor of right ventricular pacing-induced cardiomyopathy in the pediatric population. *J Cardiovasc Electrophysiol*. [2020]; 31(1): 337-344.
- [21] ElShabrawi M, Lotfy W, Hegazy R, Abdelaziz O, Sobhy R, Abdelmohsen G, Ibrahim H , Dohain AM. Evolution of ventricular function in children with permanent right ventricular pacing after tetralogy of Fallot repair: A midterm follow-up. *J Card Surg*. [2020] (10) ;1–9.