

Central Lancashire Online Knowledge (CLoK)

Title	B-cell lymphoma research in Malaysia - A narrative review
Type	Article
URL	https://clock.uclan.ac.uk/51441/
DOI	##doi##
Date	2024
Citation	Lim, Kean Ghee, Sumera, Afshan orcid iconORCID: 0000-0002-4108-2271, Venkateswaran, Sunil Pazhayanur, Burud, Ismail Abdul Sattar and Albazah, Nabeel Ibraheem Jaffar (2024) B-cell lymphoma research in Malaysia - A narrative review. Malaysian Journal of Pathology (MJPATH), 46 (1). ISSN 0126-8635
Creators	Lim, Kean Ghee, Sumera, Afshan, Venkateswaran, Sunil Pazhayanur, Burud, Ismail Abdul Sattar and Albazah, Nabeel Ibraheem Jaffar

It is advisable to refer to the publisher's version if you intend to cite from the work. ##doi##

For information about Research at UCLan please go to <http://www.uclan.ac.uk/research/>

All outputs in CLoK are protected by Intellectual Property Rights law, including Copyright law. Copyright, IPR and Moral Rights for the works on this site are retained by the individual authors and/or other copyright owners. Terms and conditions for use of this material are defined in the <http://clock.uclan.ac.uk/policies/>

REVIEW ARTICLE

B-cell lymphoma research in Malaysia – A narrative review

Kean Ghee LIM^{1*}, Afshan SUMERA³, Sunil Pazhayanur VENKATESWARAN², Ismail Abdul Sattar BURUD¹, Nabeel Ibraheem Jaffar ALBAZAH¹

¹Department of Surgery, School of Medicine, International Medical University, Bukit Jalil 57000, Kuala Lumpur, Malaysia; ²Department of Pathology, School of Medicine, International Medical University, Bukit Jalil 57000, Kuala Lumpur, Malaysia; ³Department of Pathology, School of Medicine, University of Central Lancashire, Fylde Rd, Preston PR1 2HE, United Kingdom.

Abstract

Lymphomas are a diverse group of malignant proliferations that arise as discrete tissue masses. The most widely accepted taxonomy for lymphoma is the World Health Organization classification of tumours of haematopoietic and lymphoid tissues, the 5th edition of which was released in June 2022. Most (85% to 90%) lymphoid neoplasms are of B cell origin. Mature B-cell neoplasms are a heterogeneous group of malignancies with similar disease courses and treatment paradigms. This review focuses on the various mature B-cell lymphomas in Malaysia, including Hodgkin lymphoma. A literature search was performed in various bibliographic databases. A total of 64 papers were included in this review. We found 15 papers on Hodgkin lymphoma, 14 on follicular lymphoma, 12 on Burkitt lymphoma, 5 on mucosa-associated lymphoid tissue (MALT) lymphoma, 4 on plasmablastic lymphoma, 3 on mantle cell lymphoma, 1 each on primary mediastinal large B-cell lymphoma, B-lymphoblastic lymphoma, and 3 on other unspecified B-cell lymphomas. The site, age, distribution, prognostic markers, and the various subclassification of B cell lymphomas were studied from these papers. Prognostic genetic markers in B-cell lymphomas include C-MYC, BCL2 and BCL6 as they are the most prevalent mutations in this condition. Anecdotal outcomes range from rapid fatality to unexplained spontaneous remission. This review adds to the existing literature on lymphoma in Malaysia by compiling the evidence that may lead to further research on the diagnosis and treatment of lymphoma in Malaysia and worldwide.

Keywords: B-cell Lymphoma, Burkitt, Hodgkin, Follicular lymphoma, MALT, Mantle cell, Malaysia.

INTRODUCTION

Lymphomas are a type of malignant growth that appear as distinct lumps of tissue. They are the fourth most common type of neoplasm in Malaysia, with a prevalence of 5.2% according to the Malaysia National Disease Registry Report 2012-2016.¹ The prevalence is higher in males (6.6%) compared to females (3.8%). However, information on lymphoma in Malaysia is scattered across various publications, and a review would be helpful for the scientific community to gain a larger understanding. The World Health Organization has established a thorough classification for lymphomas, with the fifth edition being released in June 2022.² Besides NK/T lymphomas and other Non-Hodgkin lymphomas, the classification categorises

B-cell lymphomas into (i) tumour-like lesions with B-cell dominance, (ii) precursor B-cell neoplasms, and (iii) mature B-cell neoplasms. Mature B cells are divided into pre-neoplastic and neoplastic small lymphoid proliferations, splenic B-cell lymphomas and leukaemias, lymphoplasmacytic lymphomas, marginal zone lymphomas, follicular lymphomas, cutaneous follicular centre lymphomas, and mantle cell lymphomas, transformation of indolent B-cell lymphomas, large B-cell lymphomas, Burkitt lymphoma, KSHV/HHV8-associated B-cell lymphoid proliferations and lymphomas, lymphoid proliferations and lymphomas associated with immunodeficiency and dysregulation, and Hodgkin lymphoma.² Worldwide, according to the WHO International

*Address for correspondence: Prof Lim Kean Ghee, Department of Surgery, School of Medicine, International Medical University, Bukit Jalil 57000, Kuala Lumpur, Malaysia. Tel: 06-7677798. Fax: 06-7677709. Email: keanghee_lim@imu.edu.my

Cancer Country Profile 2020, non-Hodgkin lymphoma (NHL) is the eighth most common cancer. This study focuses on mature B-cell lymphoma (excluding DLBCL) in Malaysia by gathering published data; it also intends to aid future research by gathering existing evidence and identifying gaps.

METHODOLOGY

A similar search approach was conducted, as published in the review on diffuse large B-cell lymphoma (DLBCL).³ The citations were manually entered or imported into the bibliographic software RefWorks and to Zotero for organisation.

The search terms used were Malaysia AND lymphoma, and information in this report is extracted from a more comprehensive library of published data that covered all lymphomas. The review of Diffuse large B-cell lymphoma (DLBCL) and NK/T lymphomas were published separately.^{3,4} The search was performed on 18 May 2021 and repeated on 3 July 2022.

The inclusion criteria were all published case reports and case series in Malaysia of lymphoma in general, B-cell and Hodgkin’s lymphomas, articles published in English between 1967 until 2022. Exclusion criteria for our review were, articles of cases which were reported from countries other than Malaysia, published in languages other than English and which included only lymphomas other than B cell and Hodgkin lymphoma.

We attempt synthesis where possible by presenting epidemiology and pathological features first followed by clinical features and then treatment results when available.

RESULTS AND DISCUSSION

The first search earmarked a total of 451 publications. An additional 65 publications were noted on 3 July 2022. A number unrelated to lymphoma or findings in Malaysia were excluded. Five authors (LKG, SPV, AFS, IAS & NIJ) carefully examined all 516 publications and deleted unrelated publications. A total of 64 publications were included in the study. (Fig. 1)

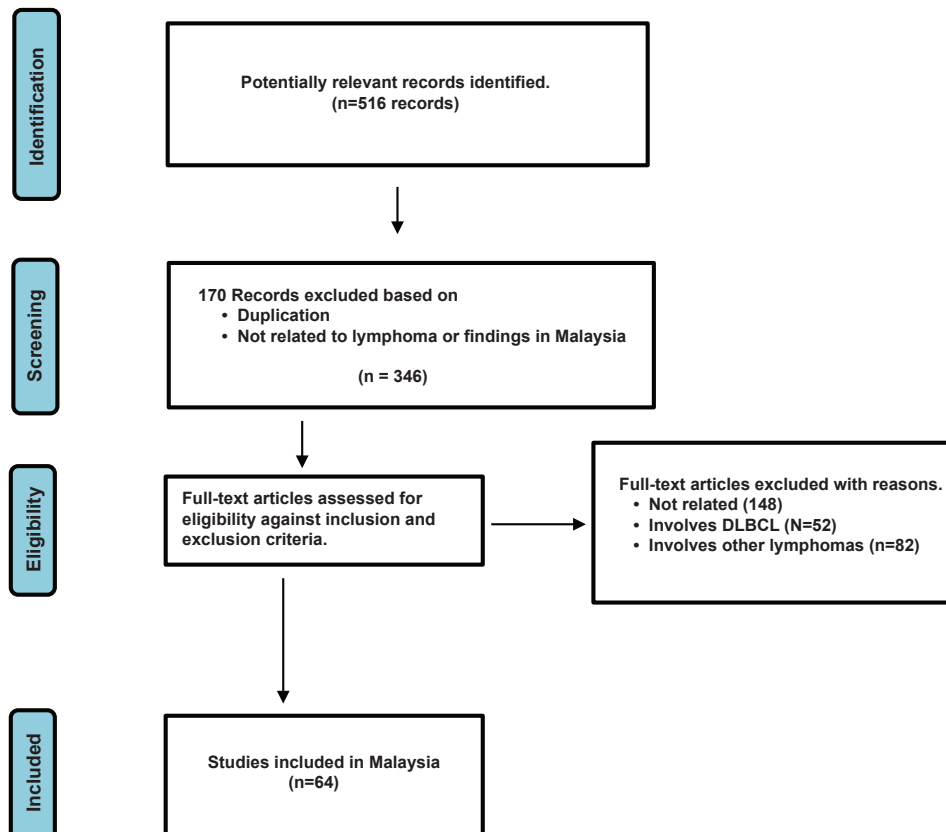


FIG. 1: PRISMA chart of workflow

B cell lymphomas account for between 71.3-83.3% of all lymphomas according to published case series from Malaysia. Within B-cell lymphomas, DLBCL is the commonest and accounts for 54-65% of all B cell lymphomas (Table 1). Hodgkin lymphoma is not included in this table as historically, they were counted separately when classified.

Prognostic genetic markers

Several genetic mutations characterise B-cell lymphoma and explain their behaviour and prognosis, the most common being *C-MYC*, *BCL2* and *BCL6*.

In normal cells, *C-MYC* acts as a transcriptional regulator involved in cell cycle progression and inhibition of terminal differentiation. *C-MYC* translocation of t (8;14) (q24; q32), deregulates its expression and overexpression leads the cell to resist cell death. It is observed in 7-15% of DLBCL cases and rare in Follicular Lymphoma (FL). Using FISH analysis, Salam *et. al* found *C-MYC* gene aberrations (gain/translocation or both) in 16.6% (12/72) of B-cell lymphomas, 9/50 (18%) of DLBCL, 2/13 (15.3%) of FL and present in the only case of Burkitt Lymphoma (BL).¹⁰

In the same study, it was reported that the gene is deregulated by the *BCL2* translocation of t (14;18) (q32; q21), which leads to the overexpression of the pro-survival *BCL2* protein, which suppresses apoptotic cell death. 80-90% of FL patients and 15%-20% of DLBCL cases exhibit it.¹⁰ In addition, Salem *et al.*¹⁰ has discovered *BCL2* abnormalities in 1 in 4 MALT, 40% (6/15) of FL, and 31.4% (16/51) of DLBCL.

BCL6 is necessary for B-cells to establish a germinal centre. Up to 35% of DLBCL cases had *BCL6* translocation t(3q27), which deregulates the gene and promotes malignant transformation in (GCB) germinal centre-derived B-cells. *BCL6* gene aberrations were not discovered in the other B-cell lymphomas (BL, MALT, and NOS), but they were found in 19/47 (40.4%) of DLBCL and 4/11 (36.4%) of FL.¹⁰

Tai *et al.* investigated the frequency of the 18q21 re-arrangement and trisomy 3 in 52 extranodal B-cell lymphomas and found that the 18q21 rearrangement in 23% and trisomy 3 in 26% of cases.¹¹ Of the 52 cases the 18q21 rearrangement was detected in 30% of grade-1 (low-grade lymphoma of MALT type) and grade 2 (diffuse large B-cell lymphoma with MALT component) lymphomas and 18% grade-3 (DLBCL without MALT component) tumours.

TABLE 1: Frequency of various B-cell lymphoma subtypes in Malaysia, excluding Hodgkin lymphoma

Author	Year	Number of cases	Location	DLBCL	FL	BL	MALT	NOS	Others
Chai <i>et al</i> ⁵	1981-1983	80	Sabah and Sarawak	52 (65%)	5 (6.3%)	15 (18.8%)	2 (2.5%)	5 (6.3%)	Mantle cell 1
Peh <i>et. al</i> ⁶	1993-1999	57 Chinese 4 (5%) Malay 47 (80%) Indian 6 (15%)	Klang	31 (54%)	11 (19%)	3 (5.3%)	6 (10.5%)	3 (5.3%)	Lymphoplasmacytic/Lymphocytic 3
Peh <i>et al</i> ⁷	1996-1998	58	Sarawak	38 (65.5%)	5 (8.6%)	5 (8.6%)	?	?	
Peh <i>et al</i> ⁸	1997-1999	68	Sabah	43 (65%)	7 (10.6%)	7 (10.6%)	6 (9.1%)	3	Lymphoblastic 1 Plasmacytoma 1
Salam ⁹	2010-2015	175 Males 98 Females 77	Pantai Premier Pathology	107 (61%)	21 (12%)	6 (3.4%)	16 (9.1%)	9 (5.1%)	Plasmablastic 4 Mantle cell 6 Lymphocytic 3 Lymphoblastic 3

FOLLICULAR LYMPHOMA

Follicular lymphoma (FL), a common B-cell origin NHL, arises from the follicular centre of lymph nodes, spleen, Waldeyer's ring, and bone marrow. FL rarely presents like leukaemia.¹² A study from West Malaysia reported a 10% frequency of FL in 158 cases of lymphoma.¹³ and 7.6% in 210 cases.⁹ In addition, a study from Sabah, East Malaysia, also found the same frequency of FL as 10.6% in 125 lymphoma cases.⁸

The hallmark of FL is the t(14;18) (q32;q21) which causes overexpression of the BCL2 protein, an apoptosis regulator.^{14,15} The t(14;18) translocation was detected 74% (46/62) of FL patients in Malaysia by Peh *et al.*¹⁶ It was present in all the ethnic Indian patients. The translocation is seen in up to 80% of FL.¹⁷ In an analysis of 26 cases of t(14;18) negative FL Masir *et al.*¹⁸ divided the cases into 3 groups (i) normal BCL2 genes and BCL2 protein negative, (ii) normal BCL2 genes but protein positive and (iii) presence of other genetic alterations (BCL2 amplification and trisomy 18) and BCL2 protein positive. Masir had 13/26 (50%) of group (i), 10 cases where BCL2 expression was heterogenous and 3 where it was strongly positive. 2 cases were group (iii).

The FLAGS (Follicular Lymphoma Grading System) has been developed with Malaysian input.¹⁹ The following cases illustrate how diverse FL can be.

Wong *et al.* reported a case of a 51-year-old man who presented with a progressive enlargement of lymph nodes of t(14;18)-negative FL with an unusual immunophenotype. FISH analysis was consistent with the absence of BCL2 gene rearrangement.²⁰

A 38-year-old man with FL reported by Masir *et al.* presented with a two-months history of systemic symptoms mild ascites, a palpable mass in the lower abdomen and enlarged inguinal lymph nodes. On imaging, mesenteric, paraaortic, pelvic wall lymphadenopathy and bilateral pleural effusions were also found. A diagnosis of the follicular type of B cell origin with signet-ring features was made based on immunohistochemistry.²¹

Goh HY reported FL in a case of a 33-year-old woman who complained of bilateral eye discomfort and redness for three months with pinkish nodular lesions on the upper bulbar conjunctivae. Topical steroids and oral anti-inflammatory medication had been ineffective.

An excisional biopsy revealed follicular B-cell NHL of grade I to II. She was kept on watchful observation. CT scan after 6 months showed no signs of disease and she remained well two years after the initial diagnosis.²²

FL has also been reported in a 47-year-old man with hypersplenism from massive splenomegaly. He had no lymph node enlargement and on presentation was diagnosed with malaria (falciparum titre 1:64) and treated with proguanil for one year. Splenectomy was then advised as he developed anaemia. The spleen weighed 3.6 kg and was found histologically to have follicular lymphoma. He was well one year after surgery.²³

Sallapan *et al.* reported a primary pancreatic FL lymphoma in a 75-year-old man in 2008 who presented with symptoms of obstructive jaundice with an ill-defined lobulated soft tissue lesion at the head of the pancreas on ultrasonography and computed tomography (CT). The diagnosis of a low-grade FL was made on histopathological and immunohistochemical analysis of the pancreatic lesion.²⁴

BURKITT LYMPHOMA

Burkitt lymphoma (BL) is named after Denis Burkitt, who described this aggressive childhood disease in Africa in the 1950s. It is associated with a translocation between the *C-MYC* gene and immunoglobulin heavy locus. The most common translocation variant is t(8;14) (q24;q32). The Epstein-Barr virus (EBV) is important in causing the disease in malnourished children and children with malaria. BL was the most common EBV-associated childhood lymphoma in a series of 103 cases in University Hospital Kuala Lumpur, and there was an increased risk of EBV association for BL in Chinese patients.²⁵

The first reported case of BL in Malaysia was a 3-year-old Chinese boy with an ulcerated tumour in the upper jaw in Johor in 1967. He was treated with cyclophosphamide and antibiotics but died of the disease after 3 weeks.²⁶ A Malay girl with long-term remission following treatment was reported in 1971.²⁷ Ramanathan and Ng also noted that BL was the commonest malignant oral tumour in children in Malaysia in 1979.²⁸ Most patients were between 3 to 8 years, with a peak age of 4 years. They had 20 cases beginning in 1967. Indians appeared to be spared. Chai *et al.* found 7 cases of Burkitt lymphoma among 13 cases of lymphoma among East Malaysian children in the University Hospital over 3 years from 1981.⁵

Although BL commonly presents in children with a lesion in the jaw it has also presented as abdominal distension, seen on ultrasound and CT imaging to be solid liver and peritoneal masses suspicious of tuberculosis in a 4-year-old Iban boy. He had Stage 3 disease and required supportive care followed by chemotherapy and survived.²⁹ BL presenting as intussusception was reported in an 11-year-old Malay boy who underwent an emergency right hemicolectomy. Following chemotherapy, he gained 5 kg within six months of completing chemotherapy.³⁰

In 1984, Ghani *et al.* described BL in the appendix. A 22-year-old Malay man who had appendectomy and removal of lymph nodes at surgery and was found to have no further disease on investigations. He received a course of chemotherapy but was only three months on follow-up when the case was reported.³¹ Burkitt lymphoma was diagnosed in a 20-year-old nulliparous woman who remained disease-free three years after treatment. She was treated with the Berlin-Frankfurt-Munster (BFM) regime, which included cyclophosphamide and prednisolone followed by alternating courses of dexamethasone/ ifosfamide/ methotrexate/ vincristine/ cytarabine/ etoposide and dexamethasone/ cyclophosphamide/ methotrexate/ vincristine/ doxorubicin with prophylactic intrathecal methotrexate.³² In the case of a 26-year-old man, it presented as peritoneal carcinomatosis.³³

Foo SH³⁴ described a case who presented with panhypopituitarism. Besides the pituitary, the 39-year-old Malay woman in Ampang Hospital was also found to have a tumour in the jaw, breast, and bone marrow. She had Stage IV disease and died of the disease.³⁴ A 9-year-old boy with a lesion in the mandible in 1982 went into remission after 4 months of cytotoxic therapy only to return one month later with a relapse and succumbed to the disease.³⁵

MUCOSA-ASSOCIATED LYMPHOID TISSUE (MALT) LYMPHOMA

MALT lymphomas are extranodal lymphomas of the marginal zone of mucosa-associated lymphoid tissue. They are often indolent and slow growing. The frequency of MALT lymphoma was reported as 1.9% in a study from Sarawak, Malaysia.⁵ A study in 2004 reported a high frequency of *p53* mutations in extranodal B-cell lymphoma with MALT component and suggested that it can be an aetiological agent in

the carcinogenesis of MALT lymphoma.³⁶ The t(11;18)(q21;q21) translocation and trisomy 3 are reported as the most common chromosomal aberrations in MALT lymphomas.¹¹

In a survey of 28 patients with orbital tumours that were biopsied at the Hospital Sultanah Bahiyah in Kedah, Tan *et al* found, 10 patients with MALT lymphomas, including 2 with bilateral disease. The other lesions were benign except for one other malignancy.³⁷

MALT lymphoma was reported in a 59-year-old lady with a 30-year history of autoimmune haemolytic anaemia. She complained of ear pain, and it was discovered that she had MALT lymphoma in the thyroid and external auditory canal tumour. According to immunohistochemistry, the malignant cells tested positive for LCA, CD20, and Bcl-2 and negative for CD3, CD15, CD30, cytokeratin, EMA, thyroid transcription factor 1 (TTF-1), and calcitonin. She responded to treatment (R-CHOP), but she was lost to follow-up after a year.³⁸

MANTLE CELL LYMPHOMA

Mantle cell lymphoma (MCL) is a distinct B-cell type of lymphoma derived from a subset of naïve pre-germinal centre cells or the mantle zone of secondary follicles. It is relatively uncommon, accounting for 2 to 5% of malignant lymphomas.

A 53-year-old woman in Kuala Lumpur with hoarseness of voice, dysphagia and loss of weight, an enlarged left tonsil but no cervical lymphadenopathy was diagnosed with MCL following a left tonsillectomy. Clinical staging was considered Stage IIB and she was treated with chemotherapy. At four months, a PET-CT scan showed no residual tumour.³⁹ A 61-year-old man who presented with severe dysphagia and globus sensation for two months with a tumour in the vallecula in the oropharynx in HUSM, Kelantan. The patient underwent endoscopic transoral tumour debulking. Histopathology confirmed MCL.⁴⁰ MCL was also reported to have caused intussusception from the hepatic flexure in the colon of a 66-year-old man. After surgery, he received two cycles of chemotherapy but was found to have the lymphoma also in the nasopharynx. He received palliative care only following that.⁴¹

PLASMABLASTIC LYMPHOMA (PBL)

PBL is an uncommon and aggressive large B-cell neoplasm which is predominantly reported in

HIV-positive male patients with the Epstein-Barr virus.

It was, however, diagnosed in a 56-year-old HIV-negative woman who presented with profuse right epistaxis. Immunohistochemical study showed that the malignant cells were immunoreactive towards CD79a, CD138, and MUM-1, and negative for CD3 and CD20. The Ki-67 proliferative index was 70%, and the cells were also positive for EBV encoding region (EBER) in situ hybridisation.⁴² Johan *et al.* reported PBL in a 74-year-old man who presented with abdominal discomfort, altered bowel habits, loss of weight, and loss of appetite with a palpable abdominal mass. Upper endoscopy revealed multiple dish-like and raised nodular mass with a central ulcer in the stomach and duodenum. The histology was consistent with high-grade lymphoma of the plasmablastic type. The immunohistochemistry was positive for CD38 and CD138, but negative for CD45, as well as CD3 and CD20. Unfortunately, the patient succumbed due to sepsis without the completion of his investigations and treatment.⁴³ Wong *et al.*⁴⁴ reported two cases in 2021, both men with lesions of the jaw; one aged 51 years and HIV negative and another 47 years and HIV positive. CD3 was positive in both patients, but a range of many other markers were negative.

A very fortunate 61-year-old man who presented with a smooth surface mass covering the entire left nasal cavity that bled on contact, with PBL was reported by Lee *et al.*⁴⁵ The patient also had large mass at the left paravertebral region with extension into the left T7/8 neural foramina discovered at CT scan. He was HIV-negative. Immunohistochemistry showed the neoplastic cells were diffusely positive for CD79a, MUM-1, and CD56 and focally positive for PAX-5, but negative for CD20, CD30, ALK-1, CD3, CD5, CD10, Bcl-2, Bcl-6, CD138, HMB45, and S-100. Ki-67 was almost 100%. Surprisingly, Lee *et al.* reported resolution of his symptoms after the first biopsy of the paravertebral mass, and hence, treatment for PBL was not initiated. Spontaneous regression of his PBL was further confirmed by a repeat rigid nasal endoscopy, which showed good patency of both nasal cavities, and a repeat CT scan of the paranasal sinuses, which revealed spontaneous regression of his left nasal mass. He remained well 4 years afterwards.

PRIMARY MEDIASTINAL LARGE B-CELL LYMPHOMA (PMLBL)

Primary mediastinal large B-cell lymphoma (PMLBL) is an uncommon lymphoma and is known to originate from B-cells of the thymus. It mimics thymic neoplasms and other lymphomas clinically and histopathologically.

Win *et al.* reported a 33-year-old obese man who presented with shortness of breath on and off for 4 years. Radiology revealed a huge anterior mediastinal mass. Histopathological examination of the excised specimen confirmed PMLBL with stromal fibrosis and sclerosis which created a diagnostic difficulty. Immunohistochemically, the tumour cells expressed diffuse positivity for LCA, CD20, CD79a, CD23, BCL2, MUM-1 and heterogenous positivity for CD30 and EMA, and were negative for CD10, CD15 and ALK. Ki67 score was very high. The patient showed partial response to 6 cycles of RICE chemotherapy and was planned for second-line chemotherapy using a hyper-CVAD regimen followed by autologous stem cell transplantation.⁴⁶

HODGKIN LYMPHOMA

Epidemiology and pathogenesis

Hodgkin lymphoma (HL) is an aggressive, germinal centre B cell lymphoma that is clinicopathologically distinctive, with comparatively high cure rates among haematological malignancies. Thomas Hodgkin described several cases in London in 1832 asserting this was a different disease from tuberculosis. Samuel Wilks coined the name about 33 years later publishing similar cases. It was recognised by the characteristic Reed-Sternberg cell in 1901. As it was a distinct entity, all other lymphomas were called Non-Hodgkin in data collection for many years and are still counted separately in some reports. The Malaysian National Cancer Registry Report (2012-2016), for example, found an ASR of 1.2, 0.9 and 0.7 per 100,000 of HL for Indian, Malay and Chinese men in Malaysia, respectively. The ASR for women were 0.7, 0.6 and 0.4 per 100,000 for Indians, Malays and Chinese respectively.¹

HL's exact cause is still unknown. However, the risk of developing EBV-positive HL is observed higher in patients with a recent episode of infectious mononucleosis. Hjalgrim H *et al.*⁴⁷ and Peh *et al.*⁶ noted a high prevalence of EBER (50%) in adults with classical Hodgkin's lymphoma (cHL) but the rate was lower among East Malaysians (33.3%).⁵ A study from Kuala

Lumpur reported high expression of CD30, CD40 and CD95 in the Reed Sternberg (RS) cells of most cases of cHL. The authors⁴⁸ suggested that the expression patterns, independent of EBV and did not correlate with apoptosis of the RS cells. The characteristic Thymus and Activation-Regulated Chemokine (TARC) positive staining in the RS cells of classical Hodgkin's lymphomas suggest that TARC can be a useful antibody in aid of diagnosis in difficult cases of cHL.⁴⁹

Classification

Globally, HL is divided into cHL, which accounts for 95% of cases, and nodular lymphocyte-predominant HL (NLPHL), which accounts for 5% of cases.⁵⁰ Salam *et al.*⁹ however, noted that in Malaysia, cHL accounted for 88% of cases and NLPHL for 12%.

cHL is subclassified into four subtypes: nodular sclerosis, lymphocyte-rich, lymphocyte-depleted, and mixed-cellularity. In Klang, Peh *et al.*⁶ noted that of the total 14 HL cases, 1 was lymphocyte-rich, 2 were lymphocyte-depleted, and 6 were lymphocyte-predominant. However, in Johor Bahru, out of 94 HL cases, the most prevalent HL histological subtype found in was nodular sclerosis (77.6%), followed by mixed cellularity (6.4%)⁵¹.

Clinical features

Malaysia's National Cancer Registry Report for 2012-2016 notes a bimodal age distribution of HL cases in Malaysia with a peak among 20–29-year-olds and another in the elderly. Boo *et al.* noted a median age of 27 years among 94 HL patients seen in Johor. The majority of the patients were male (58, 61.7%) and 73.4% were ethnic Malay, followed by Chinese (14.9%), and Indian (10.6%).⁵² Fifty-two percent of these HL patients presented in stage II, while the rest presented with more advanced stages.⁵² Among 49 cases from 1980-1984 in University Hospital, Bosco *et al.*⁵³ noted 25 were Chinese, 13 Malays and 10 Indians. In Sarawak, Peh *et al.* noted the mean age of HL patients was 34.7 years with 7 males out of 9.⁵⁴ Salam *et al.* found 68% (17/25) of HL cases were in patients below 30 years, with 11 males to 14 females, a ratio of 1:1.27. There were 11 Chinese, 9 Malays, 3 Indians and 3 of other ethnic groups.⁹

Extranodal Hodgkin's disease

Zainal Abidin *et al.* described the case of a 35-year-old man with HL and involvement of the right shoulder musculature presenting

like a sarcoma.⁵⁵ Ding and Kamarudin⁵⁶ described a 35-year-old woman who had a large supraclavicular mass which was a concomitant infection of *Cryptococcus laurentii* and HL. HL has also presented as a mediastinal mass in a 29-year-old man, who responded well to treatment.⁵⁷

Khoo *et al.*⁵⁸ reported a 53-year-old man in Sabah with splenomegaly complaining of fever for two weeks, anorexia and a 10 kg weight loss. The diagnosis was established with a trephine bone biopsy. Immunohistochemistry showed CD30+ with heterogenous PAX5- to dim PAX5+ confirming cHL with bone marrow infiltration. He responded clinically to chemotherapy, and an interval CT scan showed almost complete resolution of splenic lesions after three cycles of chemotherapy and proceeded to complete six cycles of chemotherapy.

Management

The primary practical justification for separating HL from other cancers in discussion is that, as of long ago, it has been noted that the ideal chemotherapy regimen and its favourable prognosis are special. Boo *et al.*⁵² reported a series with a median follow-up period of 28 (IQR=32) months in their cohort of 94 patients with cHL in Johor from 2013 to 2017. All patients received chemotherapy, but only 13.8% received radiation as consolidation. ABVD (doxorubicin, bleomycin, vinblastine, and dacarbazine) was the most commonly used regime. 85.1% of patients received it as first-line therapy, whereas 14.9% began the escalated BEACOPP regimen (bleomycin, etoposide, doxorubicin, cyclophosphamide, vincristine, procarbazine, and prednisone). The complete response (CR) was higher (76.9%) with increased BEACOPP compared with ABVD (62.8%). The 2-year overall survival (OS) and progression-free survival (PFS) of the entire cohort were 96.5% and 71.1%, respectively. The 2-year OS and PFS for advanced-stage disease were 93.9% and 62.8%, compared to 100% and 82.7% for early-stage disease, respectively ($P=0.252$ and $P=0.052$, respectively).

OTHER NON-SPECIFIED AND RARE PRESENTATIONS OF B CELL LYMPHOMAS

Ting *et al.*⁵⁹ reported seven cases of orbital solitary fibrous tumour presenting with proptosis in Serdang. All were CD34 positive. Four were

positive for BCL-2 indicating, B-cell lymphoma (BCL-2) but not further typed.

Lim *et al.*⁶⁰ reported a 72-year-old patient who presented with an ulcerated palatal mass, weight loss and adrenal insufficiency. Repeated biopsies from the mass revealed actinomycosis with no features of malignancy, while CT scanning revealed a left maxillary sinus mass with invasive features and bilateral large adrenal masses. The patient was treated with intravenous penicillin and intravenous hydrocortisone. However, his condition did not improve, and new signs appeared, that of left facial swelling and lymphadenopathy. A repeat biopsy of the palatal and adrenal masses revealed B-cell lymphoma.

Ramachandran *et al.* reported a case of ovarian lymphoma in a 62-year-old Chinese woman coincidentally found with a cystic, mixed epithelial carcinoma of the same ovary. Histopathological examination revealed a high grade, B-cell lymphoma with a mixed epithelial carcinoma, clear cell and serous carcinoma side by side. She also had a leiomyoma and adenomyosis of the uterus. The patient was doing well after 5 courses of a combination chemotherapy for lymphoma and carcinoma.⁶¹

Zakaria *et al.*⁶² described a case of a 45-year-old lady with no prior medical history who presented with spinal disease at the T5 level. A T4–T7 level intraspinal extradural mass with T4–T7 vertebral bodies involved was discovered by magnetic resonance imaging of the whole spine. She received tuberculosis treatment for a month with no improvement. Surgery revealed B-cell lymphoma positive for CD20, CD79a, and CD10 with a Ki67 proliferation rate of roughly 60%. Further imaging revealed Stage IV disease. She refused further treatment and succumbed to the disease.

A child was diagnosed at two years with high grade B-cell NHL having been noted to have hepatosplenomegaly at 11 months and a previous history of fever and diarrhoea at 7 months with anaemia and thrombocytopenia. Prechemotherapy screening revealed HIV infection even though HIV exposure was initially not forthcoming from the parents. The child completed cancer chemotherapy, encountering opportunistic infections, but succumbed 6 months after diagnosis.⁶³

B cell NHL has also been reported in a 60-year-old man with headache and other neurological symptoms. The tumour in the parietal bone was excised and he was given radiotherapy and chemotherapy. CT scan after 8 months showed no recurrence.⁶⁴

This section is a reminder that even as characterisation of lymphomas progress, some cases may remain unclassified.

Limitations of the study

This study does not represent the prevalence of lymphoma in Malaysia as it captures only what is published and many of these are case reports and series which are anecdotal and selective. We acknowledge that our literature search may miss out information despite our search efforts. It is hoped that this study is an indication of the gaps in literature that can guide investigators in moving forward.

CONCLUSION

This review illuminates the diverse landscape of lymphomas in Malaysia, emphasising the prevalence, genetic markers, and clinical manifestations of B-cell lymphomas. As the literature is not yet that abundant, this report retains much of the unique details of the cases report rather than lose that in the synthesis to note just patterns and percentages.

Despite advancements in managing lymphomas, particularly encompassing B-cell Lymphomas and Hodgkin's lymphoma, challenges remain in classification modifications, patient care, and treatment adherence. Notably, recent Malaysian research delving into rare lymphoma subtypes contributes valuable insights. The ongoing exploration in this domain holds the promise of advancing global lymphoma diagnosis and treatment. Persistent efforts in research and clinical endeavours are vital to addressing existing issues and refining strategies for the betterment of lymphoma patients worldwide.

Acknowledgements: We wish to thank Prof Dr Cheong-Lieng Teng for his help with the bibliographic search.

Authors' contribution: All authors contributed equally.

Conflict of interest: The authors declared no conflict of interest.

REFERENCES

1. Malaysia National Cancer Registry Report (MNCR)2012-1016, June 2019. Commentary on 10 selected cancer sites. <https://www.moh.gov.my/moh/resources/Penerbitan/Laporan/Uмум/2012->

- 2016%20(MNCRR)/MNCR_2012-2016_FINAL_(PUBLISHED_2019).pdf
2. Alaggio R, Amador C, Anagnostopoulos I, *et al.* The 5th edition of the World Health Organization Classification of Haematolymphoid Tumours: Lymphoid Neoplasms. *Leukemia*. 2022;36(7):1720-48.
 3. Lim KG, Sumera A, Burud IAS, Venkateswaran SP. Diffuse large B-cell lymphoma research in Malaysia: A review. *Malays J Pathol*. 2023;45(1):1-10.
 4. Lim KG, Venkateswaran SP, Sumera A, Burud IAS, Krishnappa P, Jaafar NI. Non-Hodgkin lymphoma research (excluding all B cell lymphoma) in Malaysia: a review. *IeJSME* 2023 17(2):34-52.
 5. Chai SP, Peh SC, Kim LH, Lim MY, Gudum HR. The pattern of lymphoma in east Malaysian patients as experienced in the University Hospital, Kuala Lumpur. *Malays J Pathol*. 1999;21(1):45-50.
 6. Peh SC, Kim LH, Thanalechimy N, Chai SP, Poppema S. Spectrum of malignant lymphomas in Klang Hospital, a public hospital in Malaysia. *Malays J Pathol*. 2000;22(1):13-20.
 7. Peh SC, Gudum HR, Tai YC, Wong FL, Dolkadir J. Spectrum of malignant lymphoma in Sarawak General Hospital. *J Clin Exp Hematop*. 2001;41(1):45-9.
 8. Peh SC, Shaminie J, Jayasurya P, Hiew J. Spectrum of malignant lymphoma in Queen Elizabeth Hospital, Sabah. *Med J Malaysia*. 2003;58(4):546-55.
 9. Salam DSDA, Teoh SH, Peh SC, Cheah SC. Retrospective Lymphoma Study from Malaysia Private Hospital. *Int J Cancer Clin Res*. 2020;27:7(4).
 10. Salam DSDA, Thit EE, Teoh SH, Tan SY, Peh SC, Cheah SC. C-MYC, BCL2 and BCL6 Translocation in B-cell Non-Hodgkin Lymphoma Cases. *J Cancer*. 2020;11(1):190-8.
 11. Tai YC, Tan JA, Peh SC. 18q21 Rearrangement and trisomy 3 in extranodal B-cell lymphomas: a study using a fluorescent in situ hybridisation technique. *Virchows Arch*. 2004;445(5):506-14.
 12. Chen SW, Chang ST, Hsieh YC, *et al.* Frequent loss of CD10 expression in follicular lymphoma with leukaemic presentation. *Malays J Pathol*. 2020;42(2):237-43.
 13. Peh SC. Host ethnicity influences non-Hodgkin's lymphoma subtype frequency and Epstein-Barr virus association rate: the experience of a multi-ethnic patient population in Malaysia. *Histopathology*. 2001;38(5):458-65.
 14. Montoto S, López-Guillermo A, Colomer D, *et al.* Incidence and clinical significance of bcl-2/IgH rearrangements in follicular lymphoma. *Leuk Lymphoma*. 2003;44(1):71-6.
 15. Masir N, Campbell LJ, Goff LK, *et al.* BCL2 protein expression in follicular lymphomas with t(14;18) chromosomal translocations. *Br J Haematol*. 2009;144(5):716-25.
 16. Peh SC, Shaminie J, Tai YC, Tan J, Gan SS. The pattern and frequency of t(14;18) translocation and immunophenotype in Asian follicular lymphoma. *Histopathology*. 2004;45(5):501-10.
 17. Shia AK, Gan GG, Jairaman S, Peh SC. High frequency of germinal centre derivation in diffuse large B cell lymphoma from Asian patients. *J Clin Pathol*. 2005;58(9):962-7.
 18. Masir N, Jones M, Abdul-Rahman F, Florence CS, Mason DY. Variation in BCL2 protein expression in follicular lymphomas without t(14;18) chromosomal translocations. *Pathology*. 2012;44(3):228-33.
 19. Fauzi MF, Pennell M, Sahiner B, *et al.* Classification of follicular lymphoma: the effect of computer aid on pathologists grading. *BMC Med Inform Decis Mak*. 2015;15:115.
 20. Wong YP, Faridah AR, Ahmad TS, Noraidah M. A case of t(14;18)-negative follicular lymphoma with unusual immunophenotype: A diagnosis dilemma. *Med & Health*. 2011;6(1supp):207.
 21. Masir N, Cheong SK, Noordin K. Signet-ring Cell Lymphoma-a Case Report. *Hematology*. 2001;6(3):187-92.
 22. Goh HY, Che Daud CMB, Santhirathelagan C, Retnasabapathy S. Primary Low Grade Follicular Lymphoma of the Conjunctivae Mimicking Nodular Anterior Scleritis: A Case Report. *Clin Med Res*. 2022;20(2):111-3.
 23. Ng SC, Kuperan P, Jayalakshmi P, Chua CT. Splenic lymphoma with hypersplenism--a case report. *Singapore Med J*. 1990;31(1):80-2.
 24. Sallapan S, Abu Bakar NZ, Jarmin R, Masir N, Mohammed F. Primary follicular lymphoma of the pancreas: A rare tumour mimicking pancreatic carcinoma. *Malays J Pathol*. 2018;40(3):359-71.
 25. Peh SC, Nadarajah VS, Tai YC, Kim LH, Abdullah WA. Pattern of Epstein-Barr virus association in childhood non-Hodgkin's lymphoma: experience of university of malaya medical center. *Pathol Int*. 2004;54(3):151-7.
 26. Krishnappa A, Burke T. A case of Burkitt's lymphoma in Johor, West Malaysia. *Int J Cancer*. 1967;2(6):604-5.
 27. Ramanathan K, Singh B. Burkitt's lymphoma--long-term remission in a Malay girl. *Dent J Malaysia Singapore*. 1971;11(2):7-11.
 28. Ramanathan K. Burkitt's lymphoma in West Malaysia. *Southeast Asian J Trop Med Public Health*. 1972;3(2):249-54.
 29. Nor Fauziah MH, Faizah MZ, Loh CK. Diagnostic challenge of Burkitt's lymphoma at early age. *Med J Malaysia*. 2017;72(5):324-6.
 30. Retinasekharan S, Sinnathamby P, Mohamad I. Paediatric burkitt lymphoma presenting as a mandible swelling and intussusception. *Med J Malaysia*. 2019;74(1):90-1.
 31. Ghani SA, Syed N, Tan PE. A rare cause of acute appendicitis: Burkitt's lymphoma of the appendix. *Med J Malaysia*. 1984;39(4):311-3.
 32. Ng SP, Leong CF, Nurismah MI, Shahila T, Jamil MA. Primary Burkitt lymphoma of the ovary. *Med J Malaysia*. 2006;61(3):363-5.
 33. Sharifah MI, Zamzami NA, Rafeah TN. Diffuse peritoneal lymphomatosis simulating peritoneal carcinomatosis. *Med J Malaysia*. 2011;66(3):270-2.
 34. Foo SH, Sobah SA. Burkitt's lymphoma presenting with hypopituitarism: a case report and review of literature. *Endocrinol Diabetes Metab Case Rep*. 2014;2014:140029.

35. Boon LC, Nik-Hussien NN. Burkitt's lymphoma in the mandible--a case report. *Br J Oral Maxillofac Surg.* 1987;25(5):410-4.
36. Tai YC, Tan JA, Peh SC. Higher frequency of p53 gene mutations in diffuse large B-cell lymphoma with MALT component. *Pathol Int.* 2004;54(11):811-8.
37. Qi-Xian T, Chew-Ean T, Abdul Rahim A, Nasaruddin RA. Orbital Tumours in Northern Malaysia: A Five-Year Review. *Cureus.* 2022;14(1):e20941.
38. Khaw B, Sivalingam S, Pathamanathan SS, Tan TS, Naicker M. Simultaneous non-Hodgkin lymphoma of the external auditory canal and thyroid gland: A case report. *Ear Nose Throat J.* 2014;93(12):508-11.
39. Pailoor J, Ramasamy V, Bahnu YS, Koay CE, Chang KM, Rajadurai P. Mantle cell lymphoma of palatine tonsil: A case report. *Respir Med Case Rep.* 2020;31:101218.
40. Lo R, Mohamad S, Krishnamoorthy M, Mohamad I, Zulkarnain S, Hussain FA. Mantle Cell Lymphoma: A Rare Vallecular Tumour. *Medeni Med J.* 2020;35(1):67-70.
41. Paul M, Asmi NH, Omar EK, Abdullah S, Mohamad I. Nasopharyngeal Mantle Cell Lymphoma: An Extremely Rare Entity. *Oman Med J.* 2019;34(1):74-7.
42. Shakri NM, Husain S, Zahedi FD, Tan GC. Nasal Plasmablastic Lymphoma in an HIV-Negative Immunocompetent Patient. *Medeni Med J.* 2020;35(1):71-4.
43. Johan S, Khairuddin A, Zuki AM, *et al.* Malignant ulcer: a great mimicker of gastric plasmablastic lymphoma. *Clin J Gastroenterol.* 2021;14(4):1027-30.
44. Wong YP, Masir N, Chew MX. CD3-positive plasmablastic lymphoma reported in two cases: A potential diagnostic caveat. *Indian J Pathol Microbiol.* 2021;64(3):579-83.
45. Lee KT, Misron NA, Abdul Aziz N, Wong CH, Liew HK. Spontaneous Regression of Plasmablastic Lymphoma in an Immunocompetent Patient: Case Report and Review of the Literature. *Case Rep Hematol.* 2022;2022:1142049.
46. Win TT, Kamaludin Z, Husin A. Primary mediastinal large B-cell lymphoma and its mimickers: a rare case report with literature review. *Malays J Pathol.* 2016;38(2):153-7.
47. Hjalgrim H, Askling J, Rostgaard K, *et al.* Characteristics of Hodgkin's lymphoma after infectious mononucleosis. *N Engl J Med.* 2003;349(14):1324-32.
48. Kim LH, Eow GI, Peh SC, Poppema S. The role of CD30, CD40 and CD95 in the regulation of proliferation and apoptosis in classical Hodgkin's lymphoma. *Pathology.* 2003;35(5):428-35.
49. Peh SC, Kim LH, Chai SP. The pattern of TARC, a CC chemokine, in Hodgkin's lymphomas, ALCL, TcRBcL and other lymphoproliferative disorders. *Malays J Pathol.* 2000;22(1):40-1.
50. Samer AS, Fayad EL. Treatment of Early Stage Hodgkin Lymphoma. *Hodgkin's Lymphoma.* InTech; 2012. Available from: <https://dx.doi.org/10.5772/34419>.
51. Swerdlow SH, Campo E, Pileri SA, *et al.* The 2016 revision of the World Health Organization classification of lymphoid neoplasms. *Blood.* 2016;127(20):2375-90.
52. Boo YL, Ting HSY, Yap DFS, Toh SG, Lim SM. Clinical features and treatment outcomes of Hodgkin lymphoma: A retrospective review in a Malaysian tertiary hospital. *Blood Res.* 2019;54(3):210-7.
53. Bosco J, Cherian R, Lin HP, Pang T. Leukaemia and lymphoma in Malaysia. *Leuk Res.* 1985;9(6):789-91.
54. Peh SC, Gudum HR, Tai YC, Wong FL, Dolkadir J. Spectrum of malignant lymphoma in Sarawak General Hospital. *J Clin Exp Hematop.* 2001;41(1):45-9.
55. Zainal Abidin I, Zulkarnaen AN, Dk Norlida AO, Wai Hoong C, Huong Ling L. Hodgkin lymphoma mimicking a large soft tissue sarcoma of the shoulder: the essential role of immunohistochemistry in histopathological diagnosis. *Malays J Med Sci.* 2012;19(4):72-6.
56. Ding CH, Kamarudin N. Non-neoformans cryptococcemia in a patient with hodgkin's lymphoma. *Asian J Pharm Clin Res.* 2018;11(12):7-8.
57. Saniasiaya J. Mediastinal lymphoma presenting with asymmetrical chest wall. *BMJ Case Rep.* 2022;15(1):e246953.
58. Khoo TT, Cheo SW, Low QJ, Tan YA, Wong LLL. Primary splenic hodgkin lymphoma masquerading as splenic abscess. *Med J Malaysia.* 2021;76(1):118-20.
59. Ting XW, Sothiraghagan S, W Md Kasim WM, Muhammed J. A Clinicopathologic Study of Seven Cases of Orbital Solitary Fibrous Tumours. *Cureus.* 2020;12(5):e8259
60. Lim JA, Wong PS, Leong KN, Wong KL, Chow TS. Masking and misleading: concomitant actinomycosis and B-cell lymphoma - a case report and review of literature. *Scott Med J.* 2018;36933018789312.
61. Ramachandram K, Jalaluddin A. Ovarian lymphoma with mixed epithelial carcinoma arising in the same ovary - case report. *Malays J Pathol.* 2000;22(1):51-2.
62. Zakaria Mohamad Z, Kow RY, Low CL, Hamdan AH, Awang MS. Primary B-cell Lymphoma of the Thoracic Spine: A Rare Cause of Spinal Cord Compression. *Cureus.* 2021;13(7):e16608.
63. Lee WS, Chan TL, Koh MT, Ariffin WA, Lin HP. Acquired immunodeficiency syndrome presenting as childhood non-Hodgkin's lymphoma. *Singapore Med J.* 2001;42(11):530-3.
64. Muin IA, Saffari HM, Hasimah YN. Primary non-Hodgkin's lymphoma of the cranial vault mimicking a meningioma: a case report. *Med J Malaysia.* 1997;52(1):86-8.