

Article

Ultrasound evaluation of Achilles tendon thickness in asymptomatics: A reliability study

Kharate, Priyanka and Chance-Larsen, Kenneth

Available at <http://clock.uclan.ac.uk/20415/>

Kharate, Priyanka and Chance-Larsen, Kenneth ORCID: 0000-0002-7619-4054 (2012) Ultrasound evaluation of Achilles tendon thickness in asymptomatics: A reliability study. International Journal of Physiotherapy and Rehabilitation, 2 . pp. 1-11. ISSN 2349-5987

It is advisable to refer to the publisher's version if you intend to cite from the work.

For more information about UCLan's research in this area go to <http://www.uclan.ac.uk/researchgroups/> and search for <name of research Group>.

For information about Research generally at UCLan please go to <http://www.uclan.ac.uk/research/>

All outputs in CLoK are protected by Intellectual Property Rights law, including Copyright law. Copyright, IPR and Moral Rights for the works on this site are retained by the individual authors and/or other copyright owners. Terms and conditions for use of this material are defined in the [policies](#) page.

ORIGINAL PAPER

Ultrasound evaluation of Achilles tendon thickness in asymptomatic's: A reliability study.

Priyanka Kharate and Kenneth Chance-Larsen
*Faculty of Health and Wellbeing, Robert Winston Building, Collegiate Crescent Campus,
Sheffield Hallam University, Sheffield S10 2BP.*
Email: k.chance-larsen@shu.ac.uk

Abstract

Background: Achilles tendon disorders are among the most common maladies encountered in sports medicine. Increased tendon thickness is considered to be a risk factor for Achilles tendon disorders. Ultrasonography is currently the modality of choice that best demonstrate the Achilles tendon abnormalities. This study investigated Intra-rater reliability of ultrasound in Achilles tendon thickness measurements among asymptomatic's, performed by a qualified physiotherapist with limited ultrasound training.

Method: A test retest reliability design was used. 25 healthy participants were recruited from Sheffield Hallam University. Achilles tendon thickness measurements were performed on two occasions, approximately 30 minutes apart; by the same rater, under same testing conditions.

Results: The Intraclass correlation coefficient (ICC) for intra-rater reliability was found be excellent (ICC =0.935; 95% confidence interval, 0.88-0.96).

Implications: Ultrasound can be used in the field of physiotherapy as a clinical tool for prevention, assessment and monitoring rehabilitation of athletes.

Conclusion: Ultrasound evaluation of Achilles tendon thickness can be reliably performed by a qualified physiotherapist with limited ultrasound training. Further research is required to investigate inter rater reliability and among different patient populations with proper US training.

Keywords: ultrasound, Achilles tendon thickness, reliability, intra-rater reliability

Introduction

Tendons are connective tissues that transmit the force produced by muscle to bone and also prevent muscle damage by acting as shock absorbers (Levangie and Norkin 2001). The Achilles tendon is the single largest, thickest and strongest tendon in the human body that transmit the force of powerful calf muscles to foot facilitating walking and running (Ying et al 2003). This has long been known as a site susceptible to disabling injury. Forces up to 12 times bodyweight may arise during sporting activity (Levangie and Norkin 2001). Achilles tendon disorders are among

the more frequent maladies encountered in sports medicine (Schepisis et al 2002). They are not only common but has shown enormous rise in incidence over the past three decades (Kader et al 2002; Maffulli et al 2004; Syha et al 2010). They are commonly associated with overuse sports injuries (Syha et al 2010) and can bring a sports career to a premature end. The combined adaptive and micro traumatic course of action that produces an increase in the level of glycoprotein matrix, tenocyte and fibroblast proliferation leads to degeneration of tendon by forming disorganized collagen (Riley 2004). This pathological process leads to thickening, vascularisation and hypoechogenicity of the diseased tendon (Martinoli et al 1999).

The various types of overuse tendon injuries include tendinopathies, peritendinitis and tendon rupture (Karjalainen et al 2000). Increased tendon thickness is the most commonly mentioned indicator of tendinopathies (Nehrer et al 1997; Paavola et al 1998). A significant correlation between progressive Achilles tendon thickening, Achilles tendon rupture and tendon abnormalities has been reported in previous studies (Nehrer et al 1997; Eriksen et al 2002). Identification of high risk subjects of these debilitating tendon conditions could lead to better prevention. Measurement of tendon thickness and detection of increased size is thus an important tool for assessment of tendons. The normal Achilles tendon thickness interval is largely unknown and varies considerably (from 4.2 to 7.1mm). It is reported to be influenced by factors like body stature, height and by ethnic factors (Koivunen-Niemela and Parkkola 1995; Bjordal et al 2003).

The current imaging modalities of choice that best demonstrate and are most helpful in delineating abnormalities within Achilles tendon are Ultrasound (US) and Magnetic Resonance Imaging (MRI). Radiography has been reported in the past to present valuable information about diseased Achilles tendon but is no longer considered to be the modality of choice for detecting tendon disorders (Kader et al 2002). MRI can illustrate the tendon pathology in detail (Karjalainen et al 2000). But, the therapeutic guidelines based on MRI are missing, and its importance in clinical decision making has not been established (Kader et al 2002).

Ultrasonography is a quick, relatively less expensive, safe (no radiation danger), non-invasive and widely accessible imaging technique for tendon assessment (Grassi et al 2000; O'Connor et al 2004). The high acoustic contrast of tendons with the adjoining tissues makes them particularly suitable for Ultrasonographic evaluation (O'Connor et al 2004). Ultrasound imaging has higher spatial resolution for superficial tendon structures than MRI and also allows for dynamic examination with real time feedback (Grassi et al 2000; O'Connor et al 2004). US imaging a clinically applicable diagnostic method for detection and examination of asymptomatic overuse tendon injuries among athletes. Moreover, imaging of asymptomatic tendons can aid in identifying athletes at increased risk of developing tendon injuries (Fredberg and Bovig 2002). US images can measure Achilles tendon thickness as well as quantify the degeneration of the tendon (Syha et al 2010).

The use of clinically reliable tools is necessary to ensure accurate diagnosis of a condition; to formulate effective treatment plan based on the obtained information (May et al 2006) and also for effective evaluation of the clinical outcomes acquired from the chosen intervention. It has been reported that ultrasonography has good to high reliability in measuring Achilles tendon thickness (O'Connor et al 2004; Ying et al 2003, Koivunen-Niemela and Parkkola 1995). Kalebo et al (1992) conducted a reliability study for diagnosing partial Achilles tendon rupture using US

and found that US had a sensitivity of 0.94, a specificity of 1.00, and an accuracy of 0.95. However, the reliability results of US are often user dependent and largely appear to correlate with the skill and experience of the operator (Schepisis et al 2002).

To obtain comparable tendon thickness sonographic images on consecutive examinations is vital to ascertain proper use of US in clinical practice as well as in follow-up research studies (Grassi et al 2000). For standardization of the Ultrasonic procedure factors such as positioning of the transducer, instrument setting, probe pressure on the skin, the angle between the US beam and tendon, patient positioning and use of a standoff pad have to be taken into consideration (Connor et al 2004). The research available in relation to the effects of these factors is narrow thus giving a good justification of unproven inter and intra- rater reliability.

Previous studies have assessed the diagnostic performance of tendon US with surgical correlation, however, availability of reproducible data is limited (Waitches et al 1998; Chen and Liang 1997). Futhermore, few research studies have evaluated the variability of diagnostic US findings, but this was not the key aim of these studies and the also their conclusions have shown to be limited (Richards et al 2001; Civeira et al 1998).

Ultrasonography as a diagnostic tool is traditionally and widely practiced by radiology professionals but due to latest and advanced technical developments, its use has been expanded and become available to other healthcare professions including physiotherapy (McKiernan et al 2010). In order to justify intervention and judge its efficacy, physiotherapists need to integrate objective measures in their clinical practice. Diagnostic US is currently been used by physiotherapists most commonly as a biofeedback tool in functional retraining of muscles (McKiernan et al 2010).

Increased Achilles tendon thickness has been implicated to be a contributing factor in overuse injuries of the foot (Kader et al 2002; Werd 2007). It is therefore essential for physiotherapists to carry out timely assessment of Achilles tendon with a reliable measuring tool. The reliability of US as a technique for testing Achilles tendon thickness has been established by experienced researchers, but its benefits lie in its ease of reproducibility by practitioners of varying experience, especially in areas such as musculoskeletal therapy and sports physiotherapy. This study being preliminary in nature would be able to examine this element of reproducibility to be exercised by qualified physiotherapists with limited experience so as to examine the extent to which US can be used on a wide scale. In most occasions, sportspersons have personal physiotherapists allocated to evaluate them on routine basis. Additionally, inter-observer variability is reported to be a higher source of error than intra-observer variability (O'Connor et al 2004). Therefore, evaluating the intra-rater reliability of ultrasound is essential. The outcomes of this research would also aid in forming a platform for future research on the applicability of US as a diagnostic tool routinely in musculoskeletal physiotherapy and sports physiotherapy.

The main purpose of this study was to test intra-rater reliability in sonographic measurements of Achilles tendon thickness and to investigate if a qualified physiotherapist with limited ultrasound training can perform a reliable US imaging examination of Achilles tendon thickness.

Methods

Study Design

This study used a test-retest research design to determine intra-rater reliability of ultrasound in measuring Achilles tendon thickness. The participants were tested on 2 occasions, approximately 30 minutes apart, by the same rater, under same test conditions.

Participants

The sampling method was that of a convenient purposive nature (Bowling 2009). Twenty five healthy (50 tendons) subjects participated in this investigation. They were selected from a pool of students at Sheffield Hallam University (SHU) which also involved volunteers, friends and colleagues. The age range of the participants was 18 to 30 years. Previous studies suggested that the peak incidence of Achilles tendon disorders was within this chosen age group (20-40years) (Kevist 1991; Copeland 1990; Rollandi et al 1995). Subjects were informed to avoid any arduous physical activity or exercises (e.g. running, cycling etc) on the study day as this has been found to cause an increase in tendon thickness (Ying et al 2003). Only patients without tendon pain/discomfort, ankle injuries / Achilles tendon surgeries, any potentially ailing conditions (e.g. systemic diseases or inflammatory conditions) were permitted to enter the study.

Due to lack of experience in the imaging field, training was undertaken from the staff and technicians of Sheffield Hallam University (SHU) to learn and get acquainted with the scanning technique. Prior to the conduction of the main study, a pilot study was undertaken involving 4 subjects (8 tendons) to identify any potential errors in the planned study layout. The research information sheet regarding the aims of the study, imaging procedure, rights of the subjects and the safety of US, was given to the participants. Each subject gave a written informed consent prior to the commencement of the study. The study was approved by SHU Ethics Committee before contact was made with the potential participants.

Experimental approach

Instrumentation

The SonoSite 180 Plus Ultrasound System was used to objectively measure Achilles tendon thickness with a 10 MHz linear transducer (Figure 1).

Procedure

Each participant was assigned a day and time to visit SHU, physiotherapy department for data collection. To ensure reproducibility of results and clinical relevance, a standardized protocol was developed.

The subjects lay in a prone position with ankles extended beyond the examination bed. Each ankle was held in 90° which was measured with the goniometer. This position was chosen to facilitate contact between the probe and the tendon and to avoid anisotropy effect which can occur if the tendon is not taut (Koivunen-Niemela and Parkkola 1995; Dong and Fessell 2009). The foot rested against the wall to maintain a constant angle (Figure 2). For each subject US scans were performed bilaterally. A longitudinal view of the Achilles tendon was obtained with

the transducer placed in sagittal plane, just proximal to calcaneal insertion (Leung and Griffith 2007; Dong and Fessell 2009) (Figure 3). Distances were measured by built in calipers at the level where the tendon separates from calcanei, at a point where the thickness was observed to be at its maximum (Bjordal et al 2003) (Figure 4). This site was chosen for measuring tendon thickness as it is the most frequent site for tendon pathology (Gibbon et al 2000). Blinded measurements were performed on both the occasions by covering the readings on the monitor screen. Data was recorded by another observer who was not a part of the study.



Figure 1: SonoSite 180 Plus Ultrasound System.

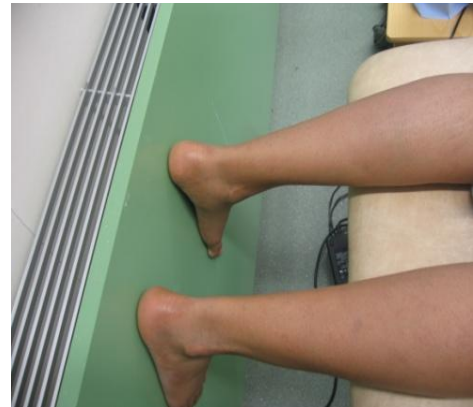

Figure 2: Participant positioning.

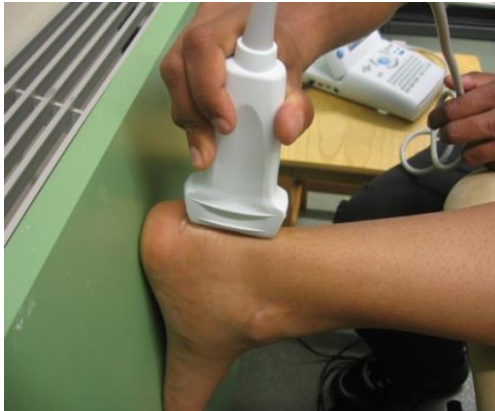

Figure 3: Positioning of the transducer.

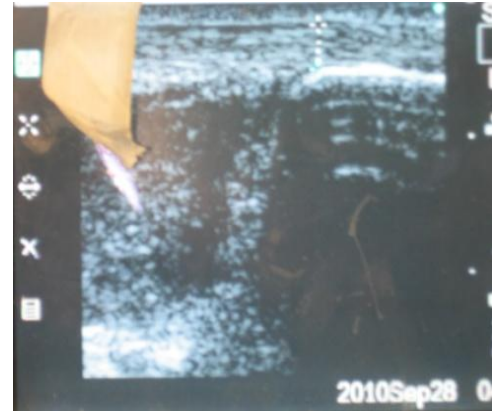


Figure 4: Sonogram showing longitudinal scan of Achilles tendon. Calipers indicate the measurement of tendon thickness

Data Analysis

All the data collected for each subject was compiled in a Microsoft Excel spreadsheet. For statistical analysis, Statistical Package for the Social Sciences (SPSS) software version 18.0 was used. Means and standard deviations (SDS) were calculated from initial and final data collection periods. Intra-rater reliability was calculated using Intraclass Correlation Coefficient (ICC). The model and type chosen were Two-way random and absolute agreement respectively.

Results

In the 25 subjects, a total of 50 (N= 50) Achilles tendons were examined (14 men and 11 women). Overall the mean age \pm SD was 25 ± 1.8 yrs. Results for Intrarater reliability of ultrasound for evaluation of Achilles tendon thickness are given in table 1. For measurement of tendon thickness, ICC was found to be 0.935 (upper 95% CI = 0.88; lower 95% CI = 0.96).

| Achilles tendon thickness (Initial test) | Achilles tendon thickness (Retest) | Intra-rater reliability (ICC) | 95% Confidence Interval | |
|---|---------------------------------------|----------------------------------|-------------------------|-------------|
| | | | Lower Bound | Upper Bound |
| 3.65 \pm .55 | 3.62 \pm .50 | .935 | .888 | .962 |

Table 1: Intra rater reliability of Ultrasound in Determining Achilles tendon thickness. Values are mean millimeters \pm SD

Discussion

Ultrasonography is commonly used for examination of Achilles tendons (Yoho and Slate 1999); however, to establish its usefulness as a measuring tool into physiotherapy practice, it is necessary to verify its accuracy in measuring Achilles tendon thickness.

In the recent years, ICC has become more popular and is the most recommended convention to quantify measurement reliability; as it reflects both aspects of test-retest reliability, correlation and agreement, using one index (Portney and Watkins 2000). According to Portney and Watkins, ICC ranging from 0.50 to 0.75 is considered moderate to good whereas ICC values above 0.75 indicate a good to excellent reliability. The correlation coefficients of 0.93 attained in this study denote that excellent intra-rater reliability is achieved. This study supports the use of US as an objective measuring tool in physiotherapy practice for measuring Achilles tendon thickness. Limited training of the rater did not appear to influence the repeatability of Achilles tendon thickness measurements.

Several previous studies have evaluated the reliability of US in measuring Achilles tendon thickness. O'Connor et al (2004) compared the sonographic findings of 11 healthy male subjects and concluded that good reproducible Achilles tendon thickness measurements can be obtained using US. Likewise, a reliability study on a Chinese population demonstrated that ultrasonography has high reproducibility in measurements of Achilles tendons (Ying et al 2003). Koivunen-Niemela and Parkkola (1995) conducted a study to investigate the reliability of US and MRI in measuring Achilles tendon thickness among healthy individuals. The sonographic findings demonstrated significantly higher reproducibility than MRI findings. However, it is difficult to compare the results of these studies with the current study due to differences in methodology. All of the above mentioned studies used different scanning protocols to measure tendon thickness and varied methods to calculate reliability.

The current study describes procedures that showed excellent intra-rater reliability in measuring Achilles tendon thickness with US by using relatively simple techniques performed by a qualified physiotherapist with limited US training unlike previously conducted studies which involved experienced professionals. Amongst all the studies, Ying et al (2003) alone used ICC to test reliability but evaluated only inter-rater reliability (ICC = 0.68). O'Connor et al (2004) evaluated both intra-rater and inter-rater variability using the ANOVA model and found that inter-observer variability was a greater source of error than intra-observer variability. Koivunen-Niemela and Parkkola (1995) analyzed intra-rater reliability by simply calculating standard deviations. The mean difference from the initial test measurement was found to be 0.2mm \pm 0.5 SD.

In the study conducted by O' Connor et al (2004) and Ying et al (2003), transverse view of Achilles tendon was obtained whereas the present study scanned the tendons longitudinally. It is found that transverse scans overestimate the tendon thickness (10%) by including epitenon and paratenon compared to longitudinal scans (Parkkola and Koivunen-Niemela 1995; Kallinen and Suominen 1994). Also, the likelihood of measurement errors is greater in transverse scans as it allows proximal, distal as well as medial lateral movement of the transducer. It is reported that intra-observer variability in sonographic measurements of Achilles tendon thickness is less in longitudinal scans than transverse scans (Fredberg et al 2008). A higher kappa value was found by Richard et al (2001) in longitudinal scans, where as Kallinen and Suominen (1994) reported equivalent SD for transverse and longitudinal scans. Parkkola and Koivunen-Niemela (1995) scanned the tendons both longitudinally and transversely.

Another difference between the O'Connor et al (2004), Parkkola and Koivunen-Niemela (1995) study and the present study was that, the retest measurements were performed a week later and 6 months later respectively. However, the retest measurements in this study were carried out 30 minutes apart to prevent any drop outs and due to limited time available to conduct the research.

Study strengths and limitations

As the tendons vary in thickness along their length, a standardized experimental approach was developed and undertaken to ensure that readings were taken at the same point during every occasion. The examination procedure may be used as a reliable framework for future evaluation of symptomatic tendons. During all the Ultrasononic examinations, the operator was blinded to the data registered. The readings on the monitor screen were covered every time Achilles tendon thickness was tested. Another observer who was not a part of the study noted all the measurements. The risk of operator bias was reduced to a great extent due to blinding.

One of the limitations of this study was that, the results were based on a relatively small number of subjects (N=25) which can be attributed to time constraints of the study. No power calculation was undertaken to determine actual sample size. It would be essential to find out if a physiotherapist with limited training would be able to obtain more accurate results if the sample size was large. Secondly, the retest measurements were carried out approximately 30 minutes apart which might have introduced unacceptable levels of operator memory bias given the small number of participants resulting into excellent reliability. In the examination procedure, no

consideration has been given to the application pressure of the US transducer while measuring tendon thickness as this is likely to influence the results obtained.

Clinical implications

Proper functioning of Achilles tendon is important to perform efficiently in sporting activity. Achilles tendon injuries account for almost 5% to 10% of all running injuries (Werd 2007). Early diagnosis of Achilles tendon disorders can minimize the duration of rehabilitation and long term disability (Turmezei et al 2010). Early intervention is essential to provide the athlete with the best chance of returning to sport activity as early as possible and avoiding the chances of repeated injury (Schepsis et al 2002).

The data of the present study suggest that US can be used clinically in musculoskeletal and sports physiotherapy for measuring Achilles tendon thickness as a reliable assessment tool. US visualization can prove to be a beneficial tool which could be used routinely by physiotherapists. Physiotherapists can incorporate the use of US into routine examination of sport professionals. It can aid in early detection of players at risk of Achilles tendon disorders, thereby preventing the risk of potential injury (Fredberg and Bovig 2002). Authors indicate that it can be used as an outcome measure in continually monitoring an athlete's progress to ensure effectiveness of the treatment (Whittaker et al 2007). It can assist efficiently in prevention, assessment and monitoring the rehabilitation of professional athletes.

Research implications

Although this study illustrated excellent intra-rater reliability, the results cannot be generalized to other physiotherapists assessing tendon thickness. Future research is needed into inter-rater reliability of US in determining Achilles tendon thickness to be performed by physiotherapists with proper US training. It is important to establish inter-rater reliability as different raters are not always in agreement about the quantity or quality of the variable being tested (Taylor and Bandy 2005). Also, the current study assessed Achilles tendon only longitudinally. Further studies should evaluate tendons both transversely and longitudinally. Comparing longitudinal and transverse scans is preferable for sonographic confirmation of tendon alterations to prevent any artifacts or pitfalls due to improper angulation between the US beam and the tendon (Grassi et al 2000). In addition, in this study asymptomatic subjects were examined, future research should be conducted involving different patient populations.

Conclusion

This study investigated intra-rater reliability of US in measuring Achilles tendon thickness and found that it can be reliably performed by a qualified physiotherapist with limited US training. This study provides evidence to support the use of US as an objective measurement tool in physiotherapy practice for measuring Achilles tendon thickness. Further research is needed to evaluate inter-rater reliability and among different patient populations with proper US training.

Acknowledgement

The authors wish to acknowledge Sheffield Hallam University (SHU) for providing an opportunity to conduct this research. The authors are also thankful to the technical staff of SHU (Collegiate Crescent campus), Robert Winston building and also to all participants for their co-operation and valuable time in aid of primary data collection of the study.

References

- Bjordal JM, Demmink JH and Ljunggren AE (2003) Tendon thickness and depth from skin for supraspinatus, common wrist and finger extensors, patellar and Achilles tendons: Ultrasonography study of healthy subjects. *Physiotherapy*, 89(6); 375-383.
- Bowling, A (2009) *Research methods in health: Investigating health & health services*. 3rd Edition, Open University Press; Glasgow
- Chen Y and Liang S (1997) Diagnostic efficacy Ultrasonography in stage I posterior tibial tendon dysfunction: sonographic-surgical correlation. *Journal of Ultrasound in Medicine*, 16; 417-423.
- Civeira F et al (1998) Achilles tendon size by high resolution sonography in healthy population: relationship with lipid levels. *Med Clin (Barc)*, 111; 41-44.
- Copeland, S (1990) Rupture of the Achilles tendon: A new clinical test. *Annals of Royal College of Surgeons England*, 72; 270–271.
- Dong Q and Fessell D (2009) Achilles tendon ultrasound technique. *American Journal of Roentgenology*, 193; W173.
- Eriksen HA, Pajala A, Leppilahti J and Ristelli J (2002) Increased content of type III collagen at the rupture site of human Achilles tendon. *Journal of Orthopaedic Research*, 20; 1352-1357.
- Fredberg U, Bolvig L, Andersen NT and Stengaard-Pedersen K (2008) Ultrasonography in evaluation of Achilles and patella tendon thickness. *Ultraschall in der medizin*, 29 (1); 60-65.
- Fredberg U and Bolvig L (2002) Significance of ultrasonographically detected asymptomatic tendinosis in the patellar and Achilles tendon of elite soccer players: a longitudinal study. *American Journal of Sports Medicine*, 30; 488-491.
- Gibbon WW, Cooper JR and Radcliffe GS (2000) Distribution of sonographically detected tendon abnormalities in patients with a clinical diagnosis of chronic Achilles tendinosis. *Journal of Clinical Ultrasound*, 28; 61-66.
- Grassi W, Filippucci E, Farina A and Cervini C (2000) Sonographic imaging of tendons. *Arthritis & Rheumatism*, 43(5); 969-976.
- Kader D et al (2002) Achilles tendinopathy: some aspects of basic science and clinical management . *British Journal of Sports Medicine*, 36; 239-249.
- Kalebo P et al (1992) diagnostic value of ultrasonography in partial ruptures of the Achilles tendon. *American Journal of Sports Medicine*, 20; 378-381.

Kallinen, M and Suominen, H (1994) Ultrasonographic measurements of the Achilles tendon in elderly athletes and sedentary men. *Acta Radiologica*, 35; 560-563.

Karjalainen PT, Soila K, Aronen HJ, et al. MR imaging of overuse injuries of the Achilles tendon. *American Journal of Roentgenology*, 175; 251–60.

Kivist M (1991) Achilles tendon injuries in athletes. *Ann Chir Gynaecol*, 80; 188-201.

Koivunen-niemela T and Parkkola K (1995) Anatomy of Achilles tendon (tendo calcaneus) with respect to tendon thickness measurements. *Surgical and Radiologic Anatomy*, 17; 263-268.

Leung J, Griffith J (2008) Sonography of chronic Achilles tendinopathy: A case–control study. *Journal of Clinical Ultrasound*, 36(1); 27-32.

Levangie P and Norkin C (2001) Joint structure and function: a comprehensive analysis. 3rd Edition, New Delhi; Jaypee Brothers

Maffulli N, Waterston SW, Squair J, Reaper J and Douglas AS (1999) Changing incidence of Achilles tendon rupture in Scotland: A 15-year study. *Clinical Journal of Sports Medicine*, 9; 157–160.

Martinoli C, Bianchi S and Derchi L (1999) Tendon and nerve sonography. *Radiologic Clinics of North America*, 37; 691–711.

McKiernan S, Chiarelli P and Warren-Forward H (2010) Diagnostic ultrasound use in physiotherapy, emergency medicine, and anesthesiology. [Radiography](#), 16(2); 154-159.

May S, Littlewood C and Bishop A (2006) Reliability of procedures in the physical examination of non-specific low back pain: a systematic review. *Australian journal of physiotherapy*, 52; 91-102.

Nehrer S et al (1997) Clinical and sonographic evaluation of the risk of rupture in the Achilles tendon. *Archives of Orthopaedic Trauma and Surgery*, 116; 14-18.

O'Connor P, Grainger AJ, Morgan SR, Smith KL, Wateron JC and Nash AFP (2004) Ultrasound assessment of tendons in asymptomatic volunteers: a study of reproducibility. *European Journal of Radiology*, 14; 1968-1973.

Paavola M, Pakkala T, Kannus T and Jarvinen M (1998). Ultrasonography in differential diagnosis of Achilles tendon injuries and related disorders: A comparison between pre-operative Ultrasonography and surgical findings. *Acta Radiologica*, 39; 612-619.

Portney L and Watkins M (2000) Foundations of clinical research. Applications to practice. New Jersey: Prentice-Hall

Richards P, Dheer A and McCall I (2001) Achilles tendon (TA) size and power Doppler ultrasound (PD) changes compared to MRI: a preliminary study. *Clinical Radiology*, 56; 843-850.

Riley G (2004) The pathogenesis of tendinopathy: A molecular prospective. *Rheumatology*, 43; 131-142.

Rollandi A et al (1995) MRI of normal Achilles tendon. *European Radiology*, 5; 590–596.

Schepsis AA, Jones H and Haas A (2002) Achilles tendon disorders in athletes. *The American Journal of Sports Medicine*, 30(2); 287-305.

Syha R et al (2010) Computer-based quantification of the mean Achilles tendon thickness in ultrasound images: Effect of tendinosis. *British Journal of Sports Medicine*, 41; 897-902

Taylor JD and Bandy WD (2005) Intrarater reliability of the KT1000 arthrometer in determining anterior translation of the glenohumeral joint. *American Congress of Rehabilitation Medicine and the American Academy of Physical Medicine and Rehabilitation*, 86; 826-829.

Turmezei TD, Yu D and Kerslake RW (2010) The Role of Imaging in Sports Medicine. *European Musculoskeletal Review*, 25(1); 82–88.

Waitches GM, Rockett M, Brage M and Sudakoff G (1998). Ultrasonographic surgical correlation of ankle tendon tears. *Journal of Ultrasound in Medicine*, 17; 249-256.

Werd MB (2007) Achilles tendon sports injuries: A review of classification and treatment. *Journal of the American Podiatric Medical Association*, 97(1), 37-48.

Whittaker J (2006) Current perspectives: the clinical application of ultrasound imaging by physical therapists. *The Journal of Manual & Manipulative Therapy*, 14; 73–75.

Ying M, Emmy Y, Brian L, Winnie L, Mandy L and Tsoi CW (2003) Sonographic evaluation of the size of Achilles tendon: The effect of exercise and dominance of the ankle. *Ultrasound in Medicine and Biology*, 29(5); 637-642.

Yoho RM and Slate RE (1999) Achilles tendon rupture: diagnosis and management. *Clinics in Podiatric Medicine and Surgery*, 16; 617-630.