

Central Lancashire Online Knowledge (CLOK)

Title	Effectiveness of Additive Manufactured Titanium Implants in the Reconstruction of Large Cranial Defects: Case Series and Review of Literature
Type	Article
URL	https://clock.uclan.ac.uk/id/eprint/50171/
DOI	https://doi.org/10.1007/s12663-023-02085-1
Date	2023
Citation	Chakranarayan, Ashish, Kumari, Pushpa, Nagori, Shakil Ahmad, Suddhan, Manoharan Dwark, Menon, P Suresh and Kapri, Anita (2023) Effectiveness of Additive Manufactured Titanium Implants in the Reconstruction of Large Cranial Defects: Case Series and Review of Literature. Journal of Maxillofacial and Oral Surgery. ISSN 0972-8279
Creators	Chakranarayan, Ashish, Kumari, Pushpa, Nagori, Shakil Ahmad, Suddhan, Manoharan Dwark, Menon, P Suresh and Kapri, Anita

It is advisable to refer to the publisher's version if you intend to cite from the work.
<https://doi.org/10.1007/s12663-023-02085-1>

For information about Research at UCLan please go to <http://www.uclan.ac.uk/research/>

All outputs in CLOK are protected by Intellectual Property Rights law, including Copyright law. Copyright, IPR and Moral Rights for the works on this site are retained by the individual authors and/or other copyright owners. Terms and conditions for use of this material are defined in the <http://clock.uclan.ac.uk/policies/>



Effectiveness of Additive Manufactured Titanium Implants in the Reconstruction of Large Cranial Defects: Case Series and Review of Literature

Ashish Chakranarayan¹ · Pushpa Kumari² ·
Shakil Ahmad Nagori³ · Manoharan Dwark Sudhan⁴ ·
P. Suresh Menon⁵ · Anita Kapri²

Received: 31 July 2023 / Accepted: 30 November 2023
© The Author(s) 2023

Abstract

Introduction Replacement of lost soft and hard tissues of the human body has always been a daunting task across all surgical specialties. Reconstruction of a cranial deformity is challenging due to the functional and cosmetic requirements. A major constraint with large cranial bony deformity reconstruction is the nonavailability of graft of a specific shape and size.

Materials and Method A total of four cases of large cranial defects which included three cases of unilateral and one case of midline residual deformity were reconstructed at our center using customized titanium implants. These implants

were fabricated using additive manufacturing/3D printing technology utilizing computerized tomographic data.

Conclusion The additively manufactured titanium implants appear to be a viable option in the reconstruction of large cranial defects.

Keywords Craniectomy · Craniotomy · Cranioplasty · Residual cranial deformity · Additive manufacturing · 3D printing · Cranial bone · Titanium cranial implant

Introduction

As far as the human body is concerned, “God given” is peerless. In the pursuit of immortality, clinicians and scientists have been persevering to find ideal replacements for diseased or lost human tissue. Due to various reasons, the replacement of missing soft and hard tissues of the human body has always been a daunting task across all surgical specialties. The ideal replacement material would be a similar tissue or organ, and in a large number of cases, owing to bilateral similarity, native tissue such as skin, mucosa, muscle, bone, organ, etc., is available for harvest. However, the size, shape, and vascularity are often the important limiting factors. Residual deformity of the cranium following trauma or surgery is commonly encountered in clinical practice [1]. Reconstruction of a cranial deformity is peculiar due to the functional and cosmetic requirements. Historically, based on the available evidence, the Incan civilization was probably performing precious metal cranioplasty-like procedures; however, the first documented report is by Fallopius in the sixteenth century [2]. The benefits of cranial reconstruction in allaying the symptoms of the syndrome of the trephine/sinking flap syndrome (SFS) have been widely reported

✉ Ashish Chakranarayan
ashish.chakranarayan@gmail.com

Pushpa Kumari
drpushpamishra@gmail.com

Shakil Ahmad Nagori
drshakilnagori@gmail.com

Manoharan Dwark Sudhan
md_sudhan@yahoo.co.in

P. Suresh Menon
psurmenon@gmail.com

Anita Kapri
anitakapri@gmail.com

¹ University of Central Lancashire,
Preston, Lancashire PR1 2HE, UK

² INHS Kalyani, Visakhapatnam, AP 530005, India

³ INDC Danteshwari, RC Church Colaba, Mumbai,
MH 400005, India

⁴ Neurosurgery Centre, INHS Asvini, Mumbai, India

⁵ Department of Oral & Maxillofacial Surgery, Vydehi
Institute of Dental Sciences & Research Center, Whitefield,
Vijayanagar, Nallurhalli, Bengaluru, Karnataka 560066, India

in the literature thereafter [3]. In many cases the neurosurgeon can perform an access osteotomy which largely preserves the shape and size of the bone flap. These flaps are then either stored in the abdominal wall or anterior thigh for later use. However, in many instances, the access procedure leaves the bone flap unusable, thereby warranting a reconstruction using other materials. This is done to provide protection to the underlying brain tissue and to restore cosmetics. A major constraint with large cranial bony deformity reconstruction is the nonavailability of graft of a specific shape and size. Over the years, various methods have been developed and used to replace the missing cranial bone to reconstruct a residual deformity of the skull [2]. The most preferred option is a local bone graft harvested from the contralateral side of the cranium [4]. Some of the other methods which have been popular are the use of polymethyl methacrylate (PMMA) plates, porous polyetheretherketone (PEEK), and titanium meshes. Though being relatively cost-effective and commonly available, all these methods have severe limitations in terms of allergic reaction, percutaneous exposure, and inability to restore desired shape, respectively [5]. The use of cranial distraction osteogenesis has been widely reported for management of different kinds of synostotic conditions; however, the employability of this technique for treating residual deformity has not been observed much [6]. Technological advancement in the field of rapid prototyping has made available to the clinician, a very viable substitute for the lost cranial bone tissue, which may be able to overcome most limitations of the conventional methods of cranial deformity reconstruction. Our study attempts to elaborate the use of customized titanium implants which are commonly referred to as patient-specific implants (PSI). These were fabricated using the additive manufacturing technology. This recently emerged technology has shown exponential progress in the fields of medicine, aerospace, energy, consumer products, and transport [7]. Using the STROBE guidelines to the best possible extent, we intend to demonstrate the clinical effectiveness of these implants as a viable substitute to the other methods of cranial reconstruction and review the relevant literature with regard to the reconstruction techniques and their advantages and disadvantages.

Materials and Method

The retrospective descriptive study included cases operated at our center from September 2020 to April 2022. All cases were referred from the Department of Neurosurgery for reconstruction of cranial residual deformity. The surgery protocol was approved by the institutional review board and the patient's consent was obtained for administration of general anesthesia, surgical procedure, and scientific publication subsequently. The age range was from 28 to 65 years and comprised of all male patients. The Glasgow Coma Scale (GCS) in two cases was 15 and in one case 13 and 8 each [Table 1]. One case was secondary to improper storage of the bone flap after a decompressive craniectomy in a case of uncontrolled hypertension [Fig. 3]. In this case, although the shape and size of the bone flap were optimal, it was deemed unfit for replacement due to improper storage after the primary surgery. The remainder of three cases were of residual deformity after a neurosurgical intervention for management of head injury due to road traffic accidents [Table 1]. All cases were systemically stable with no uncontrolled comorbidities. Routine preoperative blood and urine examination was done as per the anesthesiology requirement. Computerized tomography (CT) was done in 1-mm axial and coronal slices. Volume-rendered radiographic images were developed based on these data. The CT data were provided to the manufacturer on a compact disc for fabrication of titanium PSI for all cases [Table 1]. The surgery was carried out under general anesthesia with a reinforced oral endotracheal tube. Preoperatively, injection dexamethasone 8 mg iv was administered approximately 1 h prior to the procedure along with a broad-spectrum antibiotic cover which included injection amoxicillin 1000mg + clavulanic acid 200mg iv, injection amikacin 750 mg iv, and injection metronidazole 500 mg iv. The perioperative anesthetic drugs and management were as per the standard protocols. The patient was scrubbed neck above and draped aseptically. The operating table was adjusted to a comfortable head-up position. The incision line which was along the scar of the previous surgical intervention was infiltrated with 10 to 15 cc of 1:100,000 adrenaline in normal saline at the supra-pericranial level. A flap was raised to delineate the scalp from the dura mater. In all unilateral cases, the elevation of

Table 1 Patient demographics

S. no.	Etiology	Number of cases	Number of sites	GCS		Number and type of neurosurgical surgeries/procedures prior to cranioplasty	Time duration after the last neurosurgical intervention (months)
				Pre-op	Post-op		
1	RTA	1	Bilateral	15	15	03/Craniectomy/brain abscess drainage	02
2	RTA	1	Unilateral	15	15	01/Craniectomy	02
3	Stroke	1	Unilateral	13	15	01/Craniectomy	24
4	RTA	1	Unilateral	8	8	02/Craniectomy/VP shunt placement	02

the flap to expose the area of interest was uneventful [Figs. 2, 3]; however, in the patient requiring bilateral reconstruction, there were two breaches in the underlying pericranium/dura layer [Fig. 1]. These were uneventfully sutured using 3–0 resorbable suture. Sufficient exposure of the area of interest involved exposure of the bony margins of the defect in anterior, superior (midline), and posterior edges of the defect;

however, the inferior edge which was below or at the level of the zygomatic arch was left unexposed. Pericranium was incised to expose the underlying bone at the fixation sites and along the bony edges of the defect to ensure optimal seating of the implant. The fit of the autoclaved implant was verified, and the same was fixed using 2-mm-diameter x 7-mm-long titanium screws. Hemostasis was verified, and

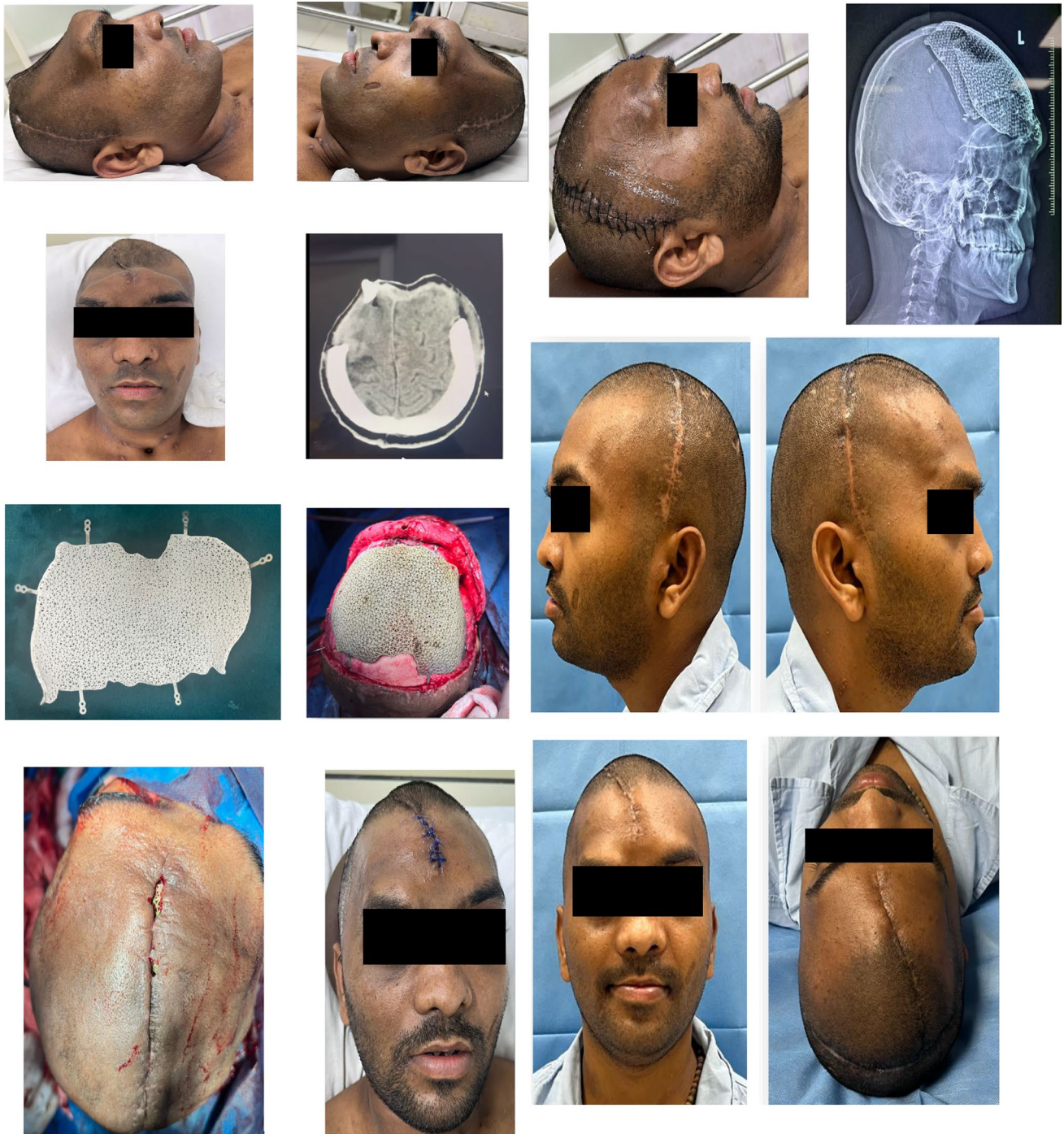

Fig. 1 Reconstruction of large bilateral cranial defect using additively manufactured titanium implant

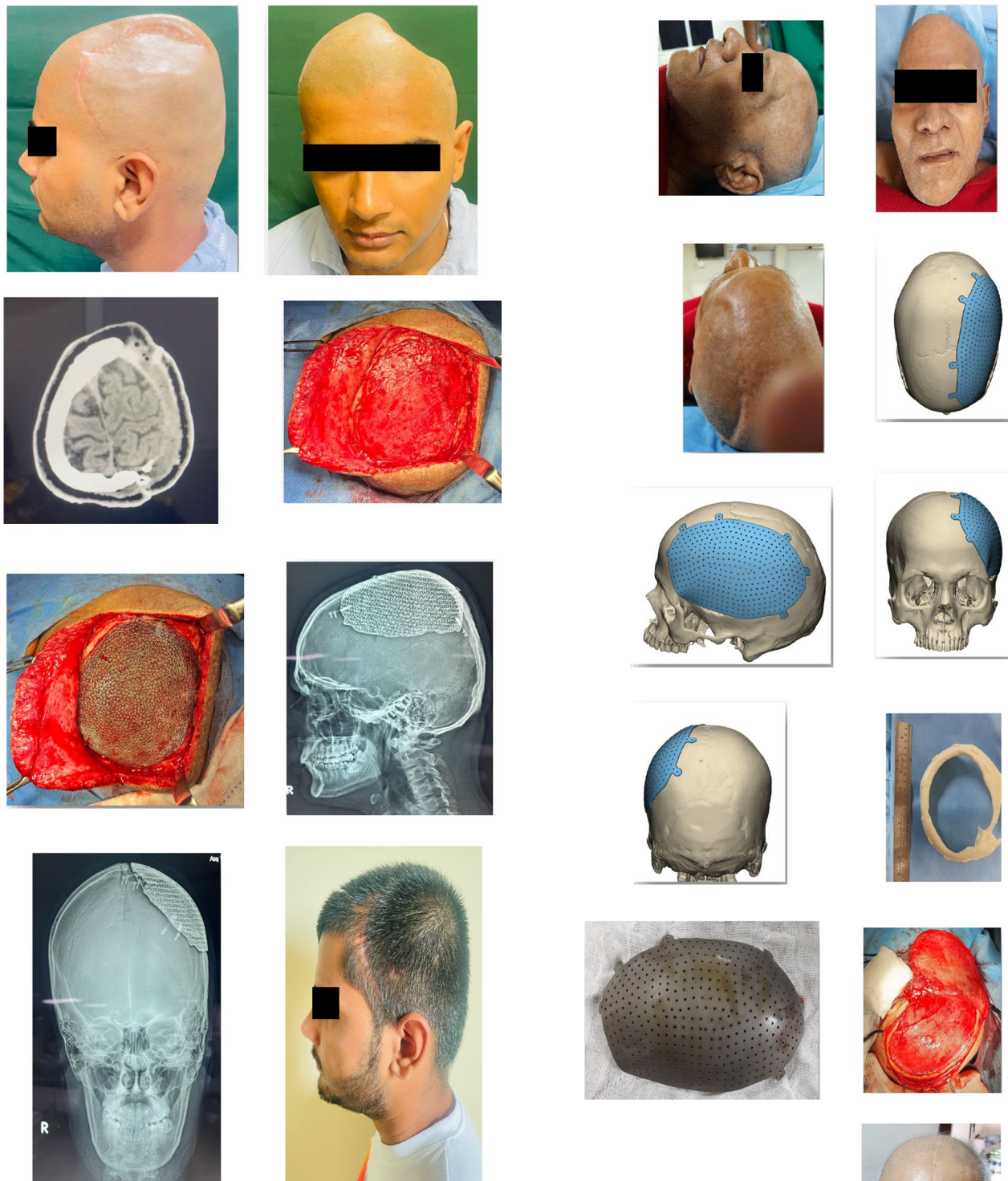


Fig. 2 Reconstruction of large unilateral cranial defect using additively manufactured titanium implant

the scalp flap was replaced after insertion of a suction drain between the implant and the flap, which was partially activated to avoid undue suction on the surrounding structures and was removed on the second postoperative day. The flap

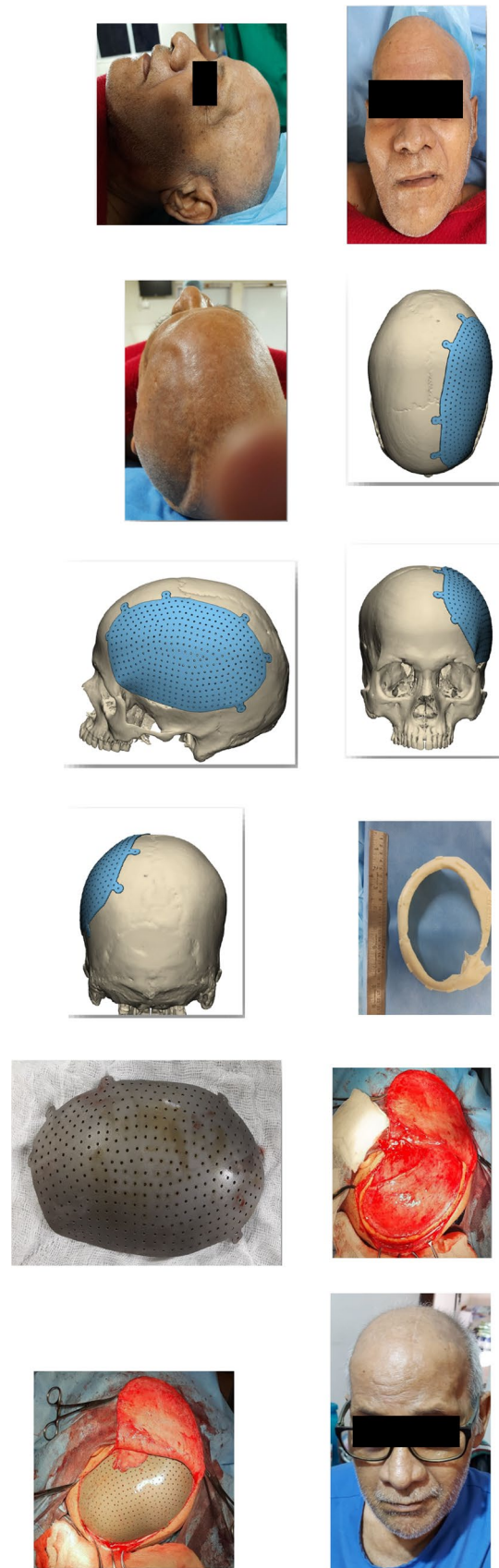


Fig. 3 Designing and steps in the construction and placement of large additively manufactured titanium cranial implant

was replaced using 3–0 resorbable sutures in the deeper layer and stainless-steel staples on the skin. Pressure dressing was applied over the incision line using Elastoplast [Figs. 1,2,3]. Postoperatively, the patient was maintained nil per os for 6 h, and injection paracetamol 1 g iv was used for postoperative pain control along with injection dexamethasone 8 mg, which were replaced by tablet ibuprofen 400mg + paracetamol 500 mg combination after the second postoperative day. The patients were under the same antibiotic cover for 3 to 5 days and were discharged after 5 to 7 days postoperatively. The skin staples were removed after 10 days. All cases were reviewed after a month.

The laboratory protocol for construction of the PSI involved the use of CT data in Digital Imaging and Communication in the Field of Medicine (DICOM) protocol, which was used to construct a 3D model in Standard Tessellation Language (STL) file. This was used to design the implant using mirroring and merging using computer software to obtain a bilaterally symmetrical shape and size. The design thus developed was used in a machine employing electron beam melting (EBM)/selective laser melting (SLM) technology to construct the implant in a cyclic process involving preheating the powdered titanium alloy, which was then scanned and melted to develop a solidified layer. Additional layers were repeatedly added till the desired form was achieved.

Results

A total of four cases were operated for reconstruction of residual deformity of the cranium using additively manufactured titanium PSI with the intention of providing protection to the underlying brain tissue, improve brain physiology, and cosmetics. The cases secondary to RTA were younger in age as compared to the one after a stroke. Relevant patient demographics are as per Table 1. All cases demonstrated a significant improvement in cosmetics [Figs. 1, 2, 3]. The two cases which were operated with GCS 15 showed no change in the GCS postoperatively; however, on review, the patients reported a sense of well-being and improved confidence. The patient who was on GCS 13 preoperatively demonstrated a significant improvement in cognition postoperatively. However, the case which was operated at GCS 8 continues to be at the same level of consciousness and has shown no signs of improvement till date. No postoperative complaints at the surgical site and/or otherwise have been reported so far.

Discussion

A decompressive craniectomy is known to be lifesaving in the event of a refractory intracranial hypertension [8]. This could happen due to a variety of reasons and is broadly

defined as a raised intracranial pressure (ICP) beyond 20 to 22 mm Hg for a sustained period of 10 to 15 min [9]. Traumatic brain injury, vascular pathology, tumors, etc., are the common etiopathological reasons for a raised ICP. Contemporarily, large decompressive craniectomies, that is, the ones involving a complete hemisphere/frontotemporoparietal and the bilateral/bifrontal procedures along with an augmentative duroplasty, are known to produce a clinically acceptable outcome [9]. As a common practice, the osteotomized bone flap is stored in the abdominal wall or anterior thigh, and the patient is observed for a prolonged period prior to a cranioplasty. It is recommended to undertake an early reconstruction of the cranium to mitigate the symptoms of the sinking flap syndrome which is known to clinically present as altered consciousness and cognition levels, speech deficit, psychosomatic disturbances, and seizures. Altered cerebral metabolism, changed pattern of CSF, cerebral blood flow, and atmospheric pressure have been suggested as the possible pathophysiologies of this syndrome [10]. To avoid an additional surgery (cranioplasty) and allay the side effects of trephination, Claudia et al. proposed hinging the bone flap prior to closure of the craniectomy (the Tucci flap). A similar technique known as the “In situ hinge craniectomy” was advocated by Kathryn et al. with reasonable success [11]. Unfortunately, in many cases, the bone flap is unviable to be replaced back during a cranioplasty, thereby giving rise to the need of finding a substitute.

Intriguingly, craniectomy which was earlier designated as trephination finds much more mention in the literature as compared to cranioplasty, and there seem to be large gaps in the recorded history in this regard. After the sixteenth-century gold plate cranioplasty reference, the next one is of a xenograft using a dog bone in a Russian man’s skull in 1680. Cranioplasty gained popularity in the twentieth century, and various techniques have been advocated thereafter. A variety of materials ranging from autogenous bone, xenografts, metals, and nonmetallic substances have been reported for cranial reconstruction. The common ones are cranium, sternum, scapula, fibula, tibia, rib, fat, fascia, canine bone, gold, silver, titanium, aluminum, lead, vitallium, tantalum, titanium, stainless steel, hydroxyapatite, PMMA, and PEEK [2].

In cases where the defect is small and does not require a very specific shape, native bone harvested from the contralateral side of the cranium is a good source of bone [4], which could be used to bridge the residual deformity. However, with this technique the volume of available bone is limited and requires surgical expertise to harvest the graft [12]. Initially reported in the 1940s, PMMA plates used to be the material of choice for a long time, for reconstruction of larger defects, as they are easy to fabricate and are cost-effective [13] (Fig. 6). However, allergic reaction due to the leaching of the monomer from the PMMA, fracture of the plate, and cumbersome retrievability in case of a subsequent

injury were reported as the limiting factors in its use [14]. Sane et al. have reported titanium mesh-reinforced prosthesis to overcome the strength, fragility, and retrievability drawbacks associated with a PMMA prosthesis [15]. Other porous materials like polyethylene, PEEK, and hydroxyapatite have also been reported in cranial reconstruction, but owing to their strength characteristics, these seem to be better suited to be used as onlay grafts for cranial recontouring [16] [Fig. 4]. Titanium mesh, which is available in various sizes, has been reported to be a much better alternative to the PMMA plates as far as the infection rates are concerned. However, the major limitation of these meshes is their inability to be bent into specific shapes, which limits their use to small-/medium-sized defects (Fig. 5). Additionally, there have been reports of skin erosion and implant exposure with the use of these meshes [17] (Fig. 6).

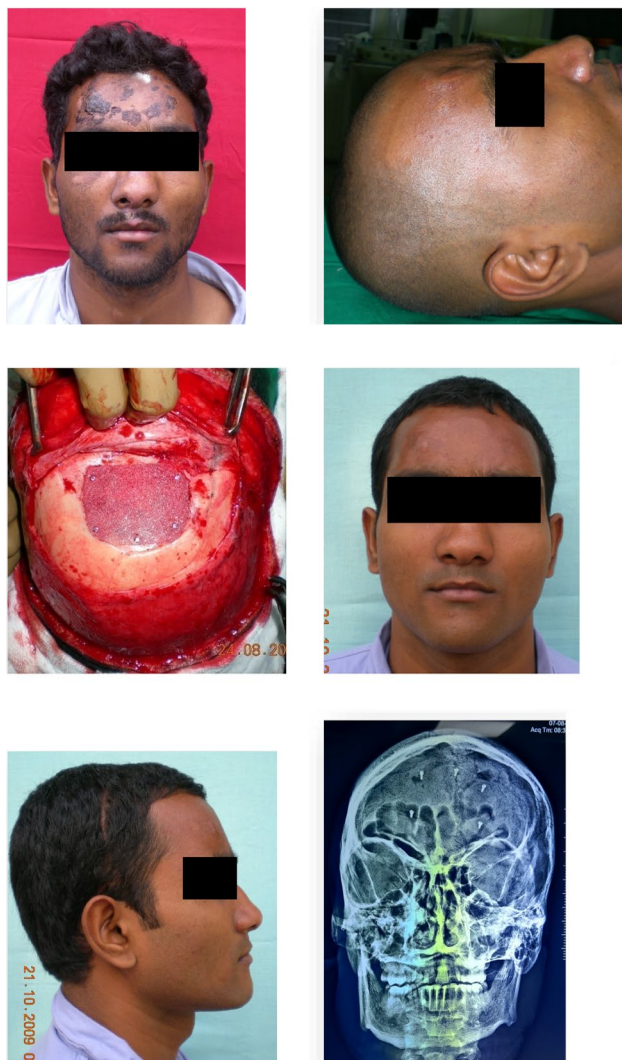

Fig. 4 Use of porous alloplastic material as onlay graft for cranial reconstruction

The reconstruction of a large residual deformity of the cranium is known to be technically challenging and expensive. Some centers advocate the use of a customized helmet to delay or defer a cranioplasty [18]. In our opinion, such practices are of historical value [Fig. 7]. The additive manufacturing technology seems to provide an option for manufacturing cranial implants to cover all kinds of defects. The main advantage of this technology is its capability to deliver customized large implants of a specific shape without compromising the strength, precision, and biocompatibility [19]. Such reconstructions are not viable with conventional bone or polymeric material, as they lack optimal volume and mechanical properties, respectively. Additive manufacturing is a method of building an object in a layer-wise manner and is commonly referred to as 3D printing. The technology dates to the 1980s where it was used to create prototypes which were usually not functional and was known as rapid prototyping. Overtime, it has evolved into an efficient method of manufacturing complex working devices. The process involves developing a design of the object using the computer-aided designing (CAD) technology, which is then used to print the same by the computer-aided manufacturing (CAM), using a 3D printer [20]. In the manufacturing of cranial hard tissue implants, DICOM data from a CT scan are used to generate a design of the implant, which is then used to fabricate the same using the electron beam melting (EBM)/selective laser melting (SLM) of powdered titanium alloy which involves laser-assisted melting of the powdered alloy and solidification in the desired shape [21, 22]. Additive manufacturing technology has been used to create cranial implants with other materials as well, like PEEK, PMMA, and hydroxyapatite [23–25]. However, in our study, titanium was used for

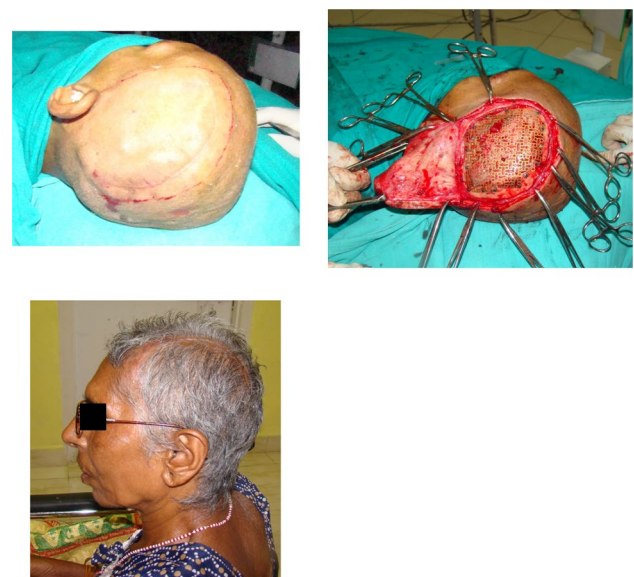

Fig. 5 Use of pre-formed titanium mesh for cranial reconstruction

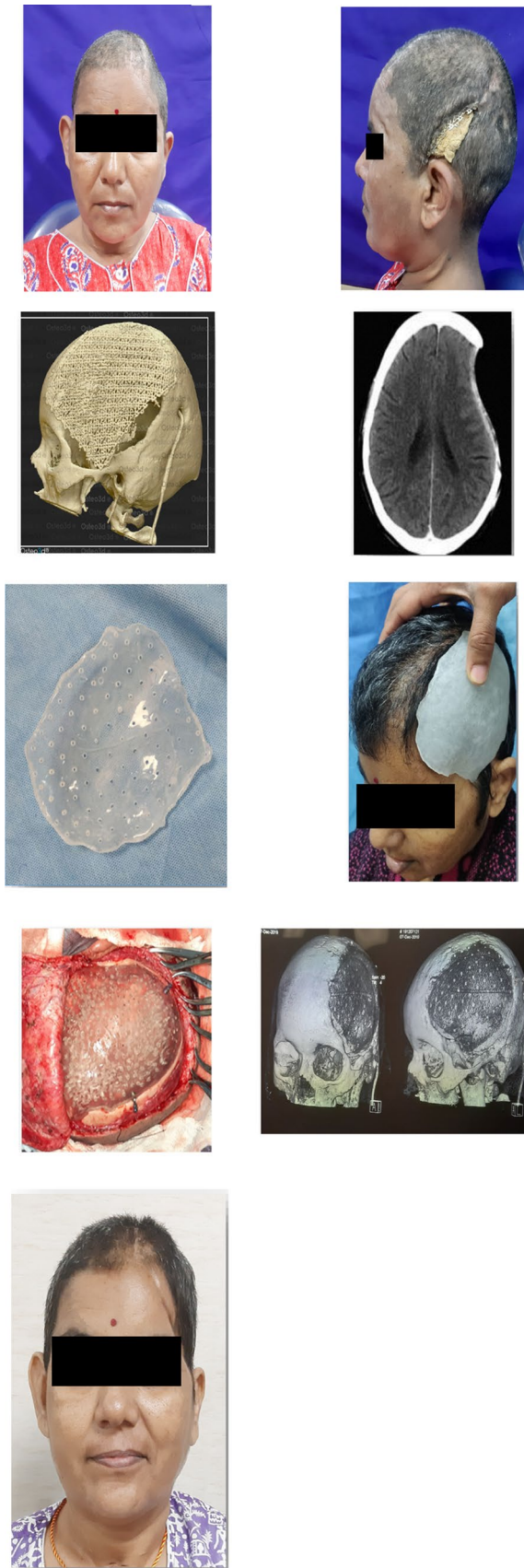


Fig. 6 Percutaneous perforation and exposure of pre-formed titanium mesh used for cranial reconstruction

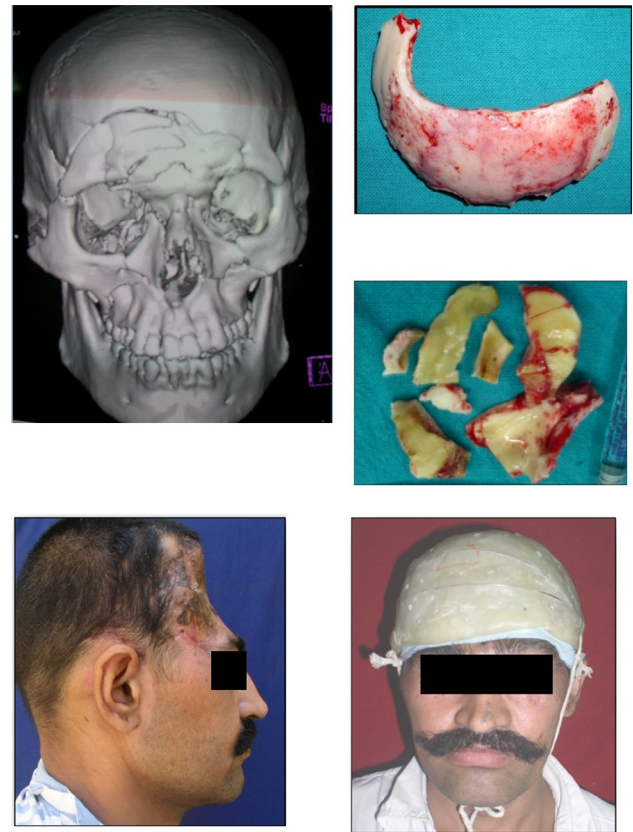


Fig. 7 Use of protective custom-made acrylic helmet after craniectomy

the management of these cases based on its proven superior mechanical and biocompatible properties. Introduced in the 1960s, the medical grade/grade 5 alloy (Ti6Al4V) [26] is the contemporary metal of choice for manufacturing of hard tissue implants because of ease of fabricability, biocompatibility, etc. This quality enables the manufacturing of complex shapes which mirrors the contralateral/uninvolved side, thereby creating an implant which mimics the presurgical dimensions. This property is particularly valuable in creating implants for defects crossing the midline, as these cannot be optimally managed using other kinds of materials. Postmanufacturing these implants are convenient to handle. These can be autoclaved routinely prior to placement on the patient and fixed with commonly available stock titanium screws. In our experience, the ease of placement, precision fit of the implant, and cosmetic outcome were clinically satisfactory. Though postoperative limitations of metal artifacts in case of subsequent diagnostic evaluation and complications such as pain at the surgical site, infection, exposure due to overlying skin erosion, displacement of implant due to failure of fixation, and wound dehiscence have been reported [22], majority of patients in our study reported improvement in general

well-being after the procedure, and no clinically significant complications have been reported so far.

Conclusion

In our experience, the additively manufactured titanium implants for cranioplasty are a viable option for reconstruction of large residual deformity cases, especially the bilateral defects. The advantages outweigh the only perceivable disadvantage of not being economical as on date. With the improvement in this technology, the manufacturing cost is likely to become more affordable in the times to come, and more extensive studies may improve the understanding and utilization of this technology.

Open Access This article is licensed under a Creative Commons Attribution 4.0 International License, which permits use, sharing, adaptation, distribution and reproduction in any medium or format, as long as you give appropriate credit to the original author(s) and the source, provide a link to the Creative Commons licence, and indicate if changes were made. The images or other third party material in this article are included in the article's Creative Commons licence, unless indicated otherwise in a credit line to the material. If material is not included in the article's Creative Commons licence and your intended use is not permitted by statutory regulation or exceeds the permitted use, you will need to obtain permission directly from the copyright holder. To view a copy of this licence, visit <http://creativecommons.org/licenses/by/4.0/>.

References

- Dewan MC, Rattani A, Gupta S, Baticulon RE, Hung YC, Panchak M et al (2019) Estimating the global incidence of traumatic brain injury. *J Neurosurg* 130(4):1080–1097
- Sanan A, Haines SJ (1997) Repairing holes in the head: a history of cranioplasty. *Neurosurgery* 40(3):588–603
- Di Rienzo A, Colasanti R, Gladi M, Pompucci A, Della Costanza M, Paracino R et al (2020) Sinking flap syndrome revisited: the Who, When and Why. *Neurosurg Rev* 43(1):323–335
- Feghali JG, Elowitz EH (1998) Split calvarial graft cranioplasty for the prevention of headache after retrosigmoid resection of acoustic neuromas. *Laryngoscope* 108(10):1450–1452
- Henry J, Amoo M, Taylor J, O'Brien DP (2021) Complications of cranioplasty in relation to material: systematic review. *Netw Meta-Anal Meta-Regres Neurosurg* 89(3):383–394
- Gomi A, Sunaga A, Kamochi H, Oguma H, Sugawara Y (2016) Distraction osteogenesis update: introduction of multidirectional cranial distraction osteogenesis. *J Korean Neurosurg Soc* 59(3):233–241
- Singh R, Davim JP (eds) (2018) Additive manufacturing: applications and innovations, 1st edn. CRC Press. <https://doi.org/10.1201/b22179>
- Monchal T, Hornez E, Prunet B, Beaume S, Marsaa H, Bourgouin S et al (2016) Hospital care in severe trauma: Initial strategies and life-saving surgical procedures. *J Visc Surg* 153(4 Suppl):3–12
- Cooper DJ, Rosenfeld JV, Murray L, Wolfe R, Ponsford J, Davies A et al (2008) Early decompressive craniectomy for patients with severe traumatic brain injury and refractory intracranial hypertension—A pilot randomized trial. *J Crit Care* 23(3):387–393
- Sveikata L, Vasung L, El Rahal A, Bartoli A, Bretzner M, Schaller K et al (2022) Syndrome of the trephined: clinical spectrum, risk factors, and impact of cranioplasty on neurologic recovery in a prospective cohort. *Neurosurg Rev* 45(2):1431–1443
- Layard Horsfall H, Mohan M, Devi BI, Adeleye AO, Shukla DP, Bhat D et al (2020) Hinge/floating craniotomy as an alternative technique for cerebral decompression: a scoping review. *Neurosurg Rev* 43(6):1493–1507
- Frautschi RS, Halasa B, Kwiczen G, Krebs J, Recinos V, Onwuzulike K et al (2019) Reconstruction of secondary calvarial defects with ex situ split calvarial bone grafts: long-term evaluation of outcomes. *Plast Reconstr Surg* 143(1):223–33
- Woolf JI, Walker AE (1945) Cranioplasty: collective review. *Int Abs Surg* 81:1–23
- Leão R de S, Maior JRS, Lemos CA de A, Vasconcelos BC do E, Montes MAJR, Pellizzer EP, et al. (2018) Complications with PMMA compared with other materials used in cranioplasty: a systematic review and meta-analysis. *Braz Oral Res* 32:e31
- Sane VD, Kadam P, Jadhav A, Saddiwal R, Merchant Y (2016) Multidisciplinary approach for reconstruction of cranial defect with polymethyl methacrylate resin reinforced with titanium mesh. *J Indian Prosthodont Soc* 16:294–297
- Punchak M, Chung LK, Lagman C, Bui TT, Lazareff J, Rezzadeh K et al (2017) Outcomes following polyetheretherketone (PEEK) cranioplasty: systematic review and meta-analysis. *J Clin Neurosci* 41:30–35
- Yeap MC, Tu PH, Liu ZH, Hsieh PC, Liu YT, Lee CY et al (2019) Long-term complications of cranioplasty using stored autologous bone graft, three-dimensional polymethyl methacrylate, or titanium mesh after decompressive craniectomy: a single-center experience after 596 procedures. *World Neurosurg* 128:e841–e850
- Chua KSG, Krishnan RR, Yen JM, Plunkett TK, Soh YM, Lim CJ et al (2021) 3D-printed external cranial protection following decompressive craniectomy after brain injury: a pilot feasibility cohort study. *PLoS ONE* 16(10):e0258296–e0258296
- Moiduddin K, Mian SH, Umer U, Alkhalefah H (2019) Fabrication and analysis of a Ti6Al4V Implant for Cranial Restoration. *Appl Sci* 9(12):2513
- Charoo NA, Barakh Ali SF, Mohamed EM, Kuttolamadom MA, Ozkan T, Khan MA et al (2020) Selective laser sintering 3D printing—an overview of the technology and pharmaceutical applications. *Drug Dev Ind Pharm* 46(6):869–877
- Czyżewski W, Jachimczyk J, Hoffman Z, Szymoniuk M, Litak J, Maciejewski M et al (2022) Low-cost cranioplasty—a systematic review of 3D Printing in medicine. *Materials* 15(14):4731
- Roh H, Kim J, Kim JH, Chong K, Yoon WK, Kwon TH, Kim JH (2019) Analysis of complications after cranioplasty with a customized three-dimensional titanium mesh plate. *World Neurosurg* 123:e39–e44. <https://doi.org/10.1016/j.wneu.2018.10.227>. (Epub 2018 Nov 9 PMID: 30415044)
- Honigsmann P, Sharma N, Okolo B, Popp U, Msallem B, Thieringer FM. Patient-specific surgical implants made of 3D printed PEEK: material, technology, and scope of surgical application. *BioMed Res Int*. 2018.
- Schön SN, Skalicky N, Sharma N, Zumofen DW, Thieringer FM. 3D-printer-assisted patient-specific polymethyl methacrylate cranioplasty: a case series of 16 consecutive patients. *World Neurosurg* 2021;148:e356–62.
- Klammert U, Gbureck U, Vorndran E, Rödiger J, Meyer-Marcotty P, Kübler AC. 3D powder printed calciumphosphate implants for reconstruction of cranial and maxillofacial defects. *J Cranio-Maxillofac Surg* 2010;38(8):565–70.

Publisher's Note Springer Nature remains neutral with regard to jurisdictional claims in published maps and institutional affiliations.