

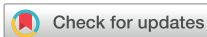Central Lancashire Online Knowledge (CLoK)

Title	Exploring the Landscape of Intracranial Aneurysms in South America: A Comprehensive Narrative Review Intracranial Aneurysms in South America
Type	Article
URL	https://clock.uclan.ac.uk/50515/
DOI	##doi##
Date	2024
Citation	Marsool Marsool, Mohammed Dheyaa, Bharadwaj, Hareesha Rishab, Ali, Syed Hasham, Aderinto, Nicholas, Shah, Muhammad Hamza, Shing, Nathanael, Dalal, Priyal, Huang, Helen, Wellington, Jack et al (2024) Exploring the Landscape of Intracranial Aneurysms in South America: A Comprehensive Narrative Review Intracranial Aneurysms in South America. <i>World Neurosurgery</i> , 185 . pp. 3-25. ISSN 1878-8750
Creators	Marsool Marsool, Mohammed Dheyaa, Bharadwaj, Hareesha Rishab, Ali, Syed Hasham, Aderinto, Nicholas, Shah, Muhammad Hamza, Shing, Nathanael, Dalal, Priyal, Huang, Helen, Wellington, Jack, Chaudri, Talhah, Awuah, Wireko Andrew, Pacheco-Barrios, Niels, Macha-Quillama, Luis, Fernandez-Guzman, Daniel and Hussien Mohamed Ahmed, Khabab Abbasher

It is advisable to refer to the publisher's version if you intend to cite from the work. ##doi##

For information about Research at UCLan please go to <http://www.uclan.ac.uk/research/>

All outputs in CLoK are protected by Intellectual Property Rights law, including Copyright law. Copyright, IPR and Moral Rights for the works on this site are retained by the individual authors and/or other copyright owners. Terms and conditions for use of this material are defined in the <http://clock.uclan.ac.uk/policies/>



Exploring the Landscape of Intracranial Aneurysms in South America: A Comprehensive Narrative Review

Mohammed Dheyaa Marsool Marsool¹, Hareesha Rishab Bharadwaj², Syed Hasham Ali³, Nicholas Aderinto⁴, Muhammad Hamza Shah⁵, Nathanael Shing⁶, Priyal Dalal⁶, Helen Huang⁷, Jack Wellington⁸, Talhah Chaudri⁹, Wireko Andrew Awuah¹⁰, Niels Pacheco-Barrios¹¹, Luis Macha-Quillama¹¹, Daniel Fernandez-Guzman¹², Khabab Abbasher Hussien Mohamed Ahmed¹³

Key words

- Global health
- Health advocacy
- Intracranial aneurysms
- Neurosurgery

Abbreviations and Acronyms

IA: Intracranial aneurysms

MDT: Multidisciplinary team

From the¹Al-Kindy College of Medicine, University of Baghdad, Baghdad, Iraq; ²Faculty of Biology, Medicine and Health, The University of Manchester, Manchester, United Kingdom; ³Faculty of Medicine, Dow Medical College, Dow University of Health Sciences, Karachi, Pakistan; ⁴Internal Medicine Department, LAUTECH Teaching Hospital, Oyo, Nigeria; ⁵School of Medicine, Queen's University Belfast, Belfast, United Kingdom; ⁶School of Medicine, University of Central Lancashire, Preston, United Kingdom; ⁷University of Medicine and Health Science, Royal College of Surgeons in Ireland, Dublin, Ireland; ⁸Department of Neurosurgery, Bradford Teaching Hospital NHS Foundation Trust, Bradford, United Kingdom; ⁹University of Birmingham, Birmingham, United Kingdom; ¹⁰Sumy State University, Sumy, Ukraine; ¹¹Alberto Hurtado Medical School, Cayetano Heredia Peruvian University, Lima, Peru; ¹²Carrera de Medicina Humana, Universidad Científica del Sur, Lima, Peru; ¹³Faculty of Medicine, University of Khartoum, Khartoum, Sudan

To whom correspondence should be addressed:

Hareesha Rishab Bharadwaj, M.B.Ch.B.

[E-mail: hareesha.bharadwaj@student.manchester.ac.uk]

Mohammed Dheyaa Marsool Marsool and Hareesha Rishab Bharadwaj are co-first authors of this study*.

Citation: *World Neurosurg.* (2024) 185:3-25.

<https://doi.org/10.1016/j.wneu.2024.01.108>

Journal homepage: www.journals.elsevier.com/world-neurosurgery

Available online: www.sciencedirect.com

1878-8750/© 2024 The Author(s). Published by Elsevier Inc.

This is an open access article under the CC BY license

(<http://creativecommons.org/licenses/by/4.0/>).

INTRODUCTION

Intracranial aneurysms (IAs) refer to localized abnormal dilatations of weakened arterial walls in the brain.¹ These aberrations arise from a confluence of genetic predispositions and lifestyle-related variables including genetic lineage, hereditary disorders, tobacco

Exploring the landscape of intracranial aneurysms in South America unravels a complex interplay of epidemiological factors, clinical manifestations, and therapeutic challenges. The study methodically conducts a comprehensive literature review spanning the years 2003 to 2023, focusing on English-language articles obtained from diverse databases to elucidate the multifaceted nature of intracranial aneurysms in the region. Results and discussions categorize outcomes into positive domains, emphasizing successful treatments, favorable recoveries, and high survival rates, while also shedding light on negative aspects such as residual aneurysms and complications. The research illuminates significant gaps in pathological typing of intracranial aneurysms and exposes challenges in healthcare accessibility, notably the disparities in neurosurgical resources. Management challenges, including constrained infrastructure access, a neurosurgeon shortage, and gender disparities, are underscored. Transitioning to future prospects, the study advocates for strategic interventions, proposing expanded neurosurgical training, multidisciplinary approaches, improved funding, enhanced access to care, and fostering international collaborations. The study concludes by emphasizing the pivotal role of collaborative efforts, intensified training programs, and global partnerships in propelling intracranial aneurysm management forward in South America, ultimately contributing to enhanced patient outcomes across the region.

consumption, and alcohol intake.^{1,2} Concomitantly, variables such as hypertension, senescence, and hormonal perturbations amplify susceptibility to IA pathogenesis.^{3,4} Globally, unruptured IAs manifest with a prevalence rate approximating 3.2%, with female predominance.⁵

Individuals with IAs often navigate the fifth decade of life, with a sizable proportion, approximately 20%–30%, presenting with poly aneurysmal pathologies.⁶ Latent IAs, though typically asymptomatic, may induce localized pressure phenomena upon significant enlargement and culminate clinical sequelae encompassing cephalalgia, vertigo, visual aberrations, and perturbations in oculomotor nerve functionality.⁷ IAs typically manifest within vessels such as the internal carotid artery, anterior cerebral artery,

middle cerebral artery, and vertebrobasilar artery.⁷ The precise anatomic positioning of these anomalies significantly influences the prognosis and the success of surgical interventions. vertebrobasilar artery-localized aneurysms, for instance, often present more intricate therapeutic challenges and are associated with suboptimal clinical outcomes, as opposed to their anterior cerebral artery counterparts.⁸

The management of IAs involves diagnostic endeavors that deploy a cadre of imaging modalities, ranging from magnetic resonance imaging to digital subtraction angiography.^{3,7} Treatment involves various approaches, from vigilant observation to intricate flow diversion techniques.^{7,9,10} However, within the South American healthcare landscape, constrained accessibility to advanced neurosurgical interventions and

neuroradiological expertise often leads to therapeutic delays for afflicted individuals. In Peru, it is estimated that more than 40% of the country's population does not have access to neurosurgical care within 2 hours.¹¹ Neurosurgery trainees and practitioners in South America further describe barriers that include inadequate access to operative equipment, highlighting the potential disparity in inaccessible material resources for neurosurgical care across the continent.¹² Economic constraints, intensified by disparities in healthcare provisioning, muddle the clinical path for IAs on the continent, while cultural nuances pose additional hurdles.¹³

Consequently, this research serves as a pivotal step toward a holistic understanding of the epidemiology, clinical profile, and therapeutic paradigms of IAs in South America, ensuring that findings are contextualized within the broader global perspective.

METHODOLOGY

This narrative review on the management of IA in South America employed a rigorous methodology involving a comprehensive search of published literature with a focus on studies conducted in South America. The detailed search string provided in the appendix facilitated an extensive and targeted literature search.

The inclusion criteria accommodated studies of various designs, including observational, case-control, cohort, and randomized controlled trials. Studies involving both pediatric and adult populations were eligible for inclusion, as were those addressing all types of IA. The review only considered articles published in English from 2003 to 2023, a time frame chosen to reflect current practices and technological advancements in IA management in South America.

Databases such as PubMed, EMBASE, Google Scholar, the Cochrane Library, EMBASE, CINAHL, SCOPUS and SciELO were enlisted for the literature search. Precise search terms, including "intracranial aneurysm", "brain aneurysm", "cerebral aneurysm", and "subarachnoid haemorrhage", were combined with geographical identifiers such as South American countries' names, "LMICs", "low-middle income countries," and

"South America". This approach ensured that the literature search targeted our specific area of interest. Furthermore, a manual search was conducted to find references for recently published, procedure-specific reviews to further inform regarding the South American IA management landscape. Stand-alone abstracts and unpublished studies were excluded from the review.

Through this comprehensive and methodical approach, the review aims to provide a high-quality academic assessment of the contemporary management of IA in South America, allowing for an in-depth synthesis of pertinent findings. This process offers insights potentially applicable to similar income settings. A summary of the methodology has been presented in **Table 1**. A visual representation illustrating the countries covered in the included studies has been performed in **Figure 1**.

RESULTS AND DISCUSSION

Two categories—positive outcomes and negative outcomes—were created from the data gathered from the aforementioned databases. A comprehensive evaluation of the studies evaluated has been provided in **Table 2**.

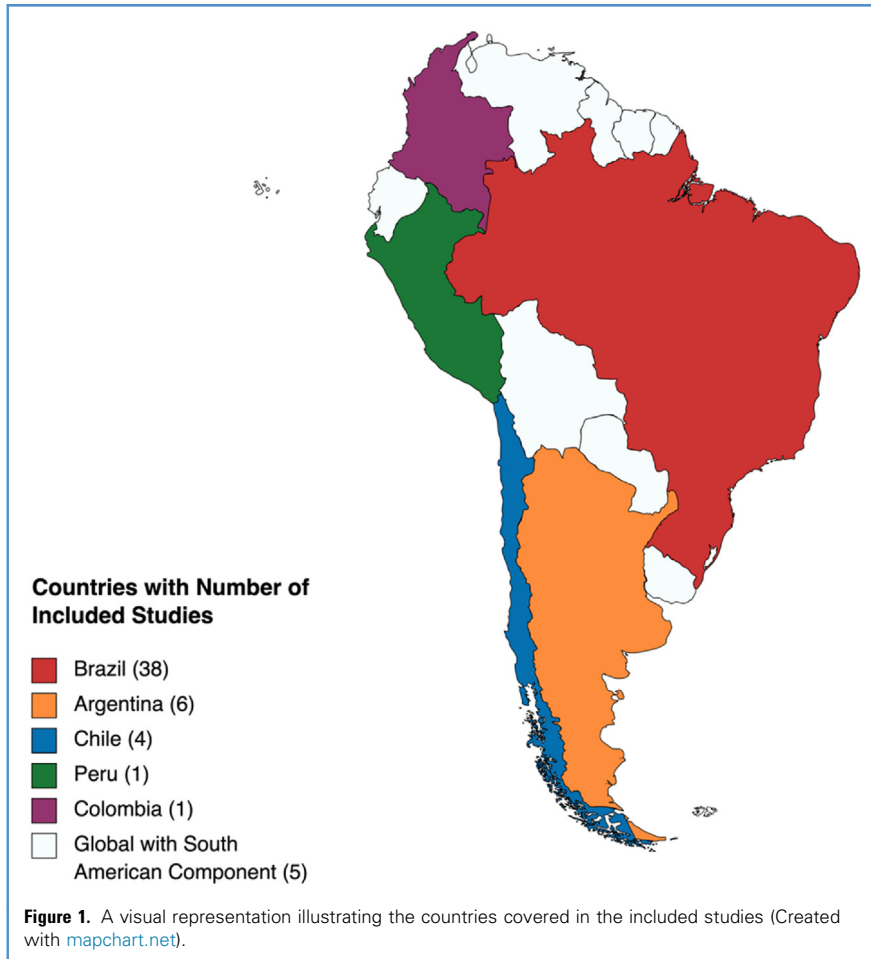
Positive outcomes

Effective aneurysm treatment and occlusion. Treatment outcomes for IA are commonly measured by successful rates of aneurysm occlusion post procedures.² In this review, studies demonstrated good occlusion rates. For example, Trivelato et al.⁴¹ reported an 80.7% occlusion rate at six months, which increased to 89.2% at 1-year postendovascular treatment. Similarly, Vanzin et al.⁴⁴ demonstrated a 76.1% initial occlusion rate, which improved to 77.8% after retreatment. Zenteno et al.⁴⁹ achieved an outstanding 92.9% obliteration rate using stenting and coiling, emphasizing the pivotal role of successful occlusion in preventing complications. Moreover, Martinez-Perez et al.⁵² achieved a remarkable 97% occlusion rate and effectively managed vasospasms in 5 patients over 2.5 years.

Favorable functional recovery. Positive functional outcomes have been highlighted across diverse treatment modalities in several studies. Santos et al.¹⁴ reported a significant number of patients achieving Glasgow Outcome Scale scores exceeding 4 during follow-up and complete recovery of patients with timely intervention for unruptured aneurysms. Patients with small aneurysms achieved Glasgow Outcome Scale scores of 4–5

Table 1. Summary of the Methodology Employed in the Drafting of This Study

Methodology Steps	Description
Literature search	PubMed, EMBASE, Google Scholar, the Cochrane Library, EMBASE, CINAHL, SCOPUS, SciELO (English only)
Inclusion criteria	Full-text articles published in English in the past 20 years (from 2003 to 2023). Various study designs, such as observational, case-control, cohort, cross-sectional, and randomized controlled trials. Studies involving paediatric and adult populations. Studies addressing all types of IA.
Exclusion criteria	Stand-alone abstracts and unpublished studies. Non-English Studies Case Reports
Search terms	Keywords include "intracranial aneurysm", "brain aneurysm", "cerebral aneurysm", and "subarachnoid haemorrhage" They are combined with geographical identifiers such as "LMICs", "low-middle income countries", and "South America".
Additional search	A manual search was conducted to find references for recently published, procedure-specific reviews.
Sample size requirement	Any study with a population of less than 9



after aneurysm clipping.⁵¹ Of note, the study also found the resolution of transient third nerve palsy in a substantial portion of patients within a year post-surgery.⁵¹ In addition, another study demonstrated that endovascular interventions helped patients achieve grade A occlusion according to the Montreal Scale.⁴⁰ This is concurrent with global standards where endovascular treatments, including coiling, consistently produce favorable functional outcomes.^{17,28} Furthermore, Perez et al.⁴⁵ examined patients with carotid cavernous aneurysms and noted improved neurological outcomes with surgical interventions. Patients experienced enhanced pain management and neurological function, highlighting the potential for life preservation and improved quality of life. Taken together, these outcomes underscore the central importance of positive functional

recovery in intracranial aneurysm treatment, regardless of the therapeutic approach.

High survival rates. In this review, several studies demonstrated notably high survival rates. Demartini Jr et al.⁵³ reported a remarkable survival rate exceeding 50% following complete recovery. Additionally, Gonzalez et al.⁶⁹ investigated the long-term outcomes of patients treated with stenting and coiling, revealing a high overall survival rate, and emphasizing the durability of positive treatment outcomes over extended periods.

Negative outcomes

Residual aneurysms, recurrence, and complications. Notably, various studies in this review reported aneurysm recurrence^{44,45,55} and residuals^{19,26} after initial treatment efforts. Further studies reported cases of incomplete surgical

clipping, postsurgical thromboembolic events, and improper device expansion.^{17,48,50} These factors potentially increase hemorrhagic risk in patients due to precipitation of residual aneurysms.¹⁷ In addition, studies have also reported incidents of hydrocephalus and elevated rates of late cerebral.^{44,55} Taken together, these findings underscore the necessity for ongoing monitoring to effectively manage aneurysm residuals, recurrence, and postoperative complications.

Pathological typing of aneurysm. This review has elucidated a dearth of anatomical variation when reporting IA in South American populations, thereby pathophysiological categorization of IA is unclear according to the evidence presented. Only 2 studies have alluded to such typing of IA. A prospective cohort study evaluated 106 individuals with 137 saccular aneurysms and reported various ways of management including aneurysmal clipping (46%), balloon remodeling (38%), stent remodeling (10.9%), and therapeutic occlusion (5.1%).⁴⁶ The study observed an overall 8% mortality rate with a substantial complication rate (12.3%) due to technical (6.6%) and clinical (5.7%) etiologies, with a recurrence rate of 8.2%.⁴⁶ Furthermore, 94.6% of the studied population reported clinical independence on follow-up,⁴⁶ potentially contributing to the higher complication rate. Another study analyzed balloon-assisted remodeling and stent deployment in 174 initial saccular aneurysm cases and reported that 23.6% of these cases had worsening recanalization post-operatively.⁶² Importantly, no studies deliberated fusiform aneurysms or mycotic “infective” pseudoaneurysms, where discrimination between true and false aneurysms may impede study control. Hence, a lack of evidence surrounding the management of true versus false aneurysms forms a surgical “grey area” in IA risk formulation, operative technique, and postoperative care in low- and middle-income countries and South America. Further delineation and categorization of aneurysm pathological type would be beneficial to avoid biases and compounding variables within the review data.

MANAGEMENT CHALLENGES AND GAPS

Access to specialized healthcare infrastructure and equipment

Several South American nations have emerged at the forefront in initiating specialized surgical centers specifically focused on the comprehensive management of IAs.^{66,70} Brazil and Ecuador, in particular, have distinguished themselves with the establishment and growth of such centres.^{71,72}

A parallel trend can be observed in Argentina, Uruguay, and Colombia. These nations have not only embraced the establishment of dedicated centers, but have also channeled efforts into systematic investigations examining patient outcomes, identifying potential gaps in care, and proposing efficacious solutions.⁷³⁻⁷⁵ These developments not only affirm the robust presence of establishments tailored for IA surgical management across South American territories but also accentuate the expansive growth of such facilities within the regional healthcare landscape. This surge can be partly attributed to the strategic establishment of specialized neurosurgical skills laboratories and centers.

However, juxtaposed against these advancements is the challenge of ensuring equitable accessibility to specialized healthcare infrastructure for IA across the South American terrain. The infrastructure, which encompasses hospitals, specialized units, and allied facilities, remains indispensable for ensuring optimal service delivery [Table 1]. Yet, inherent geographical disparities persist across the continent. Urban centers, characterized by their robust infrastructural resources, stand in stark contrast to rural areas that may be bereft of such amenities. Inhabitants of these less-served regions often grapple with logistical hurdles such as extended travel times, limiting their timely access to specialized care. For example, it is estimated that 40% of Peruvians do not have access to neurological services.⁷⁶ Moreover, ensuring that treatment centers for IAs are consistently equipped with the latest technologies remains an ongoing challenge. A disproportionate concentration of advanced neurovascular equipment is discernible within urban locales, leaving peripheral medical facilities potentially under-resourced.

Availability of neurosurgeons

For optimal management of IA, the immediate intervention of neurosurgeons is paramount. Recent studies highlight barriers to this requisite care including a lack of cutting-edge neurosurgical equipment, the absence of a standardized and comprehensive training framework, a dearth of research opportunities, and dauntingly extended working hours for neurosurgeons.¹²

The current status of neurosurgeon availability and the advent of new surgical approaches

The proficiency and skill set of personnel in neurosurgery and neuroradiology play a pivotal role in ensuring favorable outcomes for IA patients, especially within the South American region. The past few decades have witnessed a commendable escalation in the number of neurosurgeons operating within this area.^{12,77} This influx of professionals has catalyzed the advancement and expansion of new surgical interventions for IA. While the traditional method of open surgery, predominantly clipping, remains prevalent for IA treatment, sophisticated surgical methodologies including endovascular treatments are increasingly employed. These ground-breaking initiatives are instrumental in broadening the spectrum of treatment modalities accessible to IA patients.

Despite an increase in workforce, many countries in South America still grapple with a deficit of trained neurosurgical experts. According to the Latin American Federation of Neurological Societies (FLANC), >9 member countries, many of which are in South America, have <1 neurosurgeon/100,000 inhabitants compared to high-income countries like the United States with 1.52 neurosurgeons/100,000 inhabitants.⁷⁷ Consequently, the lag between detection of IAs and treatment initiation may be considerably extended, especially when juxtaposed with Western nations.⁷⁷ Furthermore, neurosurgeons in South America still heavily rely on open surgery, reflecting discrepancies in the availability and distribution of endovascular services. Alarming, this surgical paradigm has associations with heightened morbidity and mortality rates under certain conditions.⁷

Gaps in training, postoperative rehabilitation, and the gender disparity dilemma

There is a salient impediment thwarting the seamless execution of IA programs in South America. This void, accentuated by the lack of ample fellowship opportunities in the region, compromises many neurosurgeons' capabilities to uphold their surgical proficiency and dispense pivotal IA interventions. Such challenges detrimentally affect the overall healthcare delivery paradigm.⁷² The landscape of neurosurgical expertise allocation across the region is also far from uniform. While countries such as Brazil boast a robust contingent of adept neurosurgical practitioners, other territories are wrestling with a palpable dearth of such skilled resources.^{12,72}

Moreover, even as postoperative rehabilitation emerges as a linchpin in bolstering patient recovery and life quality, there's a staggering absence of research exploring this facet, especially within the South American purview. An underlying concern remains regarding the potential lack or embryonic state of postoperative rehabilitation facilities, accentuated by their skewed distribution. Central American nations, most notably, are confronting severe challenges related to neurosurgical care.⁷⁸ Such geographic disparities in the provision of neurosurgical expertise invariably result in inequitable healthcare access across the entire spectrum. This landscape is further marred by a conspicuous gender gap in neurosurgical training establishments, underscoring the pressing need for rectification.⁷⁷

GAPS IN NEUROSURGERY RESEARCH AND INFRASTRUCTURE IN SOUTH AMERICA

Multiple factors have culminated in the region's limited contribution to global research. Local physicians have been vocal about a myriad of challenges that stifle their efforts, including a lack of innovative technology and treatment.¹² One of the most potent barriers is the dearth of a robust research infrastructure. There are limited financial catalysts available for pioneering research, and it has been reported that typical grants in Latin America are significantly lower than in

many developed and emerging countries.⁷⁹ Furthermore, the distribution of funding in most Latin American countries lacks structure and varies significantly, influenced by inadequate budgets and political alliances.⁷⁹ Consequently, the motivation and capacity for healthcare professionals, including neurosurgeons, to spearhead research initiatives are invariably stifled.⁸⁰

There are also substantive impediments that lead to diminished research output in many Latin American countries.⁸¹ One constraint involves restricted access to avant-garde technological platforms. These include flow diverters, intrasaccular apparatuses, and ancillary equipment pivotal to aneurysm coiling, including advanced stents, balloons, and retrievable neck-bridging devices. This technological dearth hinders the initiation of comprehensive trials to elucidate these modalities and subsequently refine treatment paradigms.⁸²

Furthermore, a discernible deficit in specialized imaging techniques, encompassing computed tomography angiography, magnetic resonance angiography, and digital subtraction angiography, curtails profound explorations into the morphological attributes of aneurysms, their dimensions, positioning, and affiliated vasculature. Not only are these modalities indispensable for therapeutic interventions, but they also play a quintessential role in noninterventional management approaches such as vigilant surveillance and periodic assessments. Without these imaging techniques, it becomes inherently challenging to discern aneurysm progression and ascertain the judicious therapeutic window. Moreover, the dearth of telemedicine frameworks renders postoperative assessments cumbersome, attenuating the scope of reporting long-term therapeutic consequences.⁸²

A concomitant issue plaguing the research horizon is the paucity of adept research personnel.⁸¹ The pedagogy of research methodologies and intricate statistical analyses remains underemphasized. Furthermore, the fiscal architecture does not seem conducive to invigorating research endeavors, with minimal allocations from institutional, governmental, or philanthropic entities.⁸³ Predominantly,

the clinical paradigms overshadow research pursuits. Notably, while certain neurosurgical curricula in geographies such as the United States mandate a dedicated research timeline, such requisites seem sporadic in the South American context. A poignant reflection of this is evident wherein a mere 45% of neurosurgical initiatives in South America necessitate research publications by their trainees.⁸⁴ The academic ecosystem, unfortunately, does not appear to resonate sufficiently with research accolades, further dwindling the propensity toward academic investigations.⁸⁵

The healthcare fiscal landscape of South/Latin America is also characterized by modest expenditures where a fragmented, predominantly privatized system, often operates in the absence of robust governmental oversight. These structural inequities, combined with the limited governmental footprint in healthcare provision, have given rise to multifaceted bioethical challenges.⁸⁶ While initiatives such as neurosurgical missions, exemplified in Peru, have aimed to bridge these gaps, the journey is far from completion. For sustainable progress, there's an imperative need for crafting long-term alliances, integrating state-of-the-art remote technologies for uninterrupted training and communication, and fostering collaborative endeavors to reach the most underserved territories.⁷⁶

STRATEGIC INTERVENTIONS AND FUTURE PROSPECTS

Training more neurosurgeons and neurosurgical multidisciplinary team staff

Enhancing the management and treatment of IAs in South America is critically intertwined with the scaling up of training for neurosurgeons and other members of the multidisciplinary team (MDT). Historically, a dearth of skilled professionals has limited the quality and accessibility of care for patients with IAs. To address this, there should be an expansion of specialized educational programs in medical institutions throughout South America. The introduction of rigorous neurosurgical curricula, bolstered by hands-on training sessions, advanced simulations, and real-life surgical exposures, is imperative.

Furthermore, enriching these courses with global best practices, possibly through partnerships with leading neurosurgical institutions worldwide, can ensure that trainees receive a world-class education.

Beyond neurosurgeons, the broader MDT staff, encompassing nurses, radiologists, rehabilitation therapists, and anesthesiologists, among others, play an indispensable role in the comprehensive care of IA patients. Tailored programs designed for each of these roles can significantly elevate the level of care. For instance, specialized training for radiologists in recognizing and accurately diagnosing IAs can lead to earlier and more precise interventions, while therapists trained in postoperative care can significantly improve patient recovery trajectories.

Moreover, the role of continuous professional development cannot be understated. Medicine is an ever-evolving field, and as research progresses and new techniques emerge, even the most seasoned professionals must regularly update their skills. Setting up continuous education modules, workshops, and international exchange programs can ensure that South American neurosurgeons and MDT staff remain at the forefront of IA management. Importantly, the healthcare sector must recognize and address potential barriers to entering these specialized fields. From the financial constraints that prospective students may face to the lack of advanced training equipment in some institutions, these challenges, when tackled, can unlock a larger pool of talent.

Finally, fostering a culture of collaborative research and interdisciplinary integration within South America can further drive scientific innovation for more effective treatments. When neurosurgeons, radiologists, therapists, and other MDT staff come together, pooling their expertise, the resultant holistic approach can lead to significantly improved patient outcomes. By investing in training and continuous learning, South America cannot only enhance the quality of care for IA patients but also set a benchmark for other regions to emulate.

MDT approach and patient involvement

In addressing IAs, the MDT approach is pivotal. By uniting the expertise of neurologists, neurosurgeons,

neuroradiologists, and other healthcare specialists, we can ensure a comprehensive outlook on patient care. This perspective not only focuses on the physiological manifestations of IAs but also delves deep into the psychosocial nuances of each patient. Such a well-rounded approach guarantees a tailored, patient-centric care plan, improving the quality of patient experiences significantly.⁸⁷ In parallel with this approach, there's a growing emphasis on active patient engagement. The more involved a patient is in their treatment decisions, the better the outcomes. Embracing shared decision-making, a collaborative effort between the medical team and the patient has been shown to result in care plans that align closely with patient needs and values.⁸⁸ Empowering patients with knowledge about their condition and treatment options ensures they can make informed choices and be active participants in their healthcare journey.

Consequently, enhancing this MDT approach necessitates several interventions. Regularly scheduled MDT discussions, telemedicine to bridge geographical divides,⁸⁹ and collaborative training sessions all serve to bolster the efficiency and reach of this methodology. Furthermore, platforms allowing patients to share feedback will keep their perspectives central to evolving care strategies. Looking to the future, the growing prominence of the MDT approach suggests the emergence of standardized protocols. Innovations like artificial intelligence will play a role in refining these strategies, potentially leading to a stronger emphasis on preventative care for IAs. As the global medical community grapples with the challenges of IAs, international collaborations will be invaluable, catalyzing the exchange of research and innovative practices.

Improving funding and access to care

Tackling IAs effectively hinges on substantial financial backing, especially in resource-constrained environments. From diagnostics to postoperative care, every stage feels the pinch of inadequate funding. However, with equitable investment, we can usher in a healthcare renaissance, enabling the introduction of advanced technologies and bolstering research.⁹⁰

To counteract these financial constraints, diversification is the key.⁹¹ By allocating specific budgets for IA management and forging collaborations with international stakeholders, governments can bridge funding gaps. Exploring innovative channels, such as health bonds and public-private partnerships, can consolidate resources for neurovascular care. Moreover, transitioning to value-based healthcare models ensures funds directly enhance patient health, prioritizing results over service numbers. Furthermore, the urban-rural divide further complicates IA care access. Telemedicine offers a promising solution, connecting remote patients with urban specialists.⁸⁹ Additionally, mobile health clinics can be instrumental in reaching underserved areas, ensuring early and efficient IA detection and care. For a more holistic approach, we must also refine referral systems and champion patient education. By equipping primary healthcare units with the skills to detect early-stage IAs and facilitating swift referrals, we can optimize patient outcomes. Public awareness campaigns about IAs can drive early detection, minimizing complications and costs.

With these integrated strategies in place, a landscape where every individual, irrespective of their location or socioeconomic status, has equal access to IA care is within reach. As technology evolves, South America could position itself at the forefront of IA research and innovation, shaping global practices.

Fostering International Collaborations

Leveraging international partnerships can significantly enhance the management of IAs in South America. These collaborations bridge knowledge gaps and foster an exchange of innovations. Partnering with top institutions from developed nations grants South American professionals world-class training and insights, while also providing a unique perspective.¹² Beyond just training, the region has the chance to adopt state-of-the-art diagnostic and surgical tools.⁹² Events like international symposiums facilitate this exchange, allowing South American experts to engage with and contribute to global advancements.

In addition, joint clinical trials present opportunities for South America to be part

of pioneering treatments and contribute to international patient data for IAs.⁹³ Engaging with global entities can standardize regional protocols, aligning with advanced global practices. Such interactions not only advance technical aspects but also enrich cultural understanding. This holistic approach ensures more tailored patient care, resonating with diverse cultural contexts. Finally, sharing healthcare policies and best practices through these partnerships can further strengthen South America's medical landscape.

LIMITATIONS

Despite the implementation of a rigorous methodology, this review has several limitations. First, a reliance on existing literature and data sources with potential variability in data availability and reliability may introduce elements of bias or incomplete information. Second, the temporal scope of this study, encompassing the years 2003 to 2023, enables a contemporary perspective but may not capture the most recent developments in IA management. In addition, the study primarily draws from English-language publications, potentially neglecting significant research conducted in languages other than English. Moreover, the rich diversity of South America's healthcare infrastructure and practices, influenced by geographic and regional disparities, is challenging to encapsulate comprehensively in a single study. Therefore, while this article strives to illuminate the challenges and opportunities in IA management across South America, these limitations necessitate cautious interpretation and underline the imperative for context-specific, nuanced investigations tailored to individual countries and regions within this dynamic continent.

CONCLUSIONS

In conclusion, this study provided a comprehensive review of the contemporary management of IAs in South America, highlighting the use of various treatment modalities and reporting positive and negative outcomes in the region. Importantly, challenges surrounding a lack of access to specialized healthcare infrastructure, deficits in neurosurgical experts

Table 2. Comprehensive Summary of Management Procedures and Outcomes of Intracranial Aneurysms Across Different South American Countries

Author/Year/ Country	Study Type	Relevant Presentation	Diagnostic Method	Management Procedure(s)	Salient Outcomes	
					Positive Outcomes	Negative Outcomes
Santos et al. 2015 – Brazil ¹⁴	Retrospective	21 patients with ACoA Aneurysms	Cerebral angiography	-Undefined aneurysmal repair but with instances of temporary clipping and arterial occlusion	-66.6% of patients had a GOS greater than or equal to 4 on follow-up -Patients with unruptured aneurysms had full recovery on follow-up	-66.6% of patients developed vasospasm -52% of patients developed hydrocephalus -In patients with ruptured aneurysms, only 41.6% had a favourable outcome -2 patients are reported deceased postoperatively
Henrique et al. 2021 – Brazil ¹⁵	Prospective, open, single-arm pilot safety trial	21 patients with distal unruptured IAs	DSA	-Prasugrel 5/10 mg started 7 days before treatment -Heparinisation initiated under GA -A p48 MW HPC flow diverter was delivered via catheter to the aneurysm -Adjunctive coiling or balloon remodelling done if considered appropriate by MDT	-Absence of any neurologic symptoms in all patients at 1 month follow-up -Complete aneurysm occlusion achieved in 33.3% of cases on 30-day follow-up -The logistic regression analysis showed that only adjunctive coiling was a predictor for complete occlusion of the aneurysm at the 1-month follow-up (OR 13.6, 95%CI 1.22 to 151.0, P= 0.034) -Performing coiling in addition to flow diverter implantation increased the chance of complete aneurysm occlusion by 13.6 times after 1 month -Achieved a mean mRS of 0 postoperative with pretreatment and post-treatment mRS unchanged for all patients. No mortality reported	-20% of the cohort had asymptomatic ischemic lesions on a 48-hour postoperative MRI -Flow diverter migration in 7.4% of aneurysms on 30-day follow-up
De M et al. 2011 – Argentina ¹⁶	Retrospective	Patients with dissecting IAs	MRI DSA	-75 mg clopidogrel and 100 mg aspirin 72 hours preoperatively -IV heparin intraoperatively -PED deployed after coil embolization of aneurysm -Dual antiplatelet medication continued 6 months postoperatively with heparinization unreversed	-GOS 4 and 5 were achieved in 74% of patients -46/51 devices successfully deployed, achieving 90% technical success -No aneurysmal rupture following PED deployment	-2 patients died following late SAH complications -Intraoperative technical difficulties occurred; 1 device fell into the aneurysmal sac, 2 slipped proximally during deployment, and 2 presented shortening which required a new device

ACoA, anterior communicating artery; CI, confidence interval; DCI, delayed cerebral ischemia; EVD, external ventricular drainage; FRED, flow redirection endoluminal device; GA, general anesthesia; ICA, internal carotid artery; VPS, ventriculoperitoneal shunt; MSE, Mental State Examination; MIS, minimally invasive surgery; mRROC, modified Raymond Roy Occlusion Class; mRS, modified Rankin scale; IAs, intracranial aneurysms; CT, computed tomography; SAH, subarachnoid haemorrhage; PED, pipeline embolization device; SS, Surpass Streamline; IV, intravenous; TBO, temporary balloon occlusion; SPECT, single photon emitting computed tomography; ICU, intensive care unit; MDT, multidisciplinary team; ml, millilitre; OR, odds ratio.

*Data are largely expressed as a percentage of the patient population to facilitate easier visualization by the reader, except where the study a) has a small patient population or b) has expressed data without providing percentages.

†Follow-up statistics are expressed as a percentage of the total population which were available for follow-up.

Continues

Table 2. Continued

Author/Year/ Country	Study Type	Relevant Presentation	Diagnostic Method	Management Procedure(s)	Salient Outcomes	
					Positive Outcomes	Negative Outcomes
Dellaretti et al. 2017 – Brazil ¹⁷	Retrospective	Patients with IAs	DSA Rotational angiography	Microsurgical clipping	The majority of patients had no residual aneurysms	-Surgical clipping incomplete in 13.3% of aneurysms
Do Souto et al. 2006 – Brazil ¹⁸	Retrospective	Patients with complex paraclinical and giant cavernous IAs	TBO – SPECT for evaluation of collateral carotid circulation and cerebral blood flow	-Balloon catheters were introduced via the femoral artery, with subsequent catheterisation of the carotid artery under fluoroscopy -Definitive treatment decided on by MDT after discussion -Eleven patients underwent therapeutic carotid occlusion 1) 8 underwent surgical trapping 3) 3 underwent endovascular balloon occlusion	-12/15 patients had good clinical outcomes without any deficits	-3 complications – 1 case of permanent motor deficit due to unintended occlusion of perforator branches, 1 developed hemiparesis on the fourth postoperative day which improved, and 1 developed transient hemiparesis secondary to saphenous vein bypass thrombosis -One patient died postoperatively due to sepsis
Echeverria et al. 2022 – Chile ¹⁹	Prospective	Patients with IAs	-Clinical assessment -MR angiography	-Embolization via novel shape memory polymer coil with or without stents as appropriate -One patient (PX) with the largest aneurysm was treated with a flow diverter further	-No adverse events during the first thirty days	-PX reported hemiparesis, with episodes of hemiplegia, at 12-month follow-up due to antiplatelet therapy noncompliance. The patient recovered after therapy
Estevao et al. 2017 – Brazil ²⁰	Retrospective	Patients with MCA aneurysms	-CT scan -Angiogram	-Microsurgical clipping	-69.6% of cases had no postoperative complications (mRS 0) -6.5% had no significant disability (mRS 1)	-13%, 4.30%, and 6.5% of patients developed a slight disability, severe disability, and death, respectively
Figueiredo et al. 2016 – Brazil ²¹	Prospective	Patients with anterior circulation aneurysms	-Angiogram	-Ministerial craniotomy -Clipping	-67 patients (the vast majority) had an mRS of 0 or 1	-12 deaths reported -7 patients had an mRS of 2 -Intraoperative bleeding in 05/102 aneurysm removal procedure, intracranial haemorrhage in 3, CSF leak in 1, clinical vasospasm in 34, radiological vasospasm in 16, postoperative hydrocephalus in 06, and infection in 03 -One reoperation is required for clip repositioning

Lylyk et al. 2005 – Argentina ²²	Prospective	50 patients with IAs	-DSA -3D angiography -Clinical assessment	-Antiplatelet administration -GA or sedation done as appropriate -Catheterisation with Neuroform self-expanding stent placement -One of 3 strategies followed: 1) stent alone, 2) stent with coiling thereafter, or 3) coiling with stenting after that -Endovascular reconstruction -Transfer to ICU and monitoring via Doppler ultrasonography -Dual antiplatelet regimen 30 days postoperatively followed by aspirin for life	-Overall the vast majority of the cohort survived	-One case of premature stent delivery, 1 of gastric bleeding due to antiplatelet therapy, and 2 patients had incision site complications -6 thromboembolic events with resolution following abciximab administration -1 patient had a left temporal stroke resulting in hemiplegia and aphasia -1 case of dissection of cervical ICA, resulting in a minor stroke with anticoagulation therapy resulting in eventual resolution -One procedural death due to intracranial haematoma secondary to arterial rupture caused by wire manipulation -8.6% and 2.1% overall morbidity and mortality rate
Lopes et al. 2018 Global with an Argentinian component ²³	Multicentre, single-arm, retrospective	Patients with posterior circulation aneurysms	-Undisclosed	-PED implantation	-84 patients recovered well	-7/91 deaths at different times postoperative for multiple reasons including infarcts, pneumonia, aneurysm rupture, and PED thrombosis
Foa Torres et al. 2018 – Argentina ²⁴	Retrospective	Patients with complex IAs	-Clinical assessment -Angiography	-Dual antiplatelet pretreatment -Silk flow diverter stent deployed, with coiling if deemed necessary by MDT -3 cases needed additional balloon angioplasty, 3 others needed additional chemical thrombolysis -Transfer to neurosurgical ICU for monitoring	-At 12-month follow-up, there was complete occlusion in 93.9% of aneurysms and partial occlusion in 6.1% of aneurysms -In the subgroup of aneurysms of the posterior territory, mortality was 1.4%, and morbidity 1.1% with a complete occlusion rate of 100%	-Postoperative angiography showed total occlusion in 1.4% of aneurysms and subtotal occlusion in 96.2% of aneurysms -4.2% and 2.1% morbidity and mortality rates, respectively, at 1-year follow-up -Technical complications occurred in 4.1% of procedures (poor stent opening, stent migration, shortening, and so on)

ACoA, anterior communicating artery; CI, confidence interval; DCI, delayed cerebral ischemia; EVD, external ventricular drainage; FRED, flow redirection endoluminal device; GA, general anesthesia; ICA, internal carotid artery; VPS, ventriculoperitoneal shunt; MSE, Mental State Examination; MIS, minimally invasive surgery; mRROC, modified Raymond Roy Occlusion Class; mRS, modified Rankin scale; IAs, intracranial aneurysms; CT, computed tomography; SAH, subarachnoid haemorrhage; PED, pipeline embolization device; SS, Surpass Streamline; IV, intravenous; TBO, temporary balloon occlusion; SPECT, single photon emitting computed tomography; ICU, intensive care unit; MDT, multidisciplinary team; ml, millilitre; OR, odds ratio.

*Data are largely expressed as a percentage of the patient population to facilitate easier visualization by the reader, except where the study a) has a small patient population or b) has expressed data without providing percentages.

†Follow-up statistics are expressed as a percentage of the total population which were available for follow-up.

Continues

Table 2. Continued

Author/Year/ Country	Study Type	Relevant Presentation	Diagnostic Method	Management Procedure(s)	Salient Outcomes	
					Positive Outcomes	Negative Outcomes
Fonseca et al. 2021 – Brazil ²⁵	Retrospective comparative	Patients with anterior circulation aneurysms	-Angiography -Angiotomography	Two groups of patients undergoing 2 procedures: 1) Minimally invasive supraorbital craniotomy (SOMC) – 50 patients 2) Pterional craniotomy (PC) – 35 patients	-Patients undergoing SOMC had significantly shorter postoperative ICU stays than PC group -No significant difference in mortality, postoperative complications, or outcome in the 2 approaches	-Though not significant, the PC approach resulted in more complications -Aesthetically, SOMC resulted in better results as measured by visual analog scale -9 deaths overall, with 6 in the PC group
Fujimoto et al. 2020 – Chile ²⁶	Retrospective	Patients with wide- neck bifurcation aneurysms	-Angiography -Radiography	-Antiplatelet pretreatment and post- treatment therapy, heparinisation -Deployment of the Woven EndoBridge self-expanding flow-disrupter	TECHNICAL:-Technical success in 95% of cases No intraoperative rupture FOLLOW UP:-Complete occlusion seen in 71.4% and 62.5% of patients on initial and short-term follow-up –62.5% complete occlusion rate on long-term follow-up -No mortality	TECHNICAL:-Technical failures occurred due to inappropriate device size, later resolved by implanting a new device -Additional stent placement was required in 2 cases because of device protruded into the parent artery FOLLOW-UP: -Residual aneurysm rate ranging from 16.8%–25% on short to long-term follow-up –2.4% overall morbidity
Giacomini et al. 2015 – Brazil ²⁷	Retrospective	Patients with IAs	DSA MR Angiography	-Dual antiplatelet regimen -Silk or PED used as appropriate, in some cases with coiling	-Immediate angiography revealed contrast stasis in 94% of aneurysms -Complete occlusion in 84% of all aneurysms -In those who presented with cranial nerve compression (18), relief was seen in most (10)	-Overall morbidity of 10.4% and mortality of 3.9% -mRS statistics show a poorer outlook as follow-up time increases
Lylyk et al. 2021 Argentina ²⁸	Retrospective	Patients with IAs	Rotational angiogram	-Dual antiplatelet therapy -PED devices implanted and/or coiling if aneurysm giant or partially thrombosed	-Complete occlusion in 75.8% of aneurysms -Rate of complete occlusion on follow-up increased on each follow-up check (12 month: 75.8%, 2–4 years: 92.9%, >5 years: 96.4%)	-Technical complications in 4.8% of procedures, mostly incomplete wall apposition of device necessitating balloon angioplasty -4.4% of aneurysms had residual neck postoperatively -Retreatment in 4% of aneurysms -Complications included a 3.6% rate of stroke and a 1.8% rate of haemorrhage –4.6% all-cause mortality rate

Lylyk et al. 2009 – Argentina ²⁹	Prospective	Patients with IAs	-3D rotational angiogram -DSA	-Dual antiplatelet regimen -PED deployment	-By the 6-month follow-up complete occlusion was achieved in 93% of cases, which rose to 94.4% in 12 months* -Scores for all patients with an initial mRS of 0 or 1 remained unchanged postoperatively	-Only 8% of aneurysms showed complete occlusion –11% had complications intraoperatively, all of which were resolved -On 3-month angiographic follow-up 8% of vessels showed mild in-stent stenosis, while 5% of vessels had moderate or severe stenosis
Mandel et al. 2021 – Brazil ³⁰	Single-centre randomised parallel-group trial	Patients with unruptured IAs	Angiogram CT Scan	3 groups undergoing 3 different operative strategies: 1) Trans-eyelid approach (TelA) [MIS] 2) Nanopterional approach (NPtA) [MIS] 3) Pterional approach (PtA)	-The MIS approaches fared significantly better with greater stability and higher mRS postoperatively than the PtA group at 15–30 days and 12–18 months postoperatively ($P=0.0085$) -MIS groups had significantly higher self-satisfaction scores across all metrics considered -No significant difference in mortality between groups	-The one death reported occurred in the PtA group -The PtA group fared worse in postoperative cosmetic evaluation with significantly greater temporal muscle atrophy and was ranked as significantly less aesthetically pleasing by observers score across all metrics considered
Saal-Zapata et al. 2022 – Peru ³¹	Retrospective	Patients with IAs	3D Rotational Angiogram DSA	-Endovascular treatment with Penumbra coils 400 (stent-assisted or balloon-assisted), with the femoral approach	-No mortality -Good postoperative mRS in 88% of patients -At follow-up, 96% of patients had good clinical outcomes -Overall, an immediate aneurysmal obliteration seen in 36% of cases -Immediate mRROC was total (grade 1) in 15% of cases -On follow-up, mRROC grade 1 was seen in 58% of cases	-Coil protrusion in 16% of cases -1 patient developed MCA thrombosis, underwent thrombectomy -Overall complication rate was 6% -Most aneurysms had subtotal immediate occlusions as measured by mRROC, grade 2: 21%, grade 3A: 64%
Rocha-Filho et al. 2007 – Brazil ³²	Prospective	Patients with post-craniotomy headaches after procedures to treat supratentorial aneurysms IAs	Clinical examination Self-report	Craniotomies:- 89.7% pterional –5.8% fronto-orbital-zygomatic –4.6% frontal	None	-91.1% of patients had headache postoperatively -There was a positive, significant correlation between anxiety, depression, and headache frequency during the whole study period
<p>ACoA, anterior communicating artery; CI, confidence interval; DCI, delayed cerebral ischemia; EVD, external ventricular drainage; FRED, flow redirection endoluminal device; GA, general anesthesia; ICA, internal carotid artery; VPS, ventriculoperitoneal shunt; MSE, Mental State Examination; MIS, minimally invasive surgery; mRROC, modified Raymond Roy Occlusion Class; mRS, modified Rankin scale; IAs, intracranial aneurysms; CT, computed tomography; SAH, subarachnoid haemorrhage; PED, pipeline embolization device; SS, Surpass Streamline; IV, intravenous; TBO, temporary balloon occlusion; SPECT, single photon emitting computed tomography; ICU, intensive care unit; MDT, multidisciplinary team; ml, millilitre; OR, odds ratio.</p> <p>*Data are largely expressed as a percentage of the patient population to facilitate easier visualization by the reader, except where the study a) has a small patient population or b) has expressed data without providing percentages.</p> <p>†Follow-up statistics are expressed as a percentage of the total population which were available for follow-up.</p>						

Continues

Table 2. Continued

Author/Year/ Country	Study Type	Relevant Presentation	Diagnostic Method	Management Procedure(s)	Salient Outcomes	
					Positive Outcomes	Negative Outcomes
Manzato et al. 2021 – Brazil ³³	Single arm, multicentre, prospective observational	Patients with brain aneurysms	DSA	-Dual antiplatelet therapy -Endovascular treatment via FRED through the femoral route and heparinization -Stenting and coiling or balloon angioplasty as appropriate -Dual antiplatelet therapy continued for 6 months postoperatively	-Treatment was successful in all cases -Occlusion at 6 months was 91.3%, 95.9% at 12 months*	–4.6% complication rate
Pereira-Filho et al. 2010 – Brazil ³⁴	Prospective	Patients with anterior circulation aneurysms	Mini-MSE	Microsurgical clipping by pterional approach in 39 cases and anterior interhemispheric approach in 1 case	-All patients eventually obtained a GOS of 5 -No mortality	-Morbidity seen in 2 patients, one with a postoperative visual defect and one with hemiparesis and dysphasia, eventually resolved
Piske et al. 2009 – Brazil ³⁵	Prospective	Patients with wide-necked IAs	DSA CT brain MRI Clinical evaluation Neurological evaluation	-Dual antiplatelet therapy -HyperGlide balloon inserted, with contrast to assess how much inflation is necessary for occlusion of the aneurysm -Endovascular treatment under GA with the Onyx HD-500 Liquid Embolic System -Adjunctive devices like stents and coils used in a total of 4 cases	-Occlusion rates were assessed via angiographic assessments classified as such, with complete occlusion rates* (%): 1 -Control I (Immediately postoperative): 65.5% 2 -Control II (6 months):84.6% 3 -Control III (18 months):90.3% 4 -Control IV (36 months):80% -Recanalization rates decreased at every follow-up*	-Incomplete occlusion rate was 34.5% at control I decreased subsequently† -3 deaths, by sepsis, ICA thrombosis, and SAH each -5 complications, 2 cases of ischemia, 1 SAH, 1 chorea, and 1 cavernous cranial nerve change in 5 patients
Vivanco-Suarez et al. 2023 – Global ³⁶	International multicentre retrospective with a South American component	235 patients with IAs	CT scan	PED (92) SS (56) FRED (47) SILK (40)	-No statistically significant difference in occlusion rates of patients operated on with different devices, when using the Raymond-Roy classification. However, the SILK device achieved the highest Class I occlusions at 78%.	-Major ischemic event rates were 2%, 7%, 2%, and 10% for PED, SS, FRED, and Silk subgroups, respectively. No difference was noted between the subgroups ($P = 0.1$) -Technical assistance using an additional balloon or stent was required in 12% of the patients and was more common in the SS subgroup (24%) ($P = 0.004$)

<p>Waihrich et al. 2018 – Brazil³⁷</p>	<p>Retrospective and prospective</p>	<p>Patients with carotid siphon aneurysms</p>	<p>DSA</p>	<p>-Dual antiplatelet therapy started a week before treatment and continued 3 months post-treatment -Treatment via flow diverter stent with access by a triaxial system, a long sheath, an intermediate catheter, and a microcatheter -Patients discharged to ICU</p>	<p>-According to the O’Kelly-Marotta classification, 74.32% of patients exhibited grade D</p>	<p>–25.68% of patients exhibited non-grade D result (C3: 13.11%, C2: 3.28%, B: 0.0%, A3: 7.10%, A2: 2.19%)</p>
<p>Da Silva Jr et al. 2021 – Brazil³⁸</p>	<p>Multicentre Retrospective</p>	<p>Patients with residual or recurrent IAs</p>	<p>-Neurosurgical evaluation -3D rotational angiography</p>	<p>-Varying antiplatelet therapy for unruptured aneurysms only as appropriate according to aneurysmal characteristics <i>Antiplatelet regimen details:</i> -Unruptured aneurysms: aspirin (100 mg) for 5 days before treatment. In cases of flow diverter deployment or stenting, add clopidogrel. -For stent-assisted coiling, clopidogrel for 1 month postoperatively -For the flow diverter, 6 months post-treatment-Aspirin was maintained for 12 months. -GA administered -Heparinisation with spontaneous reversal <i>Treatment and indication:</i> -Simple coiling for unruptured narrow-neck aneurysms -Balloon-assisted coiling for unruptured wide-neck aneurysms -stent-assisted coiling for unruptured wide-neck aneurysms if located at bifurcation -Flow diversion for unruptured aneurysms if located at a sidewall</p>	<p>-The total occlusion rate was 73.1% on immediate postprocedure angiography (excluding aneurysms treated with a flow diverter) -At 1 year, the total occlusion rate was 75.3%</p>	<p>-Intraoperative complications in 6.8% of patients -Neck remnants were present in 20.3% and residual filling of the sac in 4.4% -Recanalization after endovascular retreatment was observed in 14.5% of the cases</p>

ACoA, anterior communicating artery; CI, confidence interval; DCI, delayed cerebral ischemia; EVD, external ventricular drainage; FRED, flow redirection endoluminal device; GA, general anesthesia; ICA, internal carotid artery; VPS, ventriculoperitoneal shunt; MSE, Mental State Examination; MIS, minimally invasive surgery; mRROC, modified Raymond Roy Occlusion Class; mRS, modified Rankin scale; IAs, intracranial aneurysms; CT, computed tomography; SAH, subarachnoid haemorrhage; PED, pipeline embolization device; SS, Surpass Streamline; IV, intravenous; TBO, temporary balloon occlusion; SPECT, single photon emitting computed tomography; ICU, intensive care unit; MDT, multidisciplinary team; ml, millilitre; OR, odds ratio.

*Data are largely expressed as a percentage of the patient population to facilitate easier visualization by the reader, except where the study a) has a small patient population or b) has expressed data without providing percentages.

†Follow-up statistics are expressed as a percentage of the total population which were available for follow-up.

Continues

Table 2. Continued

Author/Year/ Country	Study Type	Relevant Presentation	Diagnostic Method	Management Procedure(s)	Salient Outcomes	
					Positive Outcomes	Negative Outcomes
Soares et al., 2019 – Brazil ³⁹	Retrospective	Patients with ACoA aneurysms	-Digital angiography -CT angiography	-Access through pterional craniotomy in all cases -Temporary clipping (15%) -EVD (37%) -In patients with mild ventricular enlargement treated with daily therapeutic lumbar puncture and manometry	-GOS 4/5 in 54% of patients -Outcomes were significantly better among patients with unruptured aneurysms than in those with ruptured aneurysms ($P=0.01$).	-Intraoperative aneurysm rupture in 3% of cases -Clinical vasospasm in 43% of patients -GOS 1/2/3 in 46% of people -Complication rate of 41% -Mortality rate of 26%
Trivelato et al. 2013 – Brazil ⁴⁰	Retrospective	Patients with fenestration basilar artery aneurysms	-CT angiography -Catheter angiography -3D DSA	-Endovascular treatment, coiling for type 1A and 1B aneurysms, stent or balloon-assisted coiling in type 2A or 2B aneurysms	-5/8 patients had a grade A occlusion according to the Montreal Scale	-3/8 patients had a grade B occlusion -1 complication, perforation in a patient, initially stabilised but eventual death
Trivelato et al. 2019 – Brazil ⁴¹	Multicenter, prospective, interventional, single-arm trial	Patients with IAs	-Angiography	-Dual antiplatelet regimen started 5 days before and continued 6 months postoperatively -Heparin administered -The Derivo Embolisation Flow Diverter Device was introduced via a triaxial system -Coils used if appropriate -Balloon angioplasty undertaken to correct a device not expanded or incorrect wall apposition	-80.7% of aneurysms were totally occluded at six months which increased to 89.2% at 1 year* -94.5% of patients had no adverse events at follow-up	-Periprocedural complications in 7.3% of patients like improper device expansion -2.6% of patients had thromboembolic events, treatment of which resulted in 1 ischemic stroke -In-stent stenosis in 6.6% of patients -1.4% mortality rate
Trivelato et al. 2019 – Brazil ⁴²	2-centre comparative retrospective	Patients with IAs	-Catheter angiography -DSA	-Dual antiplatelet therapy -Heparinisation at 5000 U, no reversal -PED flow diverter deployed -Balloon angioplasty to correct wall apposition	-76.92% total occlusion rate at 6 months	-Death or major stroke in 3.45% of patients
Trivelato et al. 2019 – Brazil ⁴³	Observational Prospective single-arm multicentre	Patients with IAs (mid-term results)	-Angiography	-Dual antiplatelet therapy 5 days preoperative and 6 months postoperative -Standard triaxial introduction of PED -Balloon angioplasty if appropriate	-93.4% of patients had no rupture, haemorrhage, or neurological deficit	-Periprocedural complication rate was 7.3% -3 cases of in-stent stenosis at 6-month follow-up -Univariable analysis demonstrated that there was a significant influence of adjunctive coiling on morbimortality (OR 6.19, $P=0.021$) -In multivariate analysis, the performance of balloon angioplasty was also associated with treatment failure

Vanzin et al. 2012 – Brazil ⁴⁴	Retrospective	Patients with IAs	DSA	-Endovascular treatment with inert platinum coiling	-Class II occlusion according to Roy and Raymond’s scale is 76.1% at the initial result The final complete occlusion rate postretreatment was 77.8%	–26.8% recurrence rate -Class II and III occlusion rates increased on each follow-up
Perez et al. 2008 – Brazil ⁴⁵	Retrospective	Patients with carotid cavernous aneurysms	-CT cranium -Complete cerebral angiography -MRI	-Conservative management (52.5%) -Surgical management (47.5%) (23.5% - ICA ligation postcervicotomy, 3 patients with detachable balloon allocated endovascularly, 4 with embolization, 1 with embolization and ICA stent, 1 bypass, 1 trapping)	-In the group of patients surgically treated, 85% had improvement of pain, with 70% of patients reporting neurological improvement, and the other 30% stable. -Patients treated conservatively presented in 16.7% of the cases improvement of pain while 58.3% were stable -Overall, there was an improvement in pain symptoms in 56.7% of the cases, stability in 33.3% -Overall neurologically, there was an improvement in symptoms in 36.7% of the patients, stability in 50% and a deficit decrease in 13.3%. -Multinomial regression shows that surgical intervention has better neurological outcomes	-Among those undergoing surgery, a 36.8% complication rate -Patients treated conservatively did not have improvement of neurological deficits, 66.7% were stable and 33.3% presented intensification -Overall, increase in pain in 10% of cases
Abud et al. 2010 Brasil ⁴⁶	Prospective	106 Patients with 137 saccular aneurysms	-DSA -3D Angiography	–46% of aneurysms treated with coiling –38% underwent balloon remodeling –15% underwent stent remodeling –5.1% underwent therapeutic occlusion	–96% of the patients with unruptured aneurysms were discharged at an mRS 0 –2, with 94.6% reporting independence at follow-up -Of the 31 patients with SAH from rupture, 61.3% had a good grade on the Hunt-Hess scale -Angiographic result class I was obtained in 86.13% of aneurysms	The rate of technical complications was 6.6% inpatient population -Clinical complication rate was 5.7% -Of the 31 patients with SAH from rupture, 38.7% had a bad grade on the Hunt-Hess scale The rate of recurrence was 8.2% –8% overall mortality rate -Angiographic result class II and III was obtained in 6.57% and 7.3%. of aneurysms respectively

ACoA, anterior communicating artery; CI, confidence interval; DCI, delayed cerebral ischemia; EVD, external ventricular drainage; FRED, flow redirection endoluminal device; GA, general anesthesia; ICA, internal carotid artery; VPS, ventriculoperitoneal shunt; MSE, Mental State Examination; MIS, minimally invasive surgery; mRROC, modified Raymond Roy Occlusion Class; mRS, modified Rankin scale; IAs, intracranial aneurysms; CT, computed tomography; SAH, subarachnoid haemorrhage; PED, pipeline embolization device; SS, Surpass Streamline; IV, intravenous; TBO, temporary balloon occlusion; SPECT, single photon emitting computed tomography; ICU, intensive care unit; MDT, multidisciplinary team; ml, millilitre; OR, odds ratio.

*Data are largely expressed as a percentage of the patient population to facilitate easier visualization by the reader, except where the study a) has a small patient population or b) has expressed data without providing percentages.

†Follow-up statistics are expressed as a percentage of the total population which were available for follow-up.

Continues

Table 2. Continued					Salient Outcomes	
Author/Year/ Country	Study Type	Relevant Presentation	Diagnostic Method	Management Procedure(s)	Positive Outcomes	Negative Outcomes
De Aguiar et al. 2013 – Brazil ⁴⁷	Retrospective	30 patients with ACoA aneurysms	Transcranial Doppler studies	-Clipping with, 1) Group A: fenestration of the lamina terminalis and removal of cisternal clots (17 patients) 2) Group B: control (13 patients)	-Survival of the majority of the cohort	-One patient in group A and 5 in group B underwent subsequent endovascular treatment for vasospasm -One and 2 deaths in groups A and B, respectively -VPS required in 1 and 5 cases in groups A and B, respectively
Martinez -Galdamez et al. 2019 – Global ⁴⁸	International retrospective with a Colombian component	84 patients with IAs	Undisclosed	-Double antiplatelet therapy with heparinisation -Low-profile stents delivered via double-lumen balloons	-Immediate angiographic results demonstrated Raymond 1 occlusion rate in 77.9% of aneurysms -On follow-up, complete and near-complete occlusion rates were 90.1%, with no complications	-Raymond grade 2 and 3 occlusions achieved in 19.7% and 2.3% of aneurysms, respectively -Minor and major clinical events in 2.4% (thrombi) and 1.2% (mortality) of the population, respectively -A technical complication was reported in 11.6% of cases including in-stent thrombosis and branch thrombosis events
Zenteno et al. 2006 – Global ⁴⁹	Longitudinal international observational with a Brazilian component	36 patients with wide-neck and/or complex aneurysms	-DSA -CT scan	-Heparinization and double antiplatelet therapy administered -Balloon-expandable stents delivered to the site -Coiling is done in 58% of aneurysms -No coiling in 42% of aneurysms	-58% of aneurysms in the stenting + coiling cohort achieved total obliteration, with a further 43% achieving subtotal obliteration -Overall, 36% of aneurysms were totally obliterated, and 61% were subtotal obliterated	-Only 7% of total obliteration was achieved in aneurysms treated via stenting alone -Complications in 14% of cases, from thromboses to artery ruptures -Technical failures in 3% of aneurysms overall, with no further treatment possible
Wajnberg et al. 2009 – Brazil ⁵⁰	Prospective	24 patients with wide-necked IAs	-Angiography	-Coiling with a Neuroform stent under GA and after heparinisation	-Device delivery successful in 24/26 targets -No mortality or arterial dissection -14/21 aneurysms had complete occlusion -17 patients had a GOS of 5	-2 stent delivery failures, therefore a balloon was used for coil retention -7/21 were in some measure incomplete with 4 neck remnants and 3 incomplete occlusions -5 patients discharged with GOS 4, and 2 with a GOS 3
Pahl, Oliveira, and Rotta 2017 – Brazil ⁵¹	Undisclosed	43 patients with basilar tip aneurysms	-Angiography	-62.8% of patients underwent clipping -38.2% underwent endovascular treatment	The majority of the cohort survived -No mortality in patients with small aneurysms undergoing clipping, with all of them achieving a GOS 4–5 -In the 23 patients who had small aneurysms and underwent clipping, a 100% exclusion rate was observed on follow-up	-Transient third nerve palsy reported in 77% of patients, with recovery within a year -All (2) patients with giant aneurysms died -Patients with posteriorly positioned aneurysms were left with a residual neck

Martinez-Perez et al. 2020 – Chile ⁵²	Multicentre retrospective	Patients with acute aneurysmal SAH	-CT angiography -Clinical examination	-Aneurysms were clipped after a minipterional craniotomy	-Complete occlusion was achieved in 97% of aneurysms, with the one remaining found subtotally occluded postoperatively -On a 2.5-year follow-up, no significant change was seen in occlusion status	–5 patients developed vasospasms which were subsequently managed
Demartini Jr et al. 2018 – Brazil ⁵³	Retrospective	Patients with IAs	Angiography	-Heparinization -Coiling with 2 employing balloon remodelling and 2 employing stent assistance -A stent retriever device was employed and kept open for a few minutes The stent retriever was withdrawn under negative pressure	–5/10 cases of complete recovery –5/10 patients had a good mRS (0–1) at follow-up, improving from their immediate scores	–5/10 patients were discharged with disabilities including severe deficits, left or right hemiparesis, hemianopia, aphasia or facial paralysis –3/10 patients were left with long-term disabilities including 1 in a bedridden state, 1 with hemianopia, and 1 with cognitive impairment and upper limb monoparesis –2/10 patients had to retire from work due to poor outcome
De Aguiar et al. 2017 – Brazil ⁵⁴	Retrospective	Patients with residual IAs	DSA	Clipping	-Grade I aneurysm residuals were found in 13 aneurysms (34%), grade II in 9 aneurysms (24%)	-Grade III residuals in 10 aneurysms (26%), grade IV in 2 aneurysms (5%), and grade V in 4 aneurysms (10%)
Mura et al. 2007 – Chile ⁵⁵	Prospective, nonrandomized case series	Patients with aneurysmal SAH	CT scan DSA	2 groups 1) Microsurgical treatment: clipping, extensive cleansing of cisternal blood and microsurgical fenestration of the lamina terminalis (95 patients) 2) Endovascular treatment via coiling (28 patients)	-No significant difference between vasospasm or hydrocephalus presentation in 2 groups -The calculated mean of GOS scores was 4.35 ± 1.09 for the microsurgical group and 3.37 ± 1.52 for the endovascular groups ($P < 0.001$) -Mean GOS was significantly better for patients undergoing cisternal blood cleansing plus lamina terminalis fenestration	-The mean GOS scores in the endovascular group show a clear tendency toward a worse prognosis with delayed timing of treatment -Late cerebral infarction rate 3.1% and 14.3% for microsurgical and endovascular treatment, respectively
Demartini Jr. et al. 2023 – Brazil ⁵⁶	Retrospective cross-sectional	11 pediatric patients with IAs;	Undisclosed	-Endovascular treatment (70%) -Coiling (40%) –3 patients underwent clipping	–10/11 patients discharged with mRS 0 –2	–5/11 patients had complications such as sepsis, shock, renal failure, hydrocephalus, vasospasms, and so on. –1 death

ACoA, anterior communicating artery; CI, confidence interval; DCI, delayed cerebral ischemia; EVD, external ventricular drainage; FRED, flow redirection endoluminal device; GA, general anesthesia; ICA, internal carotid artery; VPS, ventriculoperitoneal shunt; MSE, Mental State Examination; MIS, minimally invasive surgery; mRROC, modified Raymond Roy Occlusion Class; mRS, modified Rankin scale; IAs, intracranial aneurysms; CT, computed tomography; SAH, subarachnoid haemorrhage; PED, pipeline embolization device; SS, Surpass Streamline; IV, intravenous; TBO, temporary balloon occlusion; SPECT, single photon emitting computed tomography; ICU, intensive care unit; MDT, multidisciplinary team; ml, millilitre; OR, odds ratio.

*Data are largely expressed as a percentage of the patient population to facilitate easier visualization by the reader, except where the study a) has a small patient population or b) has expressed data without providing percentages.

†Follow-up statistics are expressed as a percentage of the total population which were available for follow-up.

Continues

Table 2. Continued

Author/Year/ Country	Study Type	Relevant Presentation	Diagnostic Method	Management Procedure(s)	Salient Outcomes	
					Positive Outcomes	Negative Outcomes
Aurich et al. 2012 – Brazil ⁵⁷	Retrospective	Patients with IAs	Angiography	-All patients underwent remodelling via balloon or stent, coiling postheparinization -In 4 patients (11.76%) the balloon remodelling technique was associated with the stent remodelling technique due to the occurrence of coil protrusion into the parent vessel	-85.29% of aneurysms totally occluded, with partial occlusion in 5.88%	-1 mortality due to procedural haemorrhage -5.88% of aneurysms had no occlusion
Adeeb et al. 2022 – Global ⁵⁸	Retrospective with a South American component	Patients with sidewall or bifurcation IAs -Bifurcation: 572 aneurysms (group A) Sidewall: 111 aneurysms (group B)	-CT and MR angiography -DSA	-Woven Endobridge (WEB) device used	-Immediate WEB aneurysm occlusion rate higher in B versus A (66.1% vs. 43.3%) -No other significant difference between the 2 approaches	-More technical complications experienced by group B, although statistically insignificant
Goncalves et al. 2022 – Brazil ⁵⁹	Prospective	666 patients with aneurysmal SAH	CT scan	-Clipping (66%) -Coiling (25%) -No treatment (08%)	The majority of the cohort survived	-07% rebleeding rate -35% vasospasm rate -23% of patients had neurological deterioration -24% in-hospital mortality rate -55% had poor outcomes (mRS 4–6) at discharge which fell to 40%
Yoshikawa et al. 2022 – Brazil ⁶⁰	Prospective cohort	Patients with IAs undergoing temporary arterial occlusion (TAO) and being assessed for its prognostic value	Undisclosed	-Pterional craniotomy (15/24) -Minipterional craniotomy (5/24) -Prontotemporal (1/24) -Pretemporal (1/24) -Others (2/24) -12/24 had 1 TAO, 10/24 had 2 temporary clips, and 2/24 had 3 or more	-Survival of the majority of the cohort	-56.2% versus 22.2% postoperative complication rate in the TAO versus non-TAO cohort -12.5% versus 1.1% brain death rate in TAO versus non-TAO cohort -The location of temporary clip placement and the number of clips did not influence the short- and long-term outcomes of patients with unruptured intracranial aneurysms

Cavalcanti et al. 2017 – Brazil ⁶¹	Prospective	Patients with IAs	Undisclosed	-Minisphenoidal keyhole craniotomy performed (117) -Other unspecified craniotomies (128) -Endovascular treatment (283)	-Overall occlusion rate of 97.8% -No patients who had unruptured aneurysms had an outcome of mRS>3, with favourable outcomes in 98.1% of the cohort and 89.1% having an mRS of 0–1 -In the ruptured group, 78.6% of patients had favourable outcomes, with 88.6% discharged postoperatively	–4.3% of patients with a ruptured aneurysm died postoperatively –10% of the patients with ruptured aneurysms presented after the initial operation with hydrocephalus, which was then treated
Sousa et al. 2018 – Brazil ⁶²	Retrospective	Patients with saccular IAs	Angiography	-Coiling with, Balloon-assisted remodeling in 10.9% of cases, and stent deployment in 20.7%	-The Raymond scale score postoperatively was I in 79.3% of cases, II in 12.6% of cases	-In 23.6% of cases, there was a worsening of angiographic obliteration (recanalization) -The Raymond scale score postoperatively was III in 8% of cases
Vieira et al. 2022 – Brazil ⁶³	Prospective	Patients with ruptured IAs	CT angiogram DSA	-Microsurgical clipping	-Complete aneurysm occlusion was observed in 94.2% of patients	- Overall, 22.6% of patients had an unfavourable outcome (mRS>2), and the mortality rate was 8% -DCI occurred in 20.7% of cases -Residual neck and residual aneurysms were seen in 4.6% and 1% of cases, respectively -Shunt-dependent hydrocephalus occurred in 10% of patients –11.6% overall surgical complication rate
Diaz et al. 2013 – Colombia ⁶⁴	Prospective	Patients with IAs	3D angiography	-Dual antiplatelet therapy started 7 days preoperatively -Endovascular treatment via the FRED system	-Immediate flow reduction seen in all cases -No technical or clinical complications	None
Da Costa et al. 2023 – Brazil ⁶⁵	Retrospective	Patients with PComA IAs with oculomotor nerve palsy	CT scan MRI Angiography	Clipping	–45.4% of patients with palsy recovered complete function during the study period, with a further 35.3% showing partial recovery	–19.3% showed no recovery during the study period

AComA, anterior communicating artery; CI, confidence interval; DCI, delayed cerebral ischemia; EVD, external ventricular drainage; FRED, flow redirection endoluminal device; GA, general anesthesia; ICA, internal carotid artery; VPS, ventriculoperitoneal shunt; MSE, Mental State Examination; MIS, minimally invasive surgery; mRROC, modified Raymond Roy Occlusion Class; mRS, modified Rankin scale; IAs, intracranial aneurysms; CT, computed tomography; SAH, subarachnoid haemorrhage; PED, pipeline embolization device; SS, Surpass Streamline; IV, intravenous; TBO, temporary balloon occlusion; SPECT, single photon emitting computed tomography; ICU, intensive care unit; MDT, multidisciplinary team; ml, millilitre; OR, odds ratio.

*Data are largely expressed as a percentage of the patient population to facilitate easier visualization by the reader, except where the study a) has a small patient population or b) has expressed data without providing percentages.

†Follow-up statistics are expressed as a percentage of the total population which were available for follow-up.

Continues

Table 2. Continued

Author/Year/ Country	Study Type	Relevant Presentation	Diagnostic Method	Management Procedure(s)	Salient Outcomes	
					Positive Outcomes	Negative Outcomes
Dellaretti 2018 — Brazil ⁶⁶	Retrospective	Patients with IAs	DSA	Microsurgical treatment	-Overall, 73.4% of patients had a good outcome (mRS equal to or less than 2) -89.8% of patients showed complete aneurysm occlusion	-Overall, 12% (37) mortality rate -Overall, 26.3% (81) of patients had a poor outcome (mRS equal or more than 3) -There were 4 deaths among patients with unruptured aneurysms and 33 deaths among those with ruptured aneurysms ($P < 0.015$). -Analysis showed poor outcomes in 33.9% of patients with ruptured aneurysms, compared with only 8.9% of patients with unruptured aneurysms, a statistically significant difference ($P < 0.001$) -10.2% of patients had residual aneurysms -Reoperation was needed in 3.5% of aneurysms
Dellaretti 2021 — Brazil ⁶⁷	Retrospective	Patients with MCA aneurysms	DSA	Microsurgery	-Overall, 76.8% of patients had a good outcome (mRS equal to or less than 2) -On postoperative DSA, 83% of patients had complete occlusion	-Overall, 23.2% of patients had a poor outcome (mRS equal or more than 3) -On postoperative DSA, 17% of patients had a residual neck -8.9% overall mortality rate
Taschner et al. 2017 — Global ⁶⁸	International, multicentre, retrospective with an Argentinian component	Patients with posterior circulation aneurysms	MR angiography	-Dual antiplatelet therapy initiated 5 days pretreatment -Treatment via the SS flow diverter with 15% of patients additionally coiled	-Technical success in 98% of patients -78% of patients alive on discharge were clinically stable and 14% had improved neurologically -Complete occlusion in 66% at follow-up -Asymptomatic patients had 5% morbidity and no mortality	-27% of the patients had some neurologic symptoms 24 hours post- treatment -27% mortality and morbidity rate overall, and an overall all-cause mortality rate of 17% -Symptomatic patients had morbidity and mortality rates of 44% and 28%, respectively

ACoA, anterior communicating artery; CI, confidence interval; DCI, delayed cerebral ischemia; EVD, external ventricular drainage; FRED, flow redirection endoluminal device; GA, general anesthesia; ICA, internal carotid artery; VPS, ventriculoperitoneal shunt; MSE, Mental State Examination; MIS, minimally invasive surgery; mRROC, modified Raymond Roy Occlusion Class; mRS, modified Rankin scale; IAs, intracranial aneurysms; CT, computed tomography; SAH, subarachnoid haemorrhage; PED, pipeline embolization device; SS, Surpass Streamline; IV, intravenous; TBO, temporary balloon occlusion; SPECT, single photon emitting computed tomography; ICU, intensive care unit; MDT, multidisciplinary team; ml, millilitre; OR, odds ratio.

*Data are largely expressed as a percentage of the patient population to facilitate easier visualization by the reader, except where the study a) has a small patient population or b) has expressed data without providing percentages.

†Follow-up statistics are expressed as a percentage of the total population which were available for follow-up.

and inadequate research funding represent barriers to optimal care of patients with IAs in South America. By bolstering research funding, expanding specialized educational programs, adapting the MDT approach to care centered around patient feedback, and fostering international collaborations, the landscape of IA management in South America can be significantly improved.

CRedit AUTHORSHIP CONTRIBUTION STATEMENT

Mohammed Dheyaa Marsool Marsool: Conceptualization, Writing – original draft, Writing – review & editing. **Hareesha Rishab Bharadwaj:** Conceptualization, Writing – original draft, Writing – review & editing. **Syed Hasham Ali:** Visualization, Writing – original draft, Writing – review & editing. **Nicholas Aderinto:** Writing – original draft, Writing – review & editing. **Muhammad Hamza Shah:** Writing – original draft, Writing – review & editing. **Nathanael Shing:** Writing – original draft, Writing – review & editing. **Priyal Dalal:** Visualization, Writing – original draft, Writing – review & editing. **Helen Huang:** Writing – original draft, Writing – review & editing. **Jack Wellington:** Writing – original draft, Writing – review & editing. **Talhah Chaudri:** Writing – original draft, Writing – review & editing. **Wireko Andrew Awuah:** Writing – original draft, Writing – review & editing. **Niels Pacheco-Barrios:** Supervision, Writing – original draft, Writing – review & editing. **Daniel Fernandez-Guzman:** Supervision, Writing – original draft, Writing – review & editing. **Khabab Abbasher Hussien Mohamed Ahmed:** Supervision, Writing – review & editing.

ACKNOWLEDGMENTS

All authors have read and approved the final version of the manuscript, and Hareesha Rishab Bharadwaj had full access to all of the data in this study and takes complete responsibility for the integrity of the data and the accuracy of the data analysis. Hareesha Rishab Bharadwaj affirms that this manuscript is an honest, accurate, and transparent account of the study being reported; that no

important aspects of the study have been omitted; and that any discrepancies from the study planned have been explained.

REFERENCES

- Toth G, Cerejo R. Intracranial aneurysms: review of current science and management. *Vasc Med.* 2018;23:276-288.
- Seibert B, Tummala RP, Chow R, Faridar A, Mousavi SA, Divani AA. Intracranial aneurysms: review of current treatment options and outcomes. *Front Neurol.* 2011;2:45.
- Chalouhi N, Hoh BL, Hasan D. Review of cerebral aneurysm formation, growth, and rupture. *Stroke.* 2013;44:3613-3622.
- Francis SE, Tu J, Qian Y, Avolio AP. A combination of genetic, molecular and haemodynamic risk factors contributes to the formation, enlargement and rupture of brain aneurysms. *J Clin Neurosci.* 2013;20:912-918.
- Korja M, Kaprio J. Controversies in epidemiology of intracranial aneurysms and SAH. *Nat Rev Neurol.* 2015;12:50-55.
- Lindgren A, Vergouwen MD, van der Schaaf I, et al. Endovascular coiling versus neurosurgical clipping for people with aneurysmal subarachnoid haemorrhage. *Cochrane Database Syst Rev.* 2018;8:CD003085.
- Tawk RG, Hasan TF, D'Souza CE, Peel JB, Freeman WD. Diagnosis and treatment of unruptured intracranial aneurysms and aneurysmal subarachnoid hemorrhage. *Mayo Clin Proc.* 2021;96:1970-2000.
- Morgan MK, Mahattanakul W, Davidson A, Reid J. Outcome for middle cerebral artery aneurysm surgery. *Neurosurgery.* 2010;67:755-761.
- Zhao J, Lin H, Summers R, Yang M, Cousins BG, Tsui J. Current treatment strategies for intracranial aneurysms: an overview. *Angiology [Internet].* 2017;69:17-30.
- Ajiboye N, Chalouhi N, Starke RM, Zanaty M, Bell R. Unruptured cerebral aneurysms: evaluation and management. *Sci World J.* 2015;2015:1-10.
- Almubaslat F, Sanchez-Boluarte SS, Diaz MM. A review of neurological health disparities in Peru. *Front Public Health [Internet].* 2023;11:1210238.
- Perez-Chadid D, Cristina A, Asfaw ZK, et al. Needs, roles, and challenges of young Latin American and Caribbean neurosurgeons. *World Neurosurgery.* 2023;176:e190-e199.
- Vigueras R, Vigueras S, Luna F. Aneurismas Cerebrales: caracterización de los datos encontrados en un protocolo de seguimiento de un Hospital Regional. *Rev Chil Neuro Psiquiatr.* 2003;41:111-116.
- de Araújo Júnior AS, de Aguiar PH, Fazzito MM, et al. Prospective factors of temporary arterial occlusion during anterior communicating artery aneurysm repair. *Acta neurochirurgica.* 2014;120:231-235.
- de Castro-Afonso LH, Nakiri GS, Abud TG, et al. Treatment of distal unruptured intracranial aneurysms using a surface-modified flow diverter under prasugrel monotherapy: a pilot safety trial. *J Neurointerventional Surg.* 2021;13:647-651.
- de M, Castro RN, Lundquist J, et al. The role of the pipeline embolization device for the treatment of dissecting intracranial aneurysms. *Am J Neuro-radiol.* 2011;32:2192-2195.
- Dellaretti M, Martins S, Dourado JC, et al. Angiographic and epidemiological characteristics associated with aneurysm remnants after microsurgical clipping. *Surg Neurol Int.* 2017;8:198.
- Aversa A, Domingues FS, Espinosa G, et al. Complex paraclinoidal and giant cavernous aneurysms: importance of preoperative evaluation with temporary balloon occlusion test and SPECT. *Arquivos De Neuro-psiquiatria.* 2006;64:768-773.
- Echeverría D, Rivera R, Giacaman P, Sordo JG, Einersen M, Badilla L. A novel self-expanding shape memory polymer coil for intracranial aneurysm embolization: 1 year follow-up in Chile. *J Neurointerv Surg.* 2022;15:781-786.
- Estevão IA, Camporeze B, Araujo AS, et al. Middle cerebral artery aneurysms: aneurysm angiographic morphology and its relation to pre-operative and intra-operative rupture. *Arq Neuro Psiquiatr.* 2017; 75:523-532.
- Figueiredo EG, Welling LC, Preul MC, et al. Surgical experience of minipterional craniotomy with 102 ruptured and unruptured anterior circulation aneurysms. *J Clin Neurosci.* 2016;27:34-39.
- Lylyk P, Ferrario A, Pabón B, Miranda C, Dorozzuk G. Buenos Aires experience with the Neuroform self-expanding stent for the treatment of intracranial aneurysms. *J Neurosurg.* 2005;102: 235-241.
- Lopes DK, Jang DK, Cekirge S, et al. Morbidity and mortality in patients with posterior circulation aneurysms treated with the pipeline embolization device: a subgroup analysis of the international retrospective study of the pipeline embolization device. *Neurosurgery.* 2017;83:488-500.
- Foa Torres G, Roca F, Noguera A, et al. Silk flow-diverter stent for the treatment of complex intracranial aneurysms: a one-year follow-up multi-center study. *Interv Neuroradiol.* 2018;24:357-362.
- Fonseca RB, Correia AO, Vieira RS, et al. Comparative study between minimally invasive supraorbital craniotomy and pterional craniotomy for treating anterior circulation cerebral aneurysms in a low-resource setting. *Sci Rep.* 2021;11: 5555.
- Fujimoto M, Lylyk I, Bleise C, Palmarola PA, Chudyk J, Lylyk P. Long-term outcomes of the WEB device for treatment of wide-neck bifurcation aneurysms. *Am J Neuroradiol.* 2020;41: 1031-1036.
- Giacomini L, Piske RL, Baccin CE, Barroso M, Joaquim AF, Tedeschi H. Neurovascular reconstruction with flow diverter stents for the treatment of 87 intracranial aneurysms: clinical results. *Interventional Neuroradiology.* 2015;21:292-299.

28. Lylyk I, Scrivano E, Lundquist J, et al. Pipeline embolization devices for the treatment of intracranial aneurysms, single-center registry: long-term angiographic and clinical outcomes from 1000 aneurysms. *Neurosurgery*. 2021;89:443-449.
29. Lylyk P, Miranda CH, Ceratto R, et al. Curative endovascular reconstruction OF cerebral aneurysms with the pipeline embolization device: the Buenos Aires experience. *Neurosurgery*. 2009;64:632-643.
30. Mandel M, Mamoru R, Li Y, et al. MISIAN (minimally invasive surgery for treatment of unruptured intracranial aneurysms): a prospective randomized single-center clinical trial with long-term follow-up comparing different minimally invasive surgery techniques with standard open surgery. *World Neurosurgery*. 2021;151:e533-e544.
31. Saal-Zapata G, Ghodke B, Walker M, Preguntegui-Loayza I, Rodríguez-Varela R. Endovascular treatment of medium and large intracranial aneurysms with large volume coils: a single-center experience. *Surg Neurol Int*. 2022;13:9.
32. Rocha-Filho PA, Gherpelli JL, de Siqueira JT, Rabello GD. Post-Craniotomy headache: characteristics, behaviour and effect on quality of life in patients operated for treatment of supratentorial intracranial aneurysms. *Cephalalgia*. 2007;28:41-48.
33. Manzato LB, Santos RB, Filho PMM, Miotto G, Bastos AM, Vanzin JR. Brazilian FRED registry: a prospective multicenter study for brain aneurysm treatment—the BRED study. *Am J Neuroradiol*. 2021;42:1822-1826.
34. Pereira-Filho AA, Pereira AG, Faria MB, Lima LC, Portuguez MW, Kraemer JL. Microsurgical clipping in forty patients with unruptured anterior cerebral circulation aneurysms: an investigation into cognitive outcome. *Arquivos De Neuro-psiquiatria*. 2010;68:770-774.
35. Leo Piske R, Kanashiro LH, Homero E, Agner C, Silveira Lima S. Paulo. Evaluation OF ONYX HD-500 EMBOLIC system IN the treatment OF 84 WIDE-NECK INTRACRANIAL aneurysms. *Neurosurgery*. 2009;64:E865-E875.
36. Vivanco-Suarez J, Rodríguez-Calienes A, Kan P, et al. Flow diverter performance in aneurysms arising from the posterior communicating artery: a systematic review and meta-analysis. *Neurosurgery*. 2023;93:764-772.
37. Waihrich E, Clavel P, Mendes G, Iosif C, Kessler IM, Mounayer C. Influence of anatomic changes on the outcomes of carotid siphon aneurysms after deployment of flow-diverter stents. *Neurosurgery*. 2018;83:1226-1233.
38. da Silva Júnior NR, Trivelato FP, Nakiri GS, et al. Endovascular treatment of residual or recurrent intracranial aneurysms after surgical clipping. *J Cerebrovasc Endovasc Neurosurg*. 2021;23:221-232.
39. Soares FP, Velho MC, Martins C. Clinical and morphological profile of aneurysms of the anterior communicating artery treated at a neurosurgical service in Southern Brazil. *Surg Neurol Int*. 2019;10:193.
40. Trivelato FP, Salles Rezende MT, Castro GD, Manzato LB, Santoro Araújo JF, Ulhôa AC. Endovascular treatment of isolated posterior inferior cerebellar artery dissecting aneurysms: parent artery occlusion or selective coiling? *Clin Neuroradiol*. 2013;24:255-261.
41. Trivelato FP, Abud DG, Ulhôa AC, et al. Derivo embolization device for the treatment of intracranial aneurysms. *Stroke*. 2019;50:2351-2358.
42. Trivelato FP, Salles Rezende MT, Ulhôa AC, Henrique de Castro-Afonso L, Nakiri GS, Abud DG. Occlusion rates of intracranial aneurysms treated with the Pipeline embolization device: the role of branches arising from the sac. *J Neurosurg*. 2018;1-7. <https://doi.org/10.3171/2017.10.JNS172175>.
43. Trivelato FP, Wajnberg E, Rezende MTS, et al. Safety and effectiveness of the pipeline flex embolization device with shield technology for the treatment of intracranial aneurysms: midterm results from a multicenter study. *Neurosurgery*. 2019;87:104-111.
44. Vanzin JR, Mounayer C, Abud DG, D'agostini Annes R, Moret J. Angiographic results in intracranial aneurysms treated with inert platinum coils. *Intervent Neuroradiol*. 2012;18:391-400.
45. Perez L, Antônio J, Esteves C, Luiz M, Shiozawa P. Presentation and treatment of carotid cavernous aneurysms. *Arquivos De Neuro-psiquiatria*. 2008;66:189-193.
46. Abud DG, Nakiri GS, Abud TG, Carlotti CG, Colli BO, Santos AC. Endovascular therapy for selected (most non-surgical) intracranial aneurysms in a Brazilian University Hospital. *Arquivos De Neuro-psiquiatria*. 2010;68:764-769.
47. Paulo BI, Lembo B, Simm R. Removal of clots in subarachnoid space could reduce the vasospasm after subarachnoid hemorrhage. *Acta neurochirurgica*. 2012;115:91-93.
48. Martínez-Galdámez M, Orlov K, Kądziołka K, et al. Safety and efficacy of intracranial aneurysm embolization using the "combined remodeling technique": low-profile stents delivered through double lumen balloons: a multicenter experience. *Neuroradiology*. 2019;61:1067-1072.
49. Zenteno M, Freitas M, Aburto-Murrieta Y, Luis Koppe G, Machado E, Lee Á. Balloon-expandable stenting with and without coiling for wide-neck and complex aneurysms. *Surg Neurol*. 2006;66:603-610.
50. Wajnberg E, de Souza JM, Marchiori E, Gasparetto EL. Single-center experience with the Neuroform stent for endovascular treatment of wide-necked intracranial aneurysms. *Surg Neurol*. 2009;72:612-619.
51. Pahl FH, Oliveira MFD, Rotta JM. Microsurgical treatment of basilar tip aneurysms: is it still acceptable? *Arq Neuro Psiquiatr*. 2017;75:697-702.
52. Martínez-Pérez R, Tsimpas A, Cuevas JL, et al. Microsurgical clipping of multiple cerebral aneurysms in the acute phase of aneurysmal subarachnoid hemorrhage through a minipterional approach: the Chilean experience. *Clin Neurol Neurosurg*. 2020;198:106243.
53. Demartini Junior Z, Gatto LAM, Koppe GL, Oliveira TFFH, Francisco AN. Rescue therapy with stent retrievers for thromboembolism during endovascular treatment of intracranial aneurysms. *Arquivos De Neuro-psiquiatria*. 2018;76:332-338.
54. Aguiar PHPD, Estevão IA, Pacheco CC, Maldaun MVC, Oliveira CTPD. Distal anterior cerebral artery aneurysms (pericallosal artery): a report of 19 cases and literature review. *Turkish Neurosurgery*; 2016.
55. Mura J, Rojas-Zalazar D, Ruiz Á, Vintimilla LC, Marengo J. Improved outcome in high-grade aneurysmal subarachnoid hemorrhage by enhancement of endogenous clearance of cisternal blood clots: a prospective study that demonstrates the role of lamina terminalis fenestration combined with modern microsurgical cisternal blood evacuation. *Minimally Invasive Neurosurgery*. 2007;50:355-362.
56. Demartini Z, Pardins JP, Koppe GL, Maeda AK, Mattozo CA, Cardoso-Demartini A. Pediatric intracranial aneurysms in a Southern Brazilian population. *Child's Nerv Syst*. 2023;39:3543-3549.
57. Aurich LA, Leal AG, Ramina R, Meneses MS. Balloon remodeling technique in endovascular treatment of intracranial aneurysms. *J Bras Neurocir*. 2012;23:205-210.
58. Adeeb N, Dibas M, Danilo J, et al. Multicenter study for the treatment of sidewall versus bifurcation intracranial aneurysms with use of woven EndoBridge (WEB). *Radiology*. 2022;304:372-382.
59. Gonçalves B, Rynkowski C, Turon R, et al. Clinical Characteristics and Outcomes of Patients with Aneurysmal Subarachnoid Hemorrhage: A Prospective Multicenter Study in a Middle-Income Country. *Neurocrit Care*. 2022;38:378-387.
60. Yoshikawa MH, Rabelo NN, Telles JPM, et al. Temporary arterial occlusion (TAO) as independent prognostic factor in unruptured aneurysm surgery: a cohort study. *J Clin Neurosci*. 2022;99:78-81.
61. Cavalcanti DD, Roberto, Alvarenga PL, Pereira PE, Niemeyer Filho P. Engaging in a keyhole concept for the management of ruptured and unruptured aneurysms. *World Neurosurgery*. 2017;102:466-476.
62. Emerson Brandão Sousa FL, Braga Tavares C, Nazareno J, Kessler IM. Importance of the first coil in the embolization of intracranial aneurysms. *Clin Neuroradiol*. 2018;29:733-740.
63. Vieira E, Guimarães T, Pontes A, et al. Initial experience in the microsurgical treatment of ruptured brain aneurysms in the endovascular era: characteristics and safety of the learning curve in the first 300 consecutively treated patients. *Acta Neurochir*. 2022;164:973-984.
64. Diaz O, Gist TL, Manjarez G, Orozco F, Almeida R. Treatment of 14 intracranial aneurysms with the FRED system. *J Neurointerventional Surg*. 2013;6:614-617.
65. Devanir M, Joao ZM, Berci Filho P, Ferrari R, Reys L, et al. Risks for oculomotor nerve palsy and time to recovery after surgical clipping of posterior communicating artery aneurysms: a multicenter retrospective cohort study. *Neurosurgery*. 2023;92:1192-1198.

66. Dellaretti M, Ronconi D, Malta Batista D, et al. Safety and efficacy of surgical treatment of intracranial aneurysms: the experience of a single Brazilian center. *World Neurosurgery*. 2018;117: e580-e587.
67. Dellaretti M, do Nascimento LM, de Oliveira Lima AD, de Almeida JC, Quadros RS. Efficacy and safety of surgical treatment for middle cerebral artery aneurysms: a retrospective case series. *Interdisciplinary Neurosurgery*. 2021;23:101018.
68. Taschner C, Srinivasan V, de Vries J, et al. Surpass flow diverter for treatment of posterior circulation aneurysms. *Am J Neuroradiol*. 2016;38:582-589.
69. González N, Mosquera J, Ruiz-Aburto A, et al. A1-A2 fenestration tube technique for clipping a ruptured anterior communicating artery aneurysm. *Arquivos Brasileiros de Neurocirurgia: Brazilian Neurosurgery*. 2019;38:153-156.
70. Ribeiro L, De Menezes R, Madeira K. Microsurgery of cerebral aneurysm: epidemiological profile. *Arquivos Brasileiros de Neurocirurgia: Brazilian Neurosurgery*. 2020;39:101-107.
71. Peña Tapia PG, Rodas López MF. Comunicado de 62 aneurismas cerebrales clipados en el Hospital Regional Docente Vicente Corral Moscoso de la ciudad de Cuenca, Ecuador. *Rev Neurol*. 2003;37: 430.
72. Rojas H, Toscano Simões R, Dellaretti M, Victor F. Trends for in-hospital metrics in the treatment of intracranial aneurysms in Minas Gerais, Brazil. *Hospital Practice*. 2019;47:163-169.
73. Akly MP, Vázquez C, Besada C, et al. Prevalence of intracranial aneurysms in hereditary hemorrhagic telangiectasia: report from a single reference center. *Am J Neuroradiol*. 2022;43:844-849.
74. Alcalá-Cerra G, Young AM, Paternina-Caicedo Á, Ribas ES. Trends in the mortality of non-traumatic subarachnoid hemorrhage in Colombia: a 10-year analysis of a nationwide registry. *Arquivos De Neuro-psiquiatria*. 2013;71: 841-845.
75. Jochen Hackembruch H, Perna A, Ketzoian C. Mortality trends by stroke in Uruguay. *J Neurol Sci*. 2013;333:e209-e210.
76. Bocanegra-Becerra JE, Castillo-Huerta NM, Ludeña-Esquivel A, Nicole Torres-García O, Vilca-Salas MI, Bermudez-Pelaez MF. The humanitarian aid of neurosurgical missions in Peru: a chronicle and future perspectives. *Surg Neurol Int*. 2022;13: 545.
77. Soriano Sánchez JA, Perilla Cepeda TA, Birrium Borba LA, Soto Garcia ME, Israel Romero Rangel JA. Current workforce status of the neurosurgery Societies belonging to the Latin American federation of neurosurgical Societies: a survey of the presidents of these neurosurgery Societies. *World Neurosurgery*. 2020;143:e78-87.
78. Rubiano AM, Parra DMS, Arcos LER, Zúñiga RR. Neurosurgery education around the world: central and South America. *Neurosurgery and Global Health*. 2022;239-254.
79. Ciocca DR, Delgado G. The reality of scientific research in Latin America; an insider's perspective. *Cell Stress & Chaperones [Internet]*. 2017;22: 847-852.
80. Ashfaq A, Lazareff JA. Language and style: a barrier to neurosurgical research and advancement in Latin America. *Surg Neurol Int*. 2017;8:308.
81. Visconti-Lopez FJ, Solorzano-Salazar DM, Vargas-Fernández R. Neurosurgery Research Productivity in Latin American and Caribbean Countries: A Bibliometric and Visualized Study. *World Neurosurgery*; 2022.
82. Fatania K, Patankar DT. Comprehensive review of the recent advances in devices for endovascular treatment of complex brain aneurysms. *Br J Radiol*. 2022;95:20210538.
83. Molina-Martinez MA, Miller E. The evolution of neurosurgery in Central America. *World Neurosurgery*. 2012;77:431-433.
84. Murguía-Fuentes R, Husein N, Vega A, et al. Neurosurgical residency training in Latin America: current status, challenges, and future opportunities. *World Neurosurgery*. 2018;120:e1079-e1097.
85. Chomsky-Higgins K, Miclau T, MacKechnie MC, et al. Barriers to clinical research in Latin America. *Front Public Health [Internet]*. 2017;5:57.
86. Penchaszadeh VB. Ethical issues in genetics and public health in Latin America with a focus on Argentina. *J Community Genet*. 2015;6:223-230.
87. Junior JR, Oliveira LM, Boechat AL, Teixeira MJ, Figueiredo EG. Cavernous carotid artery aneurysms on a single institution: An epidemiological study with 201 patients. *Clin Neurol Neurosurg*. 2019; 186:105504.
88. Corell A, Guo A, Vecchio TG, Ozanne A, Jakola AS. Shared decision-making in neurosurgery: a scoping review. *Acta Neurochir*. 2021;163: 2371-2382.
89. De Biase G, Freeman WD, Bydon M, et al. Telemedicine utilization in neurosurgery during the COVID-19 pandemic: a glimpse into the future? *Mayo Clin Proc: Innovations, Quality & Outcomes*. 2020;4:736-744.
90. Sarmiento RM, Rosa RDS. Internações hospitalares para tratamento de aneurismas cerebrais rotos e não rotos no Sistema Único de Saúde do Brasil, 2009-2018: um estudo descritivo. *Epidemiol Serv Saúde*. 2022;31:e20211122.
91. Harker P, Quitián-Reyes H, Feo-Lee OH, Iragorri N, Puentes JC. Cost-effectiveness analysis applied to the treatment of unruptured anterior circulation aneurysms in a middle-income country. *Universitas Medica*. 2020;61:1-8.
92. Lozada-Martinez ID, Ortega-Sierra MG, Hernández-Morales EY, et al. Letter to the Editor. Latin American collaboration in international neurotrauma registries: a strategy from the academy. *J Neurosurg*. 2022;1-2. <https://doi.org/10.3171/2022.1.JNS2232>.
93. Hackenberg KAM, Algra A, Al-Shahi Salman R, et al. Definition and prioritization of data elements for cohort studies and clinical trials on patients with unruptured intracranial aneurysms: proposal of a multidisciplinary research group. *Neurocritical Care*. 2019;30:87-101.

Conflict of interest statement: The authors declare that the article content was composed in the absence of any commercial or financial relationships that could be construed as a potential conflict of interest.

Received 15 December 2023; accepted 19 January 2024

*Citation: World Neurosurg. (2024) 185:3-25.
<https://doi.org/10.1016/j.wneu.2024.01.108>*

Journal homepage: www.journals.elsevier.com/world-neurosurgery

Available online: www.sciencedirect.com

1878-8750/© 2024 The Author(s). Published by Elsevier Inc. This is an open access article under the CC BY license (<http://creativecommons.org/licenses/by/4.0/>).