

## Central Lancashire Online Knowledge (CLoK)

Title	Analysis of Artefacts in Endodontically Treated Teeth on Cone Beam Computed (CBCT) Images and their Impact on Diagnostic Value
Type	Article
URL	<a href="https://clock.uclan.ac.uk/50787/">https://clock.uclan.ac.uk/50787/</a>
DOI	##doi##
Date	2024
Citation	Kanagasingam, Shalini, Mistry, Chetan D, Ahmed, Waqar orcid iconORCID: 0000-0003-4152-5172 and Barrak, Fadi N orcid iconORCID: 0000-0002-3906-9174 (2024) Analysis of Artefacts in Endodontically Treated Teeth on Cone Beam Computed (CBCT) Images and their Impact on Diagnostic Value. <i>Journal of Clinical &amp; Medical Surgery</i> , 4 . ISSN 2833-5465
Creators	Kanagasingam, Shalini, Mistry, Chetan D, Ahmed, Waqar and Barrak, Fadi N

It is advisable to refer to the publisher's version if you intend to cite from the work. ##doi##

For information about Research at UCLan please go to <http://www.uclan.ac.uk/research/>

All outputs in CLoK are protected by Intellectual Property Rights law, including Copyright law. Copyright, IPR and Moral Rights for the works on this site are retained by the individual authors and/or other copyright owners. Terms and conditions for use of this material are defined in the <http://clock.uclan.ac.uk/policies/>

Research Article

# Analysis of Artefacts in Endodontically Treated Teeth on Cone Beam Computed (CBCT) Images and their Impact on Diagnostic Value

Shalini Kanagasingam<sup>1</sup>; Chetan D Mistry<sup>1</sup>; Waqar Ahmed<sup>3</sup>; Fadi Barrak<sup>1,2\*</sup>

<sup>1</sup>School of Medicine & Dentistry, University of Central Lancashire, Preston, UK.

<sup>2</sup>VSS Academy, London, UK.

<sup>3</sup>School of Mathematics and Physics, College of Health and Science, University of Lincoln, UK.

\*Corresponding Author: **Fadi Barrak**

School of Medicine and Dentistry, University of  
Central Lancashire, UK.

Email: fnbarrak@uclan.ac.uk

## Article Information

Received: Dec 06, 2023

Accepted: Feb 02, 2024

Published: Feb 09, 2024

Archived: www.jclinmedsurgery.com

Copyright: © Barrak F (2024).

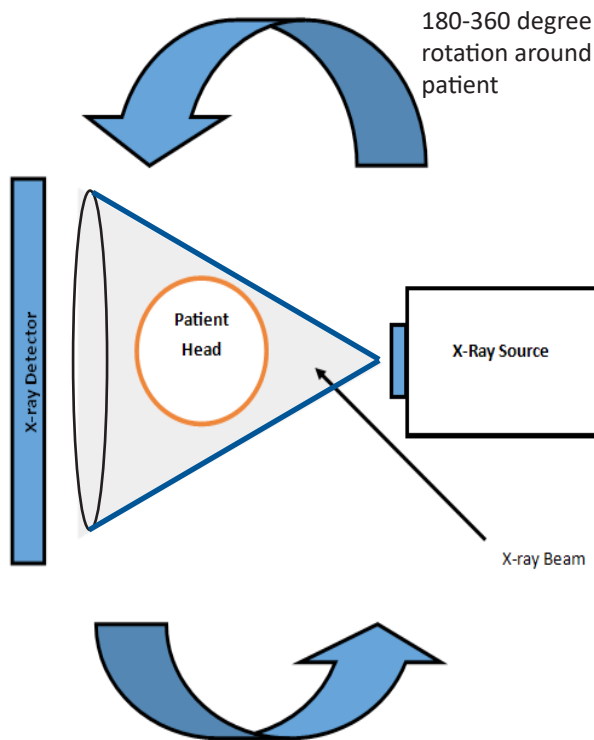
## Abstract

The aim of this paper was to investigate the incidence of artefacts produced by endodontically treated teeth on CBCT images and their impacts the diagnostic value of the image for endodontic purposes. A retrospective analysis of 57 root filled teeth from 40 CBCT scans from UCLAN dental clinic between 2016-2020 was undertaken. Each tooth was split into crown and root section with the incidence of all known artefacts recorded by the binary yes/no variable. Subjective assessment into the diagnostic acceptability of the image in relation to endodontic indications stated in the European Society of Endodontics guidance was done. Age, gender, field of view, tooth type, location, coronal restoration of subject tooth and adjacent teeth were recorded. Statistical analysis (SPSS v28, IBM system) was used to assess the relationship between study factors, artefact expression and the effects on diagnostic quality. Scatter artefacts were present in 100% of samples with Beam Hardening being present in 94.7% of samples. Image Noise, Motion and Aliasing (distortion) artefacts reported an incidence ranging between 0-17.5%. The significance level was set at  $p < 0.05$ . Of the study characteristics Beam Hardening was affected by tooth type/location, coronal restoration of subject tooth and adjacent tooth whereas Motion and Aliasing artefacts were affected by the number of roots and tooth type/location respectively. Beam Hardening, Image Noise, Motion and Aliasing artefacts were shown to have a statistically significant association with the diagnostic acceptability of the scans of root filled teeth for endodontic purposes especially in the axial and sagittal views. Beam Hardening had the most significant impact on diagnostic quality. This is the first study to show artefact expression is much more prevalent than previously reported and has strong ability to affect the diagnostic acceptability of CBCT scans of root filled teeth taken for endodontic purpose.

**Citation:** Kanagasingham S, Mistry CD, Ahmed W, Barrak F. Analysis of Artefacts in Endodontically Treated Teeth on Cone Beam Computed (CBCT) Images and their Impact on Diagnostic Value. *J Clin Med Surgery*. 2024; 4(1): 1136.

## Introduction

Radiographic imaging is crucial in endodontics, aiding in diagnosis, treatment planning, and assessing treatment outcomes [1]. While two-dimensional radiographs are commonly used for imaging dentoalveolar structures, they have limitations like geometric distortion and superimposition [2,3]. In the late 20<sup>th</sup> Century, Cone Beam Computed Tomography (CBCT) was introduced for dental implant planning, and advancements in image quality, reduced dosage, and cost have expanded its use into endodontics, as endorsed by the European Society of Endodontology and the American Association of Endodontists [4]; '(AAE and AAOMR Issue Position Statement on 3-D Imaging in Endodontics', 2015). CBCT machines, a Modification of Multi-Slice Computed Tomography (MSCT), generate images differently than conventional two-dimensional radiography. They use a single x-ray beam that diverges like a cone around a specific area (Figure 1).



**Figure 1:** Diagrammatic view of conical shaped beam produced by CBCT.

Complex computer algorithms then reconstruct a detailed three-dimensional image from the data received on the image receptor [5]. Clinicians benefit from the ability to view these images in multiple planes without superimposition, with slices as thin as 0.5 mm, providing valuable advantages [6]. Regarding radiation exposure, CBCT carries an average effective dose 95% lower than MSCT imagery. Dosage can range from as low as 2  $\mu$ Sv to 200  $\mu$ Sv, depending on the justification for exposure [4]. The average small-volume CBCT presents an effective dose of 50  $\mu$ Sv, 50 times that of a single periapical radiograph. Recent literature underscores CBCT's benefits in endodontics, such as early detection of apical pathology compared to conventional two-dimensional radiographs [7,8]. Clinical studies reveal CBCT makes apical pathology detection twice as likely, a finding supported by histopathology reference standards. Early detection implies improved outcomes, as suggested by Ng et al.'s system-

atic review in 2008. Additionally, CBCT aids in refining case selection for pulpal preservation procedures, especially in cases of deep carious lesions with pulpal exposure, where the absence of periapical pathosis is crucial for successful outcomes. CBCT significantly transforms the management of endodontic cases compared to conventional radiography, particularly in already root-filled teeth, by enabling the detection of missed anatomy, root fractures, and a more precise assessment of periapical lesion extent [6]. Despite these advancements, the subsequent impact on endodontic outcomes remains unidentified. The increased usage of CBCT among endodontists, as evidenced by a recent survey reporting a 91.8% adoption rate, underscores its growing popularity [9]. However, despite CBCT's recognized benefits like high spatial resolution and reduced anatomical noise, there is a widespread acknowledgment that reconstructed images are more susceptible to artefact production, potentially affecting diagnostic quality and utility [10]. Notably, the presence of artefacts has been suggested to pose a more severe risk of misdiagnosis rather than leading to under or over-diagnosis [6]. Artefacts in CBCT images denote inconsistencies between the reconstructed image and the actual object attenuation [11]. These artefacts can be broadly classified into unit-related, patient-related, and beam-related categories (Table 1).

**Table 1:** Types of artefacts and their definition.

Artefact	Definition	Category
Beam Hardening	Hypodense streaks, halos, and cupping	Beam Related
Scatter	Hyperdense streaks and cupping	Beam Related
Image Noise	Unwanted randomly/non-randomly distributed disturbance of the image giving it a grainy appearance	Beam Related
Motion	Blurring of image and anatomical structures	Patient Related
Ring	Concentric rings mainly visible in the axial plane around the centre of rotation	Unit Related
Aliasing	Moiré pattern at the periphery of the image.	Unit Related

Given this understanding and the heightened health risks associated with larger radiation doses, it becomes imperative for clinicians to justify exposures judiciously. An in-depth comprehension of CBCT limitations is crucial, ensuring the selection of the most appropriate radiographic examination while upholding the ALARP (as low as reasonably practicable) legislative principle [5,12]. To gauge the potential scope of the issue, we conducted a comprehensive literature review by performing an extensive search on the MEDLINE database using the terms for FIELD 1: Cone Beam Computed Tomography or CBCT; FIELD 2: Artefact or Artifact; and FIELD 3: Dentistry or Dental.

MEDLINE was selected for its status as one of the most comprehensive health electronic databases, minimizing the risk of overlooking pertinent publications. The search yielded 297 papers, from which those referencing artefact incidence and diagnostic quality were incorporated into data extraction tables, encompassing both laboratory and clinical studies. The adoption of these inclusive criteria stemmed from the scarcity of relevant papers, constraining the application of stricter selection parameters. For clarity, one table addresses artefact incidence, while the other delves into the effects of artefacts on diagnostic

quality. Considering the inaugural use of CBCT in 1998 [13], all identified articles were deemed contemporaneous. The scrutiny of the literature exposed a dearth of well-conducted clinical research on artefact production incidence and its impact on diagnostic image quality. The limited evidence predominantly centres on two specific artefacts, beam hardening and motion-related artefacts, with minimal attention to others. Regarding incidence, only two publications using *in vivo* methodology were identified. Both focused on motion artefacts, with one presenting a literature review and the other conducting a prospective study utilizing gold standard motion detection methodology to assess artefact expression [14,15]. The methodologies employed in these two studies stood out as the most rigorous in terms of both data capture and analysis, as highlighted in this review. In contrast, other studies utilized dry mandibles with laboratory-based methodologies to examine beam hardening artefact expression [16], a context that may not perfectly align with clinical situations. From the literature search, only one clinical study addressing the impact of artefacts on diagnostic quality emerged. This study employed a subjective analogue scale to evaluate how age, body mass index, implants, and other restorations affected the visualization of anatomical structures. While the authors asserted that artefacts did not compromise the ability to visualize anatomical structures, they did acknowledge a reduction in the diagnostic quality of the images [17]. In the realm of endodontics and implantology, three laboratory-based studies were identified. Two of these studies employed similar methodologies to assess artefacts' effects on detecting external root resorption or vertical root fractures [18,19]. The authors concluded that artefact expression, intensity, and location did not impede the detection of external root resorption but adversely impacted the ability to detect vertical root fractures, with an elevated risk of false positives closer to the suspected fracture site [19]. The third study, loosely tied to diagnostic quality, examined whether metal artefact reduction algorithms improved the visualization of anatomical structures with implants. Surprisingly, the authors found that these algorithms adversely affected the ability to locate those structures. The methodologies across the reviewed studies varied significantly, employing both subjective and objective analyses. Additionally, the evaluation conditions for CBCT images differed, with only a subset adhering to SEDENTEXCT guidelines for optimal viewing and dose optimization (2012). This raises concerns about the validity and relevance of the results obtained. Most studies were conducted *in vitro*, questioning whether these methodologies truly mirror clinical situations, where factors like motion and soft tissue may influence beam behaviour and attenuation. Although proposed subjective artefact assessment as the most practical given the current subjectivity in clinical radiographic interpretation, emphasizing the need for a subjective retrospective study. This approach offers a more coherent evaluation of artefact incidence and impact on diagnostic quality within the same dataset, specifically from an endodontic perspective. The study aimed to investigate artefact incidence from endodontically treated teeth on CBCT images and its consequential impact on diagnostic value.

### Materials and methods

To assess the occurrence of artefacts resulting from endodontically treated teeth on CBCT scans and their impact on endodontic diagnosis, a subjective retrospective analysis was conducted at the University of Central Lancashire (UCLAN) Dental Clinic, spearheaded by a single researcher. Given resource limitations, including self-funding constraints, the methodology

was tailored to meet the research objectives outlined earlier. This innovative approach is the first of its kind, allowing the recording of all known artefact types from a single sample dataset, facilitating inter-artefact type analysis to identify potential correlations. An overview of the methodology is presented in Figure 2. Ethical approval for the research was obtained from the UCLAN ethics committee following the HRA decision tool assessment. Since this is a retrospective analysis of images taken for justified clinical purposes, IRAS approval was deemed irrelevant. Patient consent for the clinic inherently encompasses the use of imagery for educational, marketing, and research purposes.

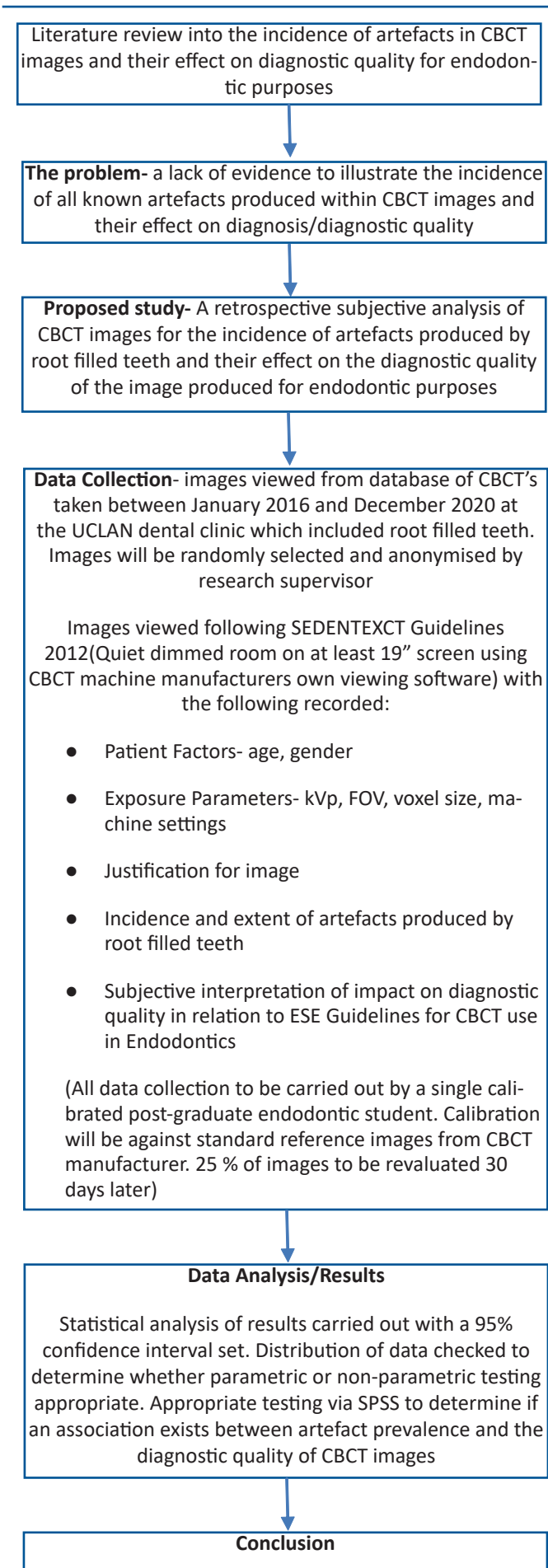
#### The inclusion criteria are summarised:

- CBCT images acquired at UCLAN Dental Clinic on Sirona Orthophos XG 3D from 2016 to December 2020.
- Scans must encompass at least one endodontically treated tooth.
- At least one tooth unit mesial and distal to the endodontically treated tooth should be visible in the scan to facilitate artefact extent determination.
- Images must be viewable from the imaging room at UCLAN Dental Clinic.
- Scans taken for clinical purposes.

#### The exclusion criteria are summarised:

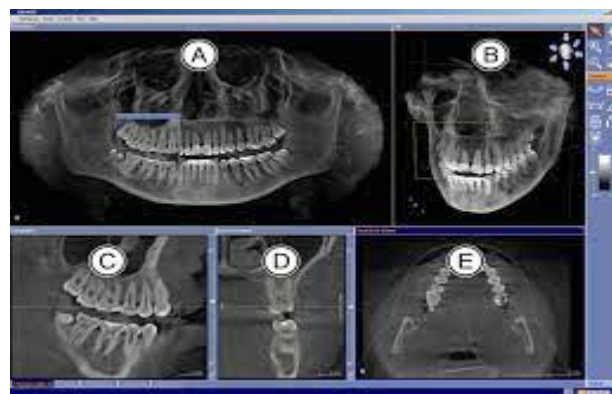
- Images captured on a different CBCT machine.
- Scans lacking at least one endodontically treated tooth.
- Scans where one tooth unit mesial or distal to the endodontically treated tooth is not visible.
- Images taken outside the dates specified in the inclusion criteria.

For sampling, images were selected randomly and anonymized by the research supervisor, utilizing a random number generator in Microsoft Excel. The researcher remained blinded to any patient-identifying data, while the research supervisor ensured each scan adhered to the previously discussed inclusion criteria for the study. Images were examined under optimal low-light conditions, employing a 19-inch monitor, and adhering to ideal viewing parameters outlined in the SEDENTEXCT Guidelines (2012). The researcher underwent calibration for all known artefacts (e.g., beam hardening, scatter, image noise, motion, ring, and aliasing artefacts) against the primary supervisor. In cases of disagreement, the secondary supervisor provided their opinion, and a consensus decision was reached. The reference standard for defining artefacts was derived from the current evidence base on CBCT artefacts [4,11]. Calibration involved a pilot study utilizing a data capture grid (refer to Figure 10), and a Cohen's Kappa calculation demonstrated a significant inter-observer co-efficient of 0.71. Intra-observer reliability was established through a subsequent pilot study, repeated a week later with another set of 10 scans under the same conditions as the main study. A Cohen's Kappa score of 0.95 indicated excellent intra-observer reliability. The researcher conducted data collection over one week, working in short periods with frequent breaks to prevent observer fatigue. To mitigate recall bias, the researcher returned after one month to reassess 10 CBCT images to ensure result accuracy and reliability. For data security, images were only viewable at the UCLAN Dental Clinic



**Figure 2:** Flowchart of study methodology.

via a password-protected computer, and the obtained data was stored on the principal investigator's password-protected folder on the University network. No sensitive information identifying patients or clinicians was recorded. To fulfil the study's aims and objectives, the researcher documented relevant information (refer to Figure 10) on a data capture grid in Microsoft Excel. Each image was viewed in the dental clinic imaging room under optimal low-light viewing conditions, following SEDENTXCT guidelines (2012). The CBCT images were observed using the proprietary viewing software, Sirona Galaxis Version 5, provided by the machine manufacturer. The MPR view was utilized, enabling the examination of the area of interest in three planes: axial, coronal, and sagittal (Figure 3).



**Figure 3:** A: Panoramic view; B: 3D view; C: Sagittal view; D: Coronal view; E: Axial view.

In this viewing configuration, each image underwent the following analysis to document the occurrence and impact of observed artefacts:

The researcher recorded general information, including gender, age, region of interest, purpose, image characteristics, and restorative profile of the teeth.

Each subject tooth was categorized into crown and root sections.

The relevant section of the tooth was systematically surveyed three times in each view-initially in the axial, followed by the coronal, and concluding with the sagittal view. Each sweep lasted approximately 10-15 seconds.

Following each view sweep, the researcher documented their findings in the data capture grid.

Upon completion of the assessment in all three views, the researcher progressed to the next section.

After a thorough assessment of artefacts for each tooth, the researcher provided a subjective overall evaluation on the data capture grid concerning diagnostic quality and the ability to identify conditions outlined by the ESE guidelines (2015) for CBCT usage in endodontics.

The sweeping approach for viewing the scan, adopted by the researcher, served to consolidate the numerous slices in a reconstructed CBCT image [5]. This motion mirrors how a clinician is likely to view the image, as the cumulative information from multiple slices is crucial for diagnosis and treatment planning.

**Rationale for the data capture grid:** The information recorded from each scan aligns with the study's aims and objectives. As the first comprehensive study of its kind to evaluate all known CBCT artefacts within a single data set, an occurrence-

based measurement was deemed the most suitable. The literature review exposed a lack of consensus between objective and subjective artefact measurements. Given the study's limited resources and [20] acknowledgment of the inherently subjective nature of radiographic analysis, the chosen capture grid and methodology were deemed the most accurate for meeting the study's objectives while maintaining clinical relevance in the profession.

**Table 2:** Study characteristics and variables.

Factor/Variable	Number of patients (n)	Patients (%)
Age Under 30	0	0
31-50	13	32.5
51 and over	27	67.5
Gender Male and Female	17 and 23	42.5 and 57.5
Field of View (cm) 5x5, 5x8, 8x8	19, 15 and 6	47.5, 37.5 and 15
Dose (kVp) 90, 95 and 120	19, 1 and 20	47.5, 2.5 and 50
Tooth Type Incisors	6	15
Canines	1	2.5
Premolars	12	30
Molars	21	52.5
Tooth Location Maxilla and Mandible	20 and 20	50 and 50
No. of Roots. 1, 2 and 3	19, 15 and 6	47.5, 37.5 and 15
Obturation Material. GP	40	100
Coronal Restoration on subject tooth		
Composite/GIC	7	17.5
Porcelain Bonded Crown	27	67.5
Feldspathic/Ceramic Crown	4	10
Ceramic Inlay/Onlay	1	2.5
Other	1	2.5
Post Present on Subject Tooth Y and N	10 and 30	25 and 75
Coronal Restoration on tooth mesial to subject tooth		
Amalgam	1	2.5
Composite/GIC	5	12.5
Porcelain Bonded Crown	7	17.5
Other	1	2.5
Unrestored	11	27.5
Tooth Absent	14	35
Denture Tooth	1	2.5
Coronal Restoration on tooth distal to subject tooth		
Amalgam	1	2.5
Composite/GIC	6	15
Porcelain Bonded Crown	5	12.5
Unrestored	7	17.5
Tooth Absent	20	50
Dental Implant	1	2.5

**Table 3:** Incidence of artefacts.

Diagnostic Acceptability		Number of teeth	% of teeth
Beam Hardening in the crown of the subject tooth	Yes	49	86
	No	8	14
Beam Hardening in the root of the subject tooth	Yes	54	94.7
	No	3	5.3
Scatter in the crown of the subject tooth	Yes	57	100
	No	0	0
Scatter in the root of the subject tooth	Yes	57	100
	No	0	0
Image Noise in the crown of the subject tooth	Yes	18	31.6
	No	39	68.4
Image Noise in the root of the subject tooth	Yes	18	31.6
	No	39	68.4
Motion artefact in the crown of the subject tooth	Yes	4	7
	No	53	93
Motion artefact in the root of the subject tooth	Yes	4	7
	No	53	93
Ring artefacts in the crown of the subject tooth	Yes	0	0
	No	57	100
Ring artefacts in the root of the subject tooth	Yes	0	0
	No	57	100
Aliasing artefacts in the crown of the tooth	Yes	10	17.5
	No	47	82.5
Aliasing artefacts in the root of the tooth	Yes	10	17.5
	No	47	82.5

### Controls

**Selection bias:** Scans meeting inclusion criteria were chosen using a random number generator in Microsoft Excel, and the primary researcher remained blinded to patient-identifying data to prevent participant bias.

**Measurement bias:** Due to the disagreement in the literature on the most appropriate artefact measurement, a simple occurrence-based measurement and subjective diagnostic impact assessment, proposed by [20], were adopted to minimize measurement bias. The simplicity of the measurement aims to reduce bias. Recall bias was minimized by repeating data collection on 10 scans a month after the initial capture to ensure good reliability.

**Optimized viewing conditions:** SEDENTXCT guidelines (2012) were adhered to.

**Standardized viewing protocol:** Each scan was viewed using a standardized protocol.

**Data analysis:** To fulfil the research objectives, the data underwent analysis using the statistical package SPSS version 28 by IBM systems, given the quantitative nature of the study. Before analysis, a missing value analysis was conducted to ensure accurate data input into SPSS, enhancing the reliability of subsequent statistical analyses.

### Results

The details of the study characteristics are given in (Table 2).

**Artefact incidence in CBCT scans:** Tables 3, 4 and 5 show incidence of artifacts, diagnostic acceptability of teeth, the inci-

**Table 5:** Influence of study characteristics on artefact incidence.

	Beam Hardening in the crown	Beam Hardening in the root	Scatter in the crown	Scatter in the root	Image Noise in the crown	Image Noise in the root	Motion artefact in the crown	Motion artefact in the root	Ring artefact in the crown	Ring artefact in the root	Aliasing artefact in the crown	Aliasing artefact in the root
Gender	0.102	0.158	a	a	0.975	0.975	0.627	0.627	a	a	0.92	0.92
Age	0.519	0.948	a	a	<b>0.005</b>	<b>0.005</b>	0.083	0.083	a	a	0.277	0.277
FOV	0.663	0.056	a	a	<b>0.01</b>	<b>0.01</b>	0.275	0.275	a	a	0.397	0.397
Tooth Type (Incisor/Canine/Premolar/Molar)	<b>0.015</b>	0.578	a	a	0.473	0.473	0.364	0.364	a	a	<b>0.039</b>	<b>0.039</b>
Tooth Location (Maxilla/Mandible)	<b>0.033</b>	0.617	a	a	0.787	0.787	0.863	0.863	a	a	<b>0.023</b>	<b>0.023</b>
No. of roots (single/multi rooted)	0.114	0.574	a	a	0.631	0.631	<b>0.042</b>	<b>0.042</b>	a	a	0.525	0.525
Subject Tooth Coronal Restoration	<b>0.01</b>	<b>0.01</b>	a	a	0.064	0.064	0.676	0.676	a	a	0.291	0.291
Coronal Restoration on adjacent mesial tooth	<b>0.03</b>	<b>0.004</b>	a	a	0.235	0.235	0.048	0.048	a	a	0.304	0.304
Coronal Restoration on adjacent distal tooth	<b>0.03</b>	0.264	a	a	0.162	0.162	0.84	0.84	a	a	0.73	0.73

**Table 4:** Incidence of artefacts.

Diagnostic Acceptability		Number of teeth	% of teeth
Root Fracture			
Axial	Yes	0	0
	No	57	100
Coronal	Yes	0	0
	No	57	100
Sagittal	Yes	1	1.8
	No	56	98.2
Detection of Periapical Pathology			
Axial	Yes	55	96.5
	No	2	3.5
Coronal	Yes	13	22.8
	No	44	77.2
Sagittal	Yes	56	98.2
	No	1	1.8
Detecting complex/missed anatomy			
Axial	Yes	8	14
	No	49	80
Coronal	Yes	0	0
	No	57	100
Sagittal	Yes	4	7
	No	53	93
Assessing Complex Trauma			
Axial	Yes	51	89.5
	No	6	10.5
Coronal	Yes	27	47.4
	No	30	52.6
Sagittal	Yes	53	93
	No	4	7
Detecting Root Resorption			
Axial	Yes	2	3.5
	No	55	96.5
Coronal	Yes	0	0
	No	57	100
Sagittal	Yes	2	3.5
	No	55	96.5
Axial	Yes	57	100
	No	0	0
Coronal	Yes	26	45.6
	No	31	54.4
Sagittal	Yes	40	100
	No	0	0

**Table 6a:** Incidence of artefacts.

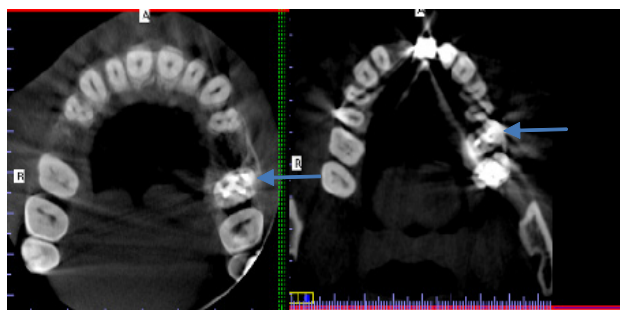
	Ability to diagnose root fracture			Ability to diagnose PA pathology			Ability to diagnose complex/missed anatomy		
	Axial	Coronal	Sagittal	Axial	Coronal	Sagittal	Axial	Coronal	Sagittal
Beam Hardening in the crown	a	A	0.684	<b>0.01</b>	0.454	<b>0.013</b>	0.893	a	0.402
Beam Hardening in the root	a	A	0.812	0.734	0.333	0.812	0.472	a	0.625
Scatter artefact in the crown	a	A	a	a	a	A	a	a	a
Scatter artefact in the root	a	A	a	a	a	A	a	a	a
Image Noise in the crown	a	A	0.138	0.568	<b>0.008</b>	0.493	0.698	a	0.053
Image Noise in the root	a	A	0.138	0.568	<b>0.008</b>	0.493	0.698	a	0.053
Motion artefact in the crown	a	A	0.782	0.692	0.179	0.782	<b>0.001</b>	a	<b>0.001</b>
Motion artefact in the root	a	A	0.782	0.692	0.179	0.782	<b>0.001</b>	a	<b>0.001</b>
Ring artefact in the crown	a	A	a	a	a	A	a	a	a
Ring artefact in the root	a	A	a	a	a	A	a	a	a
Aliasing artefact in the crown	a	A	0.642	0.219	0.058	0.642	0.159	a	0.339
Aliasing artefact in the root	a	A	0.642	0.219	0.058	0.642	0.159	a	0.339

a. Where chi square statistical analysis not possible due to one variable being constant.

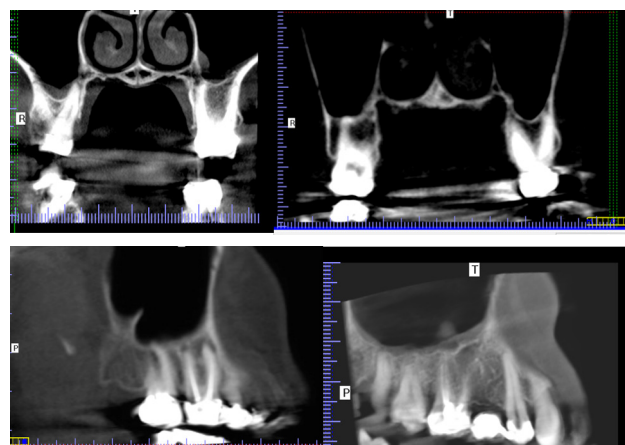
**Table 6b:** Incidence of artefacts.

	Ability to diagnose complex trauma			Ability to diagnose root resorption			Suitable for pre surgical assessment		
	Axial	Coronal	Sagittal	Axial	Coronal	Sagittal	Axial	Coronal	Sagittal
Beam Hardening in the crown	0.15	0.172	<b>0.032</b>	0.561	A	0.561	a	0.207	a
Beam Hardening in the root	0.542	0.617	0.625	0.734	A	0.734	a	0.661	a
Scatter artefact in the crown	a	A	a	a	A	a	a	a	a
Scatter artefact in the root	a	A	a	a	A	a	a	a	a
Image Noise in the crown	0.406	0.158	0.769	0.328	A	0.328	a	0.111	a
Image Noise in the root	0.406	0.158	0.769	0.328	A	0.328	a	0.111	a
Motion artefact in the crown	0.477	0.251	0.569	0.692	A	0.692	a	0.221	a
Motion artefact in the root	0.477	0.251	0.569	0.692	A	0.692	a	0.221	a
Ring artefact in the crown	a	A	a	a	A	a	a	a	a
Ring artefact in the root	a	A	a	a	A	a	a	a	a
Aliasing artefact in the crown	<b>0.001</b>	<b>0.009</b>	<b>0.002</b>	0.507	A	0.507	a	<b>0.013</b>	a
Aliasing artefact in the root	<b>0.001</b>	<b>0.009</b>	<b>0.002</b>	0.507	A	0.507	a	<b>0.013</b>	a

b. Where chi square statistical analysis not possible due to one variable being constant.



**Figure 4:** Axial sections from data showing Beam Hardening and Scatter on tooth. In both images UL6 (blue arrow) is the subject tooth. Second shows the influence of the adjacent tooth.



**Figure 5:** showing examples of extreme scatter in the coronal view



dence of artifacts and their dependence on the study characteristics. The study found a 100% incidence of scatter across all 57 subject teeth, irrespective of tooth type, field of view, dose, location, and coronal restoration. This precluded statistical analysis for scatter. Ring artefacts were absent in all 57 scans, making statistical analysis impossible for this variable as well. Beam hardening artefacts exhibited the next highest incidence in the dataset, with prevalence rates of 86% in the crown region and 94.7% in the root region of the subject tooth (Figures 4 and 5). Chi-squared analysis, with a significance level set at 95%, suggested potential associations between crown beam hardening and tooth type, location, coronal restoration type, and adjacent teeth (Table 4). Conversely, root beam hardening appeared influenced by the coronal restoration of the subject tooth and its mesial neighbour. Image Noise, Motion, and Aliasing artefacts reported incidences of 31.6%, 7%, and 14%, respectively, with no significant difference between crown and root regions. Chi-squared analysis indicated associations between Image Noise and age, as well as field of view. Motion artefacts were linked to whether the tooth was single or multi-rooted, while Aliasing artefacts showed associations with tooth type and location.

**Influence of artefacts on diagnostic acceptability in CBCT scans for endodontic purposes:** Tables 6a and 6b outlines the diagnostic acceptability of CBCT scans for endodontic purposes, ranging from 45.6% to 100% depending on the view and the purpose (detecting periapical pathology, assessing complex trauma, and pre-endodontic surgery assessment). Conversely, only up to 14% of CBCT scans were deemed acceptable when exposure justification aimed to detect root resorption, root fracture, and complex or missed anatomy. Statistical analysis revealed associations between crown beam hardening and the ability to diagnose periapical pathology in axial and sagittal views, as well as an influence on diagnosing complex trauma in the sagittal view. Image Noise presence was associated with the ability to detect periapical pathology in the coronal view. Motion artefacts were linked to visualising and detecting complex anatomy in axial and sagittal views. Scatter and ring artefacts did not allow for diagnostic acceptability analysis, as they were consistently present.

## Discussion

The widespread adoption of CBCT in endodontics, as underscored by recent reviews [4], position statements [1], and studies [6], has significantly altered the diagnosis and treatment planning, particularly for root-filled teeth, when compared to conventional 2D radiography. However, the potential benefits of CBCT are accompanied by the acknowledged susceptibility of its reconstructed images to artefacts [21,22]. This study addresses a notable gap in the literature by being the first to investigate the in vivo prevalence of artefacts on CBCT images and their impact on diagnostic quality. While scatter artefacts exhibited a 100% incidence on all subject teeth, beam hardening followed closely, being present in 86-94.7% of cases. This contrasts with a prior in vitro study [16], which reported lower artefact prevalence. Notably, this study's design better reflects real-world scenarios with diverse tooth restorations. The high incidence of beam hardening was associated with tooth type, location, and the restorative status of both the subject tooth and adjacent teeth. Recommendations for improving diagnostic quality include considering the removal of highly radiopaque materials before imaging, as they contribute to increased beam hardening and scatter artefacts. While some studies suggested factors like body mass index, age, and dosage influenced diagnostic quality

[19,17], further research is needed for comprehensive understanding. Motion artefacts, while showing a lower incidence of 7%, were associated with the number of roots, impacting the ability to detect complex or missed anatomy. This emphasizes the importance of head stability during exposure, a recognized risk factor for motion artefacts [14]. Unit-related artefacts like image noise, ring, and aliasing exhibited a 0-17.5% incidence with associations noted with study characteristics such as age, field of view, and tooth type/location. Image noise and aliasing artefacts impacted the ability to diagnose apical pathology and detect complex trauma, respectively. Proper unit maintenance was stressed to prevent these artefacts [11]. While some novel techniques, like manipulating soft tissue to reduce artefact expression, have been proposed [23], the limited evidence underscores the need for further research. Policymakers and clinicians should consider alternative measures to enhance CBCT efficacy, particularly for endodontic purposes requiring detailed anatomical structure visualization. Study limitations include retrospective data derived from CBCT scans intended for dental implants, potentially influencing exposure parameters and artefact expression. The single-machine, subjective assessment of artefact presence through a dichotomous variable may oversimplify the situation, and future studies should explore more objective scales for greater nuance. Prospective studies, standardized measures, and multiple CBCT units are recommended for enhanced methodological strength and clinical relevance.

## Conclusion

In conclusion, this research has unravelled a spectrum of artefact prevalence, underscoring Beam Hardening and Scatter artefacts as the most prevalent culprits. Notably, their influence, alongside Image Noise, Motion, and Aliasing artefacts, extends to the diagnostic acceptability of endodontic images. A nuanced interplay of factors, from the coronal restoration of the subject tooth to the characteristics of adjacent teeth, tooth type, location, age, and field of view, intricately moulds the expression of these artefacts. Yet, acknowledging the constraints of limited resources and methodological nuances, this study calls for a resolute shift towards future research endeavours that are prospective, objective, and comprehensive. This imperative is not just about filling knowledge gaps but about fortifying the foundations upon which we build guidelines for the judicious use of CBCT in the dynamic landscape of endodontics.

## References

1. Patel S, Brown J, Pimentel T, Kelly RD, Abella F and Durack C. Cone beam computed tomography in Endodontics - a review of the literature, *International endodontic journal*. 2019a; 52(8): 1138-1152. doi: 10.1111/iej.13115.
2. Huuononen S, Kvist T, Grondahl K and Molander A. Diagnostic value of computed tomography in re-treatment of root fillings in maxillary molars, *International endodontic journal*. 2006; 39(10): 827-833. doi: IEJ1157 [pii].
3. Patel S, Dawood A, Mannocci F, Wilson R and Pitt Ford T. Detection of periapical bone defects in human jaws using cone beam computed tomography and intraoral radiography, *International endodontic journal*. 2009; 42(6): 507-515. doi: 10.1111/j.1365-2591.2008.01538.x [doi].
4. Patel S, Harvey S, Shemesh H and Durack C. *Cone Beam Computed Tomography in Endodontics*. Berlin: Quintessenz Verlag. 2019.
5. Dawood A, Patel S and Brown J. Cone beam CT in dental practice, *British dental journal*. 2009; 207(1): 23-28. doi: 10.1038/

- sj.bdj.2009.560.
6. Bhatt M, Coil J, Chehroudi B, Esteves A, Aleksejuniene J, et al. Clinical decision-making and importance of the AAE/AAOMR position statement for CBCT examination in endodontic cases, *International endodontic journal*. 2021; 54(1): 26-37. doi: 10.1111/iej.13397.
  7. Patel S, Brown J, Semper M, Abella F, Mannocci F. European Society of Endodontology position statement: Use of cone beam computed tomography in Endodontics: European Society of Endodontology (ESE) developed by, *International endodontic journal*. 2019b; 52(12): 1675-1678. doi: 10.1111/iej.13187.
  8. Patel S, Wilson R, Dawood A, Mannocci F. The detection of periapical pathosis using periapical radiography and cone beam computed tomography - Part 1: pre-operative status, *International endodontic journal*. 2012; 45(8): 702-710. doi: 10.1111/j.1365-2591.2011.01989.x.
  9. Setzer FC, Hinckley N, Kohli MR, Karabucak B. A Survey of Cone-beam Computed Tomographic Use among Endodontic Practitioners in the United States, *Journal of endodontics*. 2017; 43(5): 699-704. doi: 10.1016/j.joen.2016.12.021.
  10. Spin-Neto R, Mudrak J, Matzen LH, Christensen J, Gotfredsen E, et al. Cone beam CT image artefacts related to head motion simulated by a robot skull: Visual characteristics and impact on image quality Wiley-Blackwell 2013.
  11. Nagarajappa AK, Dwivedi N, Tiwari R. *Artifacts: The downturn of CBCT image* Wolters Kluwer India Pvt Ltd. 2015.
  12. SEDENTEXCT Guideline Development Panel Cone Beam CT for Dental and Maxillofacial Radiology (Evidence Based Guidelines). European Commission: Directorate-General for Energy, Luxembourg. 2012. <http://www.manchester.ac.uk/escholar/uk-ac-man-scw:168864> (Accessed).
  13. Mozzo P, Procacci C, Tacconi A, Martini PT, Andreis IA. A new volumetric CT machine for dental imaging based on the cone-beam technique: Preliminary results, *European radiology*. 1998b; 8(9): 1558-1564. doi: 10.1007/s003300050586 [doi].
  14. Spin-Neto R and Wenzel A. Patient movement and motion artefacts in cone beam computed tomography of the dentomaxillofacial region: a systematic literature review. 2016.
  15. Spin-Neto R, Costa C, Salgado, Daniela M R A, Zambrana NRM, Gotfredsen E and Wenzel A. Patient movement characteristics and the impact on CBCT image quality and interpretability, *Dentomaxillofacial Radiology*. 2018; 47(1): 1-8. doi: 10.1259/dmfr.20170216.
  16. Vasconcelos KF, Nicolielo LFP, Nascimento MC, Haiter-Neto F, Bóscolo FN, et al. Artefact expression associated with several cone-beam computed tomographic machines when imaging root filled teeth Wiley-Blackwell. 2015.
  17. Ritter L, Mischkowski RA, Neugebauer J, Dreiseidler T, Scheer M, et al. The influence of body mass index, age, implants, and dental restorations on image quality of cone beam computed tomography. 2009.
  18. Freitas DQ, Nascimento EHL, Vasconcelos TV, Noujeim M. Diagnosis of external root resorption in teeth close and distant to zirconium implants: influence of acquisition parameters and artefacts produced during cone beam computed tomography, *International endodontic journal*. 2019; 52(6): 866-873. doi: 10.1111/iej.13065.
  19. Freitas DQ, Vasconcelos TV, Noujeim M. Diagnosis of vertical root fracture in teeth close and distant to implant: An in vitro study to assess the influence of artifacts produced in cone beam computed tomography Springer Nature. 2019.
  20. Pauwels R, Stamatakis H, Bosman H, Bogaerts R, Jacobs R, et al. Quantification of metal artifacts on cone beam computed tomography images Wiley-Blackwell. 2013.
  21. Schulze R, Heil U, Gross D, Bruellmann DD, Dranischnikow E, et al. A review, England: British Institute of Radiology. 2011.
  22. Makins SR. *Artifacts interfering with interpretation of cone beam computed tomography images*, United States: Elsevier-Health Sciences Division. 2014.
  23. Safi Y, Fazlyab M, Asgary S, Fazlalipour M. A Novel Technique for Minimizing the Metal Artifacts on Anterior Teeth in Cone-Beam Computed Tomography, *Iranian Endodontic Journal*. 2019; 14(1): 79-83. doi: 10.22037/iej.v14i1.21636.