

Central Lancashire Online Knowledge (CLoK)

Title	Tanning Melanotan Jabs and Nasal Spray: Safe or Not?
Type	Article
URL	https://clock.uclan.ac.uk/50789/
DOI	##doi##
Date	2024
Citation	Al Abadie, Mohammed, Sharara, Zinah and Veetil, Jayaprabha Puthan (2024) Tanning Melanotan Jabs and Nasal Spray: Safe or Not? Medical & Clinical Research . ISSN 2577-8005
Creators	Al Abadie, Mohammed, Sharara, Zinah and Veetil, Jayaprabha Puthan

It is advisable to refer to the publisher's version if you intend to cite from the work. ##doi##

For information about Research at UCLan please go to <http://www.uclan.ac.uk/research/>

All outputs in CLoK are protected by Intellectual Property Rights law, including Copyright law. Copyright, IPR and Moral Rights for the works on this site are retained by the individual authors and/or other copyright owners. Terms and conditions for use of this material are defined in the <http://clock.uclan.ac.uk/policies/>

Tanning Melanotan Jabs and Nasal Spray: Safe or Not?

Mohammed Al Abadie^{1*}, Zinah Sharara², Jayaprabha Puthan Veetil³

¹Clinical Director & Consultant Dermatologist, North Cumbria Integrated Care NHS Foundation Trust, UCLAN Medical School, United Kingdom.

²National Health Service (NHS), Community Dermatology Clinics (Health Harmonie), United Kingdom.

³Department of Histopathology, Royal Shrewsbury Hospital, United Kingdom.

*Corresponding Author

Professor Mohammed Al Abadie PhD, FRCP, Department of Dermatology, North Cumbria Integrated NHS Care Foundation, United Kingdom.

Submitted: 28 Jan 2024; Accepted: 06 Feb 2024; Published: 15 Feb 2024

Citation: Al Abadie M, Sharara Z, Puthan Veetil J (2024) Tanning Melanotan Jabs and Nasal Spray: Safe or Not?. Medical & Clinical Research, 9(2), 01-08.

Abstract

Cultural values among young population are focused on the concept of skin tanning as a perception of health and attractiveness. This has populated the development of using synthetic tanning agents especially with the advertisement coming from the social media. Synthetic tanning agents in forms of nasal spray or injections have gained publicity of use within society through the web and other uncontrolled sourcing routes. Warnings have been issued by UK Medicines and Healthcare products Regulatory Agency, and Irish Medicines Board against the use of subcutaneous injections labelled as Melanotan, after the upsurge in consuming tanning injections that has noticed in recent years [1].

Keywords: Melanotan, Tanning Injections, Tanning Nasal Spray, Dysplastic Naevi, Melanoma

Introduction

α -melanocyte-stimulating hormone (α -MSH) is a melanotropic peptide produced by many cell types, involving keratinocytes. It targets the melanocortin 1 receptor, which will enhance melanogenesis and DNA repair in melanocytes, and contribute to the regulation of melanin biosynthesis and pigmentation [2]. This is associated with increasing the expression of numerous enzymes such as tyrosinase and dopachrome tautomerase [3]. The synthetic analogues of α -MSH have more stability and potency reaching up to 1000 times more than the natural cytokine form.

Afamelanotide (formerly known as Melanotan I) is the first synthesised α -MSH analogue, it has been widely investigated and due to its role in activation of eumelanogenesis without exposure to UV radiation [4], Afamelanotide (Scenesse®) was approved by the European Medicines Agency, and the Food and Drug Administration (FDA) thereafter for the prevention of phototoxicity in adult patients with Erythropoietic protoporphyria (EPP) [5]. On the other hand, Melanotan I and Melanotan II are the other unregulated, non-licensed synthetic peptide analogues which stimulates tanning without the exposure to UV radiation, sold in the form of powder for injection and as a nasal spray. Sourcing of these products mainly retailed through websites by unregulated vendors who claim that the product's structure is as the originally manufactured peptide [1], those peptides are promoted as having

the advantages of increasing libido, weight loss and protecting from harsh effect of the ultraviolet rays. In fact both Melanotan I and II show wider side effect profile including erection dysfunction, nausea, loss of appetite and fatigue [6].

The third available analogue of α -MSH is Bremelanotide (Vyleesi®) has been specifically designed for sexual stimulation, and has recently approved in the USA for the management of premenopausal women with acquired, generalized hypoactive sexual desire disorder [7].

Case Report

A white female with Caucasian ethnicity, who is a 28-year-old was referred urgently to the dermatology cancer Clinic at Shrewsbury for rapidly growing new onset dark, irregularly shaped moles. The concern was raised as she has undergone frequent sunbed since the age of 18, and her mother had a history of Melanoma. Six months prior to this, the patient had started applying Melanotan nasal spray and injecting herself in the subcutaneous area of the abdomen and thighs with an α -MSH analogue on a daily basis for 6 months. Few weeks after starting treatment, she noticed new moles on her back as well as darkening of the pre-existing naevi starting to become irregular, prompting her to consult her General practitioner. She did not report any other adverse effects, as she used to inject before bedtime.

There was no personal history of skin cancer. Her past medical history was unremarkable and she was not taking any prescription medication apart from mirtazapine. Patient was advised to discontinue Melanotan self-administration via both nasal and injection routes.

On examination there are scattered darkly pigmented naevi on her upper back, 2 of which are raised, blackish, ranging between 0.4 to 0.8 cm in diameter and other 3 macular smaller pigmented lesion darker than average figure (1). The rest of her skin examination was showing scattered melanocytic naevi, most are new to her with background frank tanning.

All suspicious moles were excised with a 2-3 mm margin, Histopathologic findings of 4 Lesions revealed mildly dysplastic melanocytic junctional naevi (appendix-1) while 3 other new naevi were: compound melanocytic with focal architectural junctional abnormalities, no cytological atypia seen.

The patient is due to have regular follow-up visits and one year after initial presentation, she continued to develop new dark moles even after 1 year of Melanotan injection, these are scattered on face, neck, trunk and thigh (Figure 2).

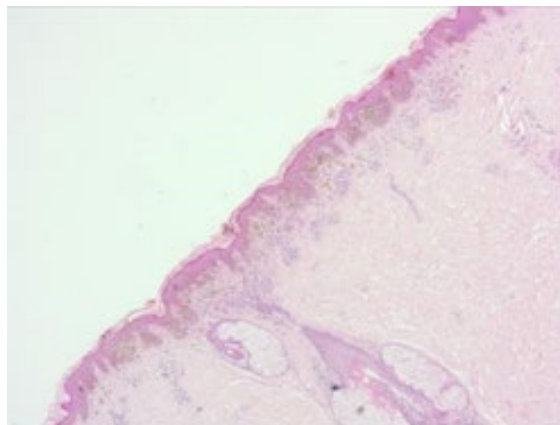


Figure 1: Scattered darkly pigmented naevi on her upper back.

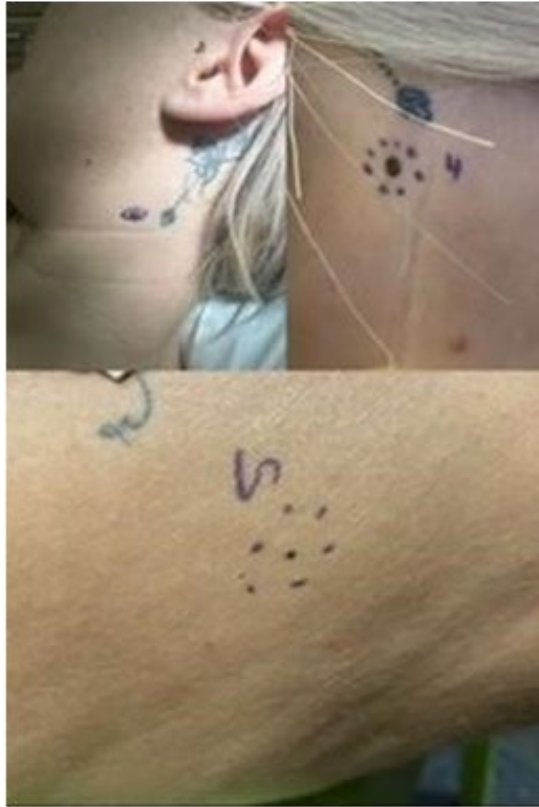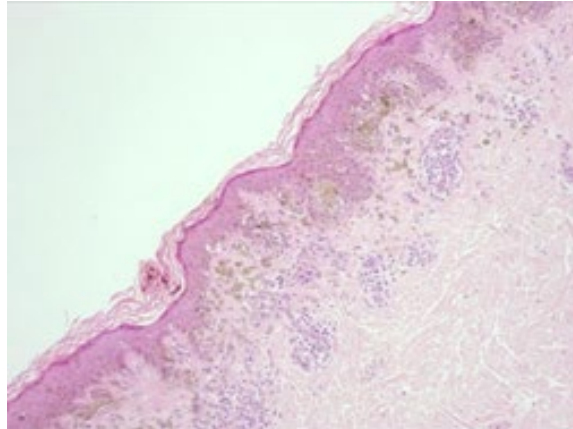


Figure 2: New dark moles even after 1 year of Melanotan injection, these are scattered on face, neck, trunk and thigh.

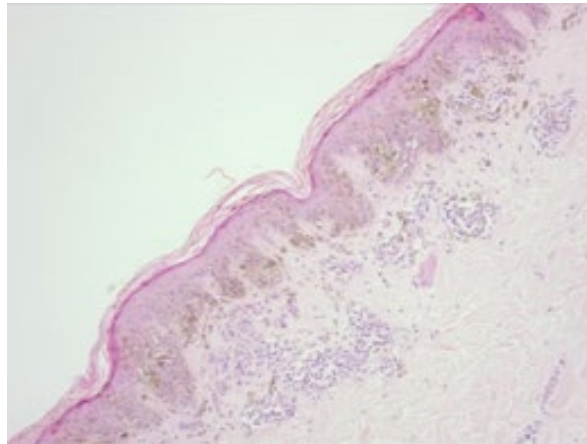
Appendix 1: Histopathology images



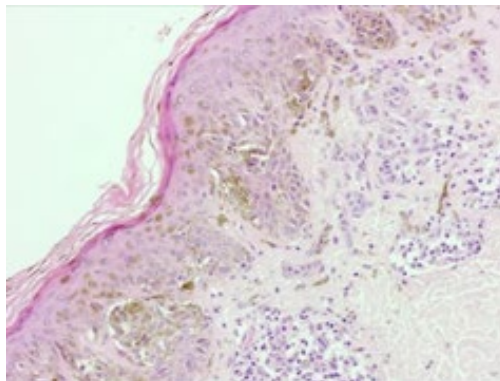
A: X4The skin includes an atypical compound melanocytic proliferation composed of lentiginous and nested atypical melanocytes.



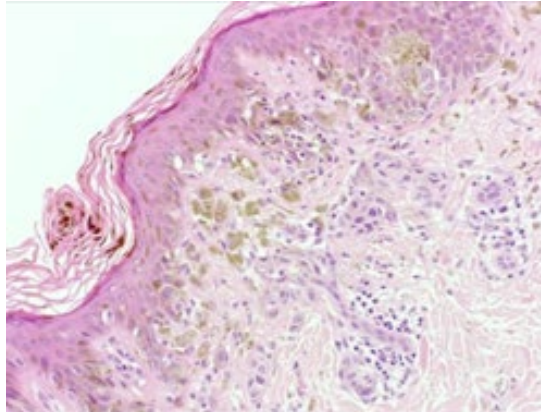
B: X10 The skin includes an atypical compound melanocytic proliferation composed of lentiginous and nested atypical melanocytes. There is architectural disorder with bridging of junctional nests of adjacent rete ridges and accompanying lamellar fibroplasia.



C: X10 The skin includes atypical compound melanocytic proliferation composed of lentiginous and nested atypical melanocytes. There is architectural disorder with bridging of junctional nests of adjacent rete ridges and accompanying lamellar fibroplasia.



D: X20 At higher magnification there is random cytological atypia predominantly in the junctional component, but to a lesser degree in the dermal component. Mitotic figures are not conspicuous and there is no pagetoid melanocytosis. There is accompanying melanin pigmentation. The dermal component shows some superficial cytological atypia but matures with depth.



E: X20 At higher magnification there is random cytological atypia predominantly in the junctional component, but to a lesser degree in the dermal component. Mitotic figures are not conspicuous and there is no pagetoid melanocytosis. There is accompanying melanin pigmentation. The dermal component shows some superficial cytological atypia but matures with depth.

Discussion

The development of synthetic α -MSH analogues has enhanced the study of melanocyte biological mechanisms and has prospective therapeutic applications [8].

The Melanotans are potent nonselective agonist of melanocortin receptors. The α -MSH and its analogues cause mitogenesis in human melanocytes [9]. They mimic the action of the melanocortin on the MC1 receptors of melanocytes leading to increased expression of eumelanin and consequently skin tanning. They have other physiological actions like enhancing sexual desire, loss of appetite and nausea.

Pubmed search was performed and shown that the α -MSH has been reported to induce eruptive nevi in susceptible patients [10-14] and melanoma in 3 patients [15-17]. Both patients with melanoma associated with Melanotan injection® have also reported darkening of many preexisting naevi following injection [15]. There is a sequential relationship between the event of injecting Melanotan® followed by the emergence of clinically and histologically atypical naevi and melanoma, this can highlight the carcinogenic potential of Melanotan, although the casual relationship was not suggested by the authors. Melanotan effect on the cells has been studied, it was concluded that MC1R is important in cellular genome maintenance pathways and recovering from UV damage by reducing free radical injury and augmenting antioxidant defence mechanisms in melanocytes, thus, α -MSH has tumour suppressor effects and it has proven to stimulate the melanocyte directly to increase dendricity and changing cell shape as well as the immunoregulatory effects, melanoma cells dendricity was also increased [18].

In addition, α -MSH is believed to impose a significant immunosuppressive effect, inhibiting tumor necrosis factor-induced intracellular adhesion molecule expression and nuclear factor- κ B activation in both melanocytes and melanoma cells [19,20] the α -MSH decreases T-cell-melanoma interaction in vitro [21], which act as pro-invasive and enables the neoplastic cells to evade immune surveillance [3, 22].

We have presented here a case report of eruptive benign melanocytic and dysplastic naevi after self-administration of Melanotan tanning products in the form of injection and nasal spray. There is an ongoing concern highlighted on the long-term risk of developing more dysplastic naevi or even developing melanoma in the pre-existing ones.

Conclusion

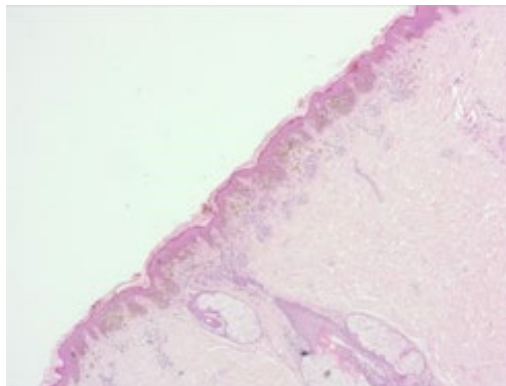
The young population are overwhelmed by the pursuit of appealing appearance, which has created social values that are based on the trend of image enhancement in a challenging manner for public health and wellbeing and drug policy. Synthetic tanning agents has gained publicity of use within western society through the web and other uncontrolled sourcing routes. Dermatologists should be aware of this trend and awareness should be raised to flag the potential long-term risk on health.

References

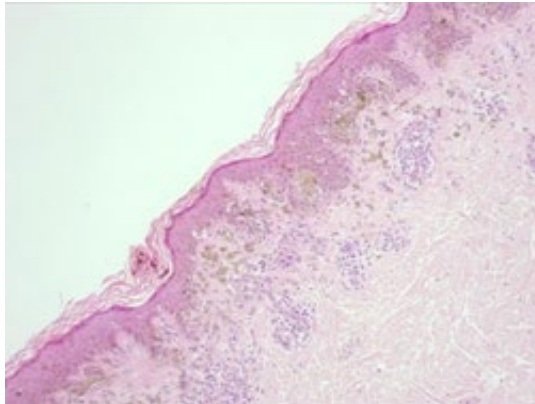
1. Evans-Brown M, Dawson RT, Chandler M, McVeigh J (2009) Use of melanotan I and II in the general population. *BMJ* 18:338.
2. Virador VM, Muller J, Wu X, Abdel-Malek ZA, Yu ZX, et al. (2002) Influence of α -melanocyte-stimulating hormone and of ultraviolet radiation on the transfer of melanosomes to keratinocytes. *The FASEB J* 16(1):1-27.
3. Wolf Horrell EM, Boulanger MC, D'Orazio JA (2016) Melanocortin 1 receptor: structure, function, and regulation. *Frontiers in Genetics* 7:95.
4. Sawyer TK, Sanfilippo PJ, Hruby VJ, Engel MH, Heward CB, et al. (1980) 4-Norleucine, 7-D-phenylalanine- α -melanocyte-stimulating hormone: a highly potent α -melanotropin with ultralong biological activity. *Proceedings of the National Academy of Sciences* 77(10):5754-5758.
5. Mullard A (2015) EMA recommended approval for 40 new drugs in 2014. *Nature Reviews Drug Discovery* 14(2):82-83.
6. Langan E, Rhodes LE (2011) Melanotropic peptides: what exactly is meant by "melanotan"? *Acta Dermato-Venereologica* 91(3):377-378.

7. Dhillon S, Keam SJ (2019) Bremelanotide: first approval. *Drugs* 79(14):1599-606.
8. Hadley ME, Dorr RT (2006) Melanocortin peptide therapeutics: historical milestones, clinical studies and commercialization. *Peptides* 27(4):921-30.
9. Scott G, Cassidy L, Abdel-Malek Z (1997) α -Melanocyte-Stimulating Hormone and Endothelin-Have Opposing Effects on Melanocyte Adhesion, Migration, and pp125FAK Phosphorylation. *Experimental Cell Research* 237(1):19-28.
10. Cardones AR, Grichnik JM (2009) α -Melanocyte-stimulating hormone-induced eruptive nevi. *Archives of Dermatology* 145(4):441-444.
11. Cousen P, Colver G, Helbling I (2009) Eruptive melanocytic naevi following melanotan injection. *British Journal of Dermatology* 161(3):707-708.
12. Van Hout MC, Brennan R (2014) An in-depth case examination of an exotic dancer's experience of melanotan. *International Journal of Drug Policy* 25(3):444-50.
13. Langan EA, Ramlogan D, Jamieson LA, Rhodes LE (2009) Change in moles linked to use of unlicensed "sun tan jab". *Bmj* 28:338.
14. Reid C, Fitzgerald T, Fabre A, Kirby B (2013) Atypical melanocytic naevi following melanotan injection. *Ir Med J* 106(5):148-149.
15. Paurobally D, Jason F, Dezfoulian B, Nikkels AF (2011) Melanotan-associated melanoma. *British Journal of Dermatology* 164(6):1403-1405.
16. Ellis R, Kirkham N, Seukeran D (2009) Malignant melanoma in a user of melanotan I. *BMJ* 338:b566.
17. Ong S, Bowling J (2012) Melanotan-associated melanoma in situ. *Australasian Journal of Dermatology* 53(4):301-302.
18. Thody AJ (1999) α -MSH and the Regulation of Melanocyte Function. *Annals of the New York Academy of Sciences* 885(1):217-229.
19. Haycock JW, Rowe SJ, Cartledge S, Wyatt A, Ghanem G, et al. (2000) α -melanocyte-stimulating hormone reduces impact of proinflammatory cytokine and peroxide-generated oxidative stress on keratinocyte and melanoma cell lines. *Journal of Biological Chemistry*. 275(21):15629-15636.
20. Haycock JW, Wagner M, Mac Neil S, Morandini R, Ghanem G, et al. (1999) α -Melanocytostimulating hormone inhibits NF- κ B activation in human melanocytes and melanoma cells. *Journal of Investigative Dermatology* 113(4):560-566.
21. Hedley SJ, Murray A, Sisley K, Ghanem G, Morandini R, et al. (2000) α -Melanocyte stimulating hormone can reduce T-cell interaction with melanoma cells in vitro. *Melanoma Research* 10(4):323-330.
22. Eves PC, MacNeil S, Haycock JW (2006) α -Melanocyte stimulating hormone, inflammation and human melanoma. *Peptides* 27(2):444-452.

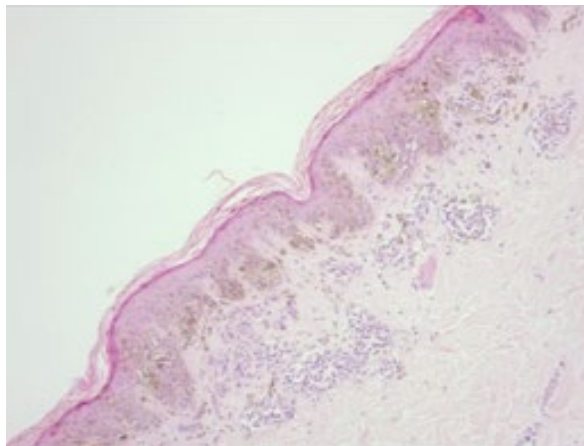
Appendix 1: Histopathology images



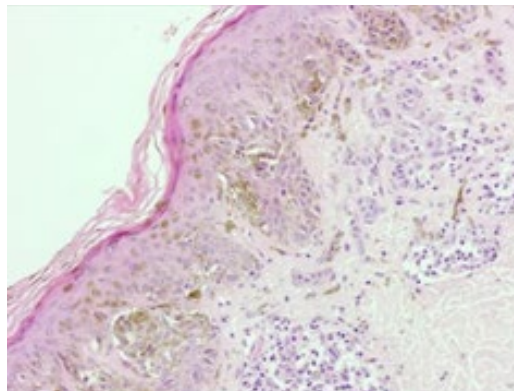
Error! Main Document Only: X4The skin includes an atypical compound melanocytic proliferation composed of lentiginous and nested atypical melanocytes.



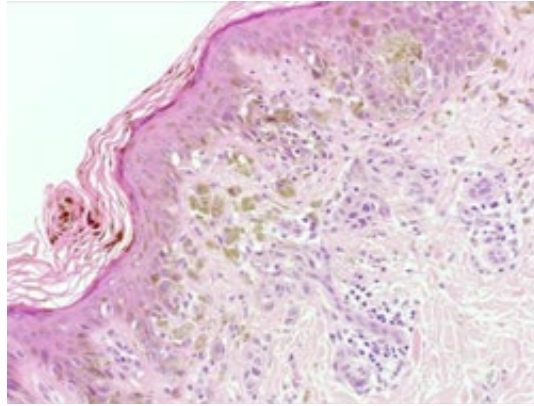
Error! Main Document Only: X10 The skin includes an atypical compound melanocytic proliferation composed of lentiginous and nested atypical melanocytes. There is architectural disorder with bridging of junctional nests of adjacent rete ridges and accompanying lamellar fibroplasia.



Error! Main Document Only: X10 The skin includes atypical compound melanocytic proliferation composed of lentiginous and nested atypical melanocytes. There is architectural disorder with bridging of junctional nests of adjacent rete ridges and accompanying lamellar fibroplasia



Error! Main Document Only: X20 At higher magnification there is random cytological atypia predominantly in the junctional component, but to a lesser degree in the dermal component. Mitotic figures are not conspicuous and there is no pagetoid melanocytosis. There is accompanying melanin pigmentation. The dermal component shows some superficial cytological atypia but matures with depth.



Error! Main Document Only: X20 At higher magnification there is random cytological atypia predominantly in the junctional component, but to a lesser degree in the dermal component. Mitotic figures are not conspicuous and there is no pagetoid melanocytosis. There is accompanying melanin pigmentation. The dermal component shows some superficial cytological atypia but matures with depth.

Copyright: ©2024 Mohammed Al Abadie, et al. This is an open-access article distributed under the terms of the Creative Commons Attribution License, which permits unrestricted use, distribution, and reproduction in any medium, provided the original authors and source are credited.