

Central Lancashire Online Knowledge (CLoK)

Title	Surgical Treatment of Vitiligo
Type	Article
URL	https://clock.uclan.ac.uk/51990/
DOI	##doi##
Date	2024
Citation	Hassan, Ahmed, Mohammed, Aya and Al Abadie, Mohammed (2024) Surgical Treatment of Vitiligo. International Journal of Clinical & Experimental Dermatology(IJCED), 9 (2). ISSN 2476-2415
Creators	Hassan, Ahmed, Mohammed, Aya and Al Abadie, Mohammed

It is advisable to refer to the publisher's version if you intend to cite from the work. ##doi##

For information about Research at UCLan please go to <http://www.uclan.ac.uk/research/>

All outputs in CLoK are protected by Intellectual Property Rights law, including Copyright law. Copyright, IPR and Moral Rights for the works on this site are retained by the individual authors and/or other copyright owners. Terms and conditions for use of this material are defined in the <http://clock.uclan.ac.uk/policies/>

Surgical Treatment of Vitiligo

Ahmed Hassan¹, Aya Mohammed² and Mohammed Al Abadie^{3*}

¹University hospital of Consultant vascular surgeon
Coventry and Warwickshire

²Speciality doctor in Dermatology, Milton Keynes
University hospitals, United Kingdom

³Clinical Director & Consultant Dermatologist, North
Cumbria integrated care NHS foundation trust, University
of Central Lancashire, UCLAN medical school, United
Kingdom

*Corresponding Author

Professor Mohammed Al Abadie, PhD, FRCP Department of Dermatology,
North Cumbria Integrated NHS Care Foundation, UCLAN Medical School,
United Kingdom, Email: mohammed.abadie@nhs.net

Submitted: 2024, Feb 05; Accepted: 2024, Mar 15; Published: 2024, Jun 13

Citation: Hassan, A., Mohammed, A., Al Abadie, M. (2024). Surgical treatment of vitiligo. *Int J Clin Expl Dermatol*, 9(2), 01-08.

Abstract

Vitiligo is an acquired, idiopathic disorder characterized by depigmented macules and patches with absence of functional melanocytes. Numerous treatment strategies exist, but lesions may be resistant to traditional therapies. Many treatments can help including topical including mainly topical steroids, calcineurine inhibitors and more recent biological therapy, ultraviolet light, laser including needling and surgical with various techniques. In this paper we highlight the various surgical techniques which can be helpful in the treatment of Vitiligo.

Keywords: Vitiligo, Epidermal Suction Blister Grafting, Tissue Graft

1. Introduction

Vitiligo is a dermatological condition characterized by pigment irregularities affecting both the skin and mucous membranes. Clinically, it presents as well-defined white patches of varying shapes and sizes, indicating a reduced number of melanocytes. Due to its significant impact on appearance, several non-invasive treatments are available to manage this condition. However, when these methods prove ineffective, surgery becomes a viable option, particularly for stable yet challenging-to-treat cases. The continuous development of new techniques and alterations to existing cell and tissue transplantation treatments offer hope to numerous patients globally. The effectiveness of each method relies on its appropriate selection based on the specific lesions being treated. Every surgical intervention in vitiligo treatment has its own set of advantages and disadvantages. These factors, coupled with considerations like the location or size of the treated hypopigmentation area, require careful analysis by a physician in consultation with their patient. This article provides an overview of the current surgical treatment methods for vitiligo, comparing their respective merits and demerits [1].

2. Dermatosurgery

In the past few decades, there has been significant progress in the development of new innovative methods and various modifications to existing techniques used in surgically treating vitiligo. Two primary surgical methods stand out in vitiligo treatment: one involves tissue grafts, while the other revolves around cellular grafts. The approach using tissue grafts entails

harvesting a segment of skin from an area of the body with normal pigmentation. This skin fragment is then transferred directly, without any additional processing with chemical reagents or enzymes, to a previously prepared recipient site. Dermabraders, various types of lasers (such as fractional CO₂, ablative CO₂, or Erbium YAG), micro-needling, and suction blistering are among the tools that can be utilized for this purpose [2].

Typically, the donor site selected for skin harvesting in vitiligo surgery is not readily visible or exposed to sunlight. Common locations for obtaining harvested skin include the inner side of the thighs, buttocks, back, or the postauricular area (behind the ear), especially if the treatment region involves facial areas. These sites are chosen to minimize visible scarring or alterations to the patient's appearance [31].

Cell transplants in vitiligo treatment require a processing step to transform the cells obtained, enabling their use as graft material applied to the affected area. Dermatosurgery is often considered most effective, particularly in cases of segmental vitiligo. This approach highlights the specificity involved in manipulating cells for transplantation, providing a targeted treatment strategy for managing vitiligo [4].

Indeed, the effectiveness of surgical methods in treating segmental vitiligo (SV) is primarily attributed to the stability of the observed changes. Typically, in cases of SV, the depigmented areas tend to remain stable over time. This stability criterion is

regarded as crucial for achieving successful outcomes through surgical interventions in the treatment of SV. The consistent nature of the affected areas in SV enhances the prospects of favorable responses to surgical treatments for vitiligo [5].

Nevertheless, patients with stable non-segmented vitiligo may also successfully receive such treatment if this method is supplemented with other available therapeutic options [6-8]. To enhance the clinical outcomes achieved post-surgical procedures, it's often recommended to complement the entire treatment regimen with NB-UVB (Narrowband Ultraviolet B) 311 nm or PUVA (Psoralen plus Ultraviolet A) phototherapy. This adjunctive phototherapy is utilized to consolidate and improve the results obtained from surgical interventions in vitiligo cases, particularly in segmental vitiligo. The combination of surgical methods with these specific phototherapy modalities aims to optimize repigmentation and maintain long-term efficacy in managing vitiligo. Due to the fact that the appropriate qualification of a patient for a given treatment method is one of the most important factors influencing its effectiveness, it was necessary to establish proper inclusion and exclusion criteria that would facilitate this process. In 2021, the British Association of Dermatologists formulated comprehensive guidelines for vitiligo treatment, which acknowledge surgical intervention as one of the potential therapeutic options. However, the guidelines underscore that this treatment is not extensively accessible through the National Health Service (NHS) but rather available in a restricted number of specialized centres. The guidelines propose the consideration of cellular grafting for patients with stable segmental or non-segmental vitiligo, especially in cases where other treatment methods have yielded unsatisfactory results. Nonetheless, the authors of these guidelines classify surgical therapies as a weakly recommended intervention for vitiligo treatment, indicating a more cautious endorsement of surgical approaches compared to other treatments [9].

3. Tissue Grafts

3.1. Mini-Punch Graft (Mpg)

The innovative technique known as minigrafting was initially introduced in 1978 by Rafael Falabella. He employed a dermabrasion device fitted with dental burrs to create abrasions measuring 2 to 3 mm in diameter and less than 1 mm in depth, spaced approximately 5 mm apart. This method represented a modification of the previously established punch grafting technique used in treating hypopigmentation skin disorders [10].

Even after more than 40 years since its introduction, the minigrafting technique remains highly regarded as a cost-effective and straightforward procedure. It is particularly recommended for patients with acral vitiligo or those experiencing hypopigmentation issues in areas such as the nipples, lips, or palms. These areas are known for their irregular shapes and are often deemed less responsive to conventional medical therapies. Minigrafting is considered effective in treating such challenging areas affected by vitiligo due to its ability to address the irregular shapes and complexities of these specific zones [1-13]. In the minigrafting procedure, tissue collection typically occurs from concealed areas such as the upper thigh or the gluteal region.

These regions are chosen due to their hidden nature, ensuring that the donor site remains discreet and less visible post-procedure, and is carried out with a punch biopsy tool equipped with a blade, which allows the obtention of a cylindrical core of tissue sample, whereby the procurement of the tissue may be manual or motorized [14,15].

To optimize the effectiveness of mini punch grafting, the tool is strategically positioned at the donor site to collect the maximum number of grafts from the smallest area possible. Once the tissue grafts are obtained, they are transferred to the previously prepared recipient area. Subsequently, both the treated site and the donor area are covered with dressings, which are typically removed after a period ranging from four to seven days. Following this, phototherapy is implemented as the final stage of treatment. Phototherapy plays a crucial role in facilitating the repigmentation process, exerting a beneficial effect on the outcome of the treatment [16].

According to the findings presented in the article by Mohammad Helalat et al., approximately 90% of patients who underwent mini-punch grafting showcased favourable repigmentation outcomes categorized as good to excellent within a span of six months post-procedure [17]. The study published in 2021 revealed that the pigmentation process could potentially be hastened by utilizing platelet-rich plasma (PRP). Despite the presence of various components in PRP, including β FGF (basic fibroblast growth factor), which influences melanocyte activity, the study indicated that the application of PRP did not yield a significant effect on the ultimate outcome of the treatment. Therefore, while PRP may have the potential to accelerate pigmentation, its specific impact on the final results of the treatment was not notably significant in this study. The most commonly cited therapeutic complications that heavily impact the final cosmetic outcome involve cobblestoning and polka dot effects, significantly influencing the aesthetic appearance of the treated skin. Over the years, modifications introduced to various aspects of the procedure, such as the method of harvesting tissue for transplantation, have aimed to reduce potential complications. A study conducted by Hirobe et al. demonstrated that employing an electric micro-drill to procure a graft with a diameter ranging from 0.6 to 1.0 mm and a depth of 1.5 to 1.8 mm resulted in minimized risk of cobblestoning. Additionally, this technique led to improvements in pigment spreading, enhancing the overall cosmetic results of the procedure [18,19].

Another intriguing concept that researchers have suggested to positively impact the ultimate therapeutic outcomes involves the utilization of transverse needling following mini-punch grafting. According to the authors, this modification has shown promising effects on the treatment results. Their findings suggest that employing transverse needling post-mini-punch grafting enables a higher degree of repigmentation within a shorter duration, achieved with the lowest cumulative dose of NB-UVB compared to when mini-punch grafting and needling are performed separately. This combined approach appears to enhance the effectiveness of the treatment, optimizing repigmentation outcomes while minimizing the required UVB

exposure [20].

3.2. Suction Blister Epidermal Grafting (SBEG)

The technique known as SBEG (Suction Blister Epidermal Grafting) emerged as a novel method in dermatosurgery, first introduced in 1964 by Kiistala and Mustakallio. Their approach involved the separation of the epidermis by inducing blisters. To achieve this, they utilized a device called an angiosterrrometer, initially designed for measuring capillary resistance. The device was repurposed to induce blister formation, allowing for the separation of the epidermal layer—an essential step in the SBEG technique [21]. The concept behind SBEG revolves around the collection of grafts using various suction devices. These devices utilize negative pressure to induce blister formation, which yields grafts that can be subsequently employed in treating various skin conditions, including hypopigmentation areas observed in vitiligo. The blisters obtained through this method contain epidermal tissue that can be utilized for grafting purposes in the treatment of skin conditions, allowing for targeted management of hypopigmentation, such as in vitiligo-affected areas.

We report our retrospective experience with suction blister epidermal grafting in 14 patients with localized, stable, recalcitrant vitiligo. Nineteen suction blister graft procedures were performed on 14 patients with localized, stable, recalcitrant vitiligo on various body sites. The patients were between ages 13 and 60 years; 8 of the 14 were male. All were resistant to various treatments for their vitiligo. All had failed multiple sessions with excimer laser or stabilized and failed to expand further any excimer-induced repigmentation. Two to three weeks after removal of the biomembrane dressing covering the receptor sites, all patients received treatment twice weekly with the 308-nm excimer laser. Subsequent treatments with laser ranged from 15 to 30 treatments over a period of 2-4 months. Final evaluations were assessed at 6 to 9 months after the grafting. Sixteen out of 19 (84.2%) procedures yielded excellent results (75% or more pigmentation). This procedure showed excellent results compared to other surgical procedures currently used for the treatment of resistant, stable vitiligo. Comparison to suction grafts alone or MKTP (non-cultured melanocyte-keratinocyte transfer procedure) grafts were not performed (Personal Communication Dr S Hadi). Indeed, the SBEG method is regarded as both easy and safe, making it a viable option for use around sensitive areas such as the mouth and eyelids. One of its advantages is the absence of necessity for additional specialized equipment [22]. Blister retrieval can be accomplished using a simple syringe, where one end, devoid of the plunger, adheres directly to the skin, while the other end is connected to the needle hub linked to the suction device, creating negative pressure. This setup allows for effective and controlled blister formation without the requirement for complex or specific equipment [23].

The study conducted by Anabar et al. suggests that the rate of blister development is influenced by the diameter of the syringe

used in the SBEG procedure. According to their findings, the authors propose that utilizing syringes with smaller diameters is more advantageous for inducing blister formation in this context. This preference for smaller-diameter syringes may contribute to more controlled and effective blister development during the SBEG procedure, as per their observations [24]. Typically, the duration needed for blister formation through the SBEG procedure ranges from 1.5 to 2 hours. However, it's important to note that the uniformity of this duration and the value of negative pressure applied can vary based on the specific technique utilized. Consequently, these parameters may exhibit variations, leading to differing durations for blister formation. The pressure applied during the process can vary within a range of approximately 150 to 500 mmHg, demonstrating the variability in techniques and settings used in the SBEG method [25,26]. What is more, the time needed for generating a blister can be modified by using local anaesthetics or increasing the body temperature of the area from which the blister is collected [27]. Although the extraction with a syringe seems to be the most convenient way, this method has some drawbacks, including incomplete blister formation and time consumption [28].

Certainly, in recent years, various alternative techniques have emerged for obtaining suction blisters for grafting purposes. One such method involves a specialized Korean technique utilizing cups equipped with valves. This innovative approach offers an alternative way to induce blister formation for graft harvesting in dermato-surgical procedures. Moreover, modified procedures utilizing syringes have been developed, including those integrating a three-way tap system. These adaptations aim to improve blister formation techniques, potentially addressing drawbacks associated with incomplete blister development and time consumption. Such advancements in technique and equipment provide alternative options for effective blister induction in suction blister grafting procedures, enhancing the

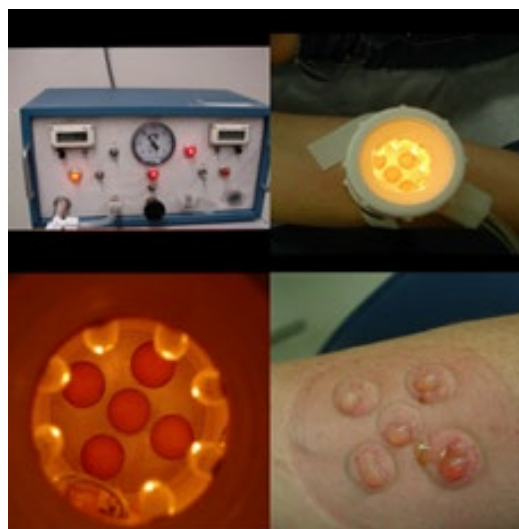

Figure 1: Epidermal suction blister grafting technique

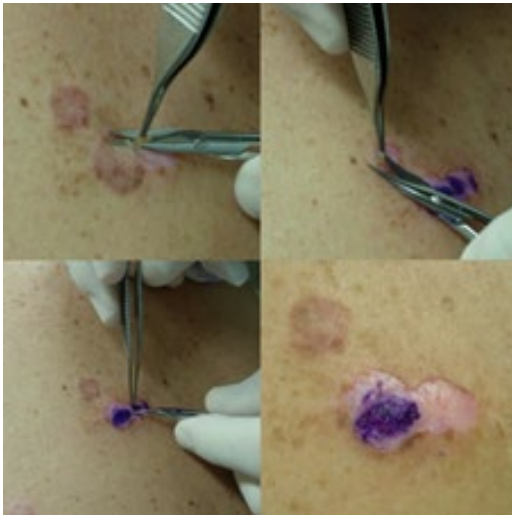

Figure 2: Epidermal Suction blister grafting technique donor site

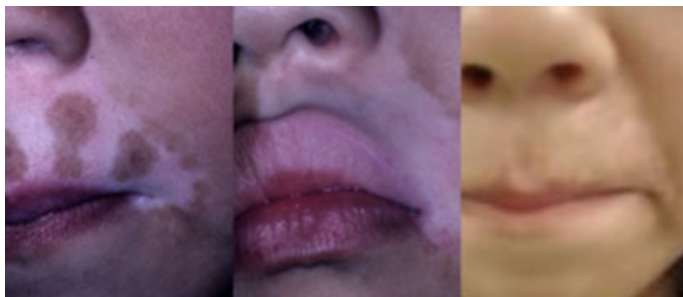


Figure 3: Results following Suction Blister Epidermal Grafting

efficiency and quality of the obtained grafts. or a formula with the use of an automated, epidermal graft-harvesting device, called CelluTome™. Taking into consideration that scarring after SBEG is a very rare complication, various parts of the body are considered suitable for obtaining blisters in SBEG procedures, yet certain regions such as the thigh or forearm remain the preferred sites due to their ease of accessibility and favourable conditions for blister formation [29-32]. However, studies have highlighted the effectiveness of utilizing SBEG in challenging areas such as the angles of the lips, which are often considered particularly difficult to treat. Successful grafting in these complex areas underscores the versatility and potential of SBEG as a viable treatment option for vitiligo and related conditions. Following successful grafting, complementary treatments such as phototherapy can be employed. Phototherapy serves as an additional therapeutic approach aimed at enhancing the repigmentation process, further improving the outcomes achieved through SBEG grafting [33].

3.3 Split-Thickness Skin Grafting (STSG)

The initial documentation of split-thickness skin grafting dates back 150 years, originally termed the cutaneous-epidermal graft by Ollier due to its method. However, it's also recognized as the ultra-thin skin graft or Ollier-Thiersch graft, similar to the techniques patented by these researchers. Another variation, the Blair and Brown method, increased the transplanted tissue by incorporating more of the dermis compared to the Ollier-Thiersch approach [34]. A split-thickness skin graft (STSG)

contains the epidermis and a segment of the dermis, unlike a full-thickness skin graft (FTSG), which includes both the epidermis and complete dermis. These grafts lack their blood supply and depend on a well-vascularized wound bed for integration. They can be sourced from various origins (autograft, homograft, allograft, or xenograft), different anatomical sites, and in different thicknesses. Typically, STSG autografts come from concealed areas like the lateral thigh or trunk, owing to their concealment and ease of harvesting from broad surfaces. STSGs are categorized by thickness into thin (0.15 to 0.3mm), intermediate (0.3 to 0.45mm), and thick (0.45 to 0.6mm) variations [35]. Due to retaining portions of the dermis and dermal appendages, STSG donor sites can regenerate new skin in 2 to 3 weeks, allowing their repeated use after proper healing, making them valuable in scenarios with limited donor sites, such as burn surgery or large wounds [36].

The advantages and disadvantages of STSGs are best highlighted by comparison with FTSGs. Considerations of proper skin graft selection should include graft take, contracture of skin graft, donor site morbidity, aesthetic match, and durability.

- **Graft Take**

Thicker grafts have greater metabolic activity but poorer nutrient diffusion. Thick grafts demand healthier recipient wound beds, avoiding them in unhealthy wounds like chronic ulcers.

- **Contracture**

All grafts undergo primary and secondary contractures. FTSGs experience significant primary contracture due to their higher dermal content, while STSGs face greater secondary contracture. Placement of STSGs in aesthetically sensitive regions should be avoided.

- **Donor Site Morbidity**

STSGs preserve stem cells in hair follicles, aiding donor site reepithelialization, unlike FTSGs that necessitate primary closure, causing more morbidity.

- **Aesthetic Match**

FTSGs offer better color matches, whereas STSGs are more prone to hypo/hyperpigmentation and altered aesthetics due to meshing.

- **Durability**

Dermal thickness is crucial for mechanical strength. Thick grafts or FTSGs are preferred for mechanically demanding areas like palms and joints, whereas thin STSGs are less resilient [37]. STSGs have downsides compared to other reconstructive methods, such as poor resemblance to recipient site skin, increased susceptibility to trauma, reduced recipient site sensation, need for anaesthesia/surgery, and prolonged wound care for both donor and recipient sites compared to flap closure.

3.4 Epidermal Curettage Technique (ECT)

The curettage technique, although known for several decades, was not initially considered a method for tissue grafting in vitiligo treatment [38]. However, positive clinical outcomes associated with this approach prompted researchers to delve deeper into its therapeutic potential [39]. The ECT (Epidermal Curettage Transplantation) procedure involves scraping the previously anesthetized donor area using a sterile curette, often chosen in

the sacral region, until the Auspitz's sign is evident. The material obtained is then treated with physiological saline or hyaluronic acid, forming a paste that is applied onto the hypopigmented area. The recipient area undergoes a similar preparation as the donor area, but the obtained skin is discarded rather than used in the treatment process. Finally, the treated area is covered with a membrane dressing for approximately seven days.

A modified approach known as the Jodhpur technique includes the use of a 2% antibiotic ointment with mupirocin on the donor area, followed by dermabrasion until reaching the upper dermis. This modification resulted in more cost-effective use of tissue grafts, showing initial effects after around a month [40,41]. This method is suitable for treating smaller hypopigmentation areas, allowing treatment of an area approximately four times smaller than the recipient site. Its main advantages include its ease of implementation, absence of the need for specialized equipment, affordability, and the ability to achieve effective therapeutic results. Potential complications of ECT may include skin hyperpigmentation and secondary infections at both the donor and recipient sites, although these side effects are relatively uncommon.

4. Smash Grafting

An alternative surgical technique used for vitiligo treatment is known as smash grafting, which is essentially a modified version of split-thickness skin grafting. The key distinction in smash grafting lies in dividing the skin taken from the donor into smaller fragments before transferring it to the recipient area. Unlike more complex methods, this procedure requires simple tools like a sterile razor and sterile scissors for harvesting the donor tissue. According to Krishnan et al., a critical aspect of this treatment approach is the method of harvesting the skin, emphasizing the importance of obtaining the skin in the smallest possible cuts, resulting in sections around 1–2 cm wide. The collected tissue is then crushed or cut for 15–20 minutes until it achieves a mushy consistency [42].

Consequently, the graft obtained from the donor site is up to 10 times smaller than the treated region. The adequately prepared tissue is then placed in a saline solution. Subsequently, the prepared tissue is applied to the affected skin area, previously prepared with a dermabrader. This method disrupts the continuity of the epidermis and dermis, causing the exudation of substances containing growth factors that influence the regenerative processes in the patient's skin [43]. As the graft is in a pulp form, there is no need to consider which side of the graft faces the recipient side. It's crucial to meticulously cover the edges of the hypopigmented area with the prepared material due to the centralization of pigment spreading [44].

4.1. Flip-Top Grafting

A flap of tissue within the epidermis is lifted at the recipient site, and tiny segments of donor tissue are carefully inserted beneath it. This technique offers an economical, natural, and efficient dressing. Additionally, it acts as a visual access point, enabling observation of the extent of repigmentation, thereby aiding in the assessment of the procedure's success [45].

4.2. Hair Follicle Graft

This approach shares similarities with hair transplant methods like follicular unit extraction or strip follicular transplant. In these hair transplant techniques, hair follicles are extracted from a donor area and relocated to another region. Typically, the donor site is the hair located at the back of the scalp (occipital area). The transplanted hair is usually spaced around 5–10 mm apart. Variations of this technique include specialized procedures like eyelash transplantation for treating leucotrichia and vellus hair transplantation [46].

5. Cellular Grafts

5.1. Cultured Melanocyte Graft

In this approach, a split-thickness skin graft is obtained, and melanocytes are isolated from it. Through cellular culture methods, their quantity is expanded to cover a larger surface area. Typically, the donor to recipient ratio stands at 1:60. Additionally, these melanocytes can be cultured alongside keratinocytes. Co-cultivating with keratinocytes offers benefits as they secrete growth factors that stimulate melanocyte growth [47]. While this technique significantly expands the coverage area, it is associated with higher costs [48].

6. Non-cultured Melanocyte-Keratinocyte Suspension

The pioneering figure behind this method was Gauthier, which closely resembles cultured melanocyte transplantation [49]. Notably, this procedure can be carried out even in locations lacking cell culture facilities. However, it features a lower donor to recipient ratio, typically ranging from 1:5 to 1:10. Despite this, its applicability remains wide as larger areas can still be covered by utilizing a greater number of donor sites [50].

To separate the cells, trypsinization of the harvested split-thickness graft can be conducted through cold or warm methods. The traditional cold method involves an 18-hour trypsin action on tissue at 4°C. Olsson and Juhlin modified this in 1998, reducing the digestion time to 60 minutes at 37°C. Although warm trypsinization is faster, studies indicate its inferiority in yielding viable cells compared to the cold method. However, newer approaches like room temperature trypsinization have demonstrated efficacy comparable to other methods [51-53]. Numerous modifications have been introduced to enhance this technique, including the addition of hyaluronic acid to increase viscosity (Van Geel et al.) and the substitution of melanocyte culture media with phosphate-buffered saline (Holla et al.). Platelet-rich plasma, when used as a suspension medium, enhances pigmentation due to its array of growth factors [54-56].

Several simplified methods have been developed, such as battery devices and welled plates, which eliminate the need for sophisticated instruments and lab setups while achieving similar outcomes. Moreover, bypassing the need for an incubator in warm trypsinization can be achieved by taping the donor epidermal tissue in an Eppendorf tube to the axillary vault for 50 minutes. The Jodhpur technique, a modification, skips the trypsinization step and has shown slightly better repigmentation compared to follicular unit transplantation. To retain transplanted material on uneven contours, a putty material can be used as a scaffold.

Advantages of NCES (Non-Cultured Epidermal Suspension) include covering large areas in a single session, achieving good cosmetic outcomes, and excellent colour matching [57-61].

7. Non-cultured outer root sheath hair follicle cell suspension (NCORSHFS)

The outer root sheath, mid-follicle region, and hair bulb matrix contain a substantial concentration of melanocytes and their precursors. This source is tapped into either after follicular unit extraction or through plucking hair follicles, followed by follicular unit suspension. The trypsinization steps involved are akin to those used in the NCES (Non-Cultured Epidermal Suspension) technique. Importantly, there exists a significant correlation between the quantity of transferred melanocytes and the subsequent repigmentation observed [62,63].

8. Conclusion

In the realm of treating hypopigmentation resulting from vitiligo, surgical methods are typically reserved for situations where commonly available therapies have not yielded satisfactory clinical outcomes. While these surgical interventions have shown promise, they come with associated side effects. Despite modifications to established techniques and the emergence of new methods, surgical interventions appear to be a viable option for patients with stable vitiligo forms. One prevalent side effect is the Koebner phenomenon, observed in conditions such as lichen planus, psoriasis, and vitiligo, with an estimated incidence of up to 62%. This phenomenon involves the appearance of previously unseen skin changes in areas that have been damaged. Surgical procedures might trigger the Koebner phenomenon, leading to the development of new vitiligo changes in some cases, as reported in a 14-year-old patient following the suction blister method. Therefore, the selection of the transplant site and technique becomes crucial, particularly in patients with a history of Koebnerization. For these individuals, opting for a method that treats the largest hypopigmentation area with the smallest graft size might be advisable. However, it's important to note that the Koebner phenomenon can vary, and individuals who haven't previously experienced it could develop Koebnerization over time. Consequently, the presence of Koebnerization often discourages surgical treatment for vitiligo patients. Medications taken by patients should also be considered before opting for surgery. A meta-analysis on the side effects of melanoma treatments revealed that vitiligo is one of the most common side effects associated with checkpoint inhibitors and PD-1 inhibitors. Treatment with nivolumab or pembrolizumab has been linked to the development of grade 1 and 2 vitiligo. Moreover, reports exist of new hypopigmentation changes in patients with hidradenitis suppurativa treated with adalimumab. Hence, it's crucial to contemplate potential therapeutic effects post-surgery along with any skin-related side effects caused by concurrent medications.

References

1. Frączek, A., Kasprowicz-Furmańczyk, M., Placek, W., & Owczarczyk-Saczonek, A. (2022). Surgical treatment of vitiligo. *International journal of environmental research and public health*, 19(8), 4812.

2. Ashwini, P. K., Sushmitha, D. J., & Veeranna, S. (2020). Vitiligo with special emphasis on vitiligo surgery. *Archives of Medicine and Health Sciences*, 8(1), 140-146.
3. Dillon, A. B., Sideris, A., Hadi, A., & Elbuluk, N. (2017). Advances in vitiligo: an update on medical and surgical treatments. *The Journal of clinical and aesthetic dermatology*, 10(1), 15.
4. Khunger, N., Kathuria, S. D., & Ramesh, V. (2009). Tissue grafts in vitiligo surgery-past, present, and future. *Indian journal of dermatology*, 54(2), 150-158.
5. Gamal, A. M., El-Barbary, R. A., & Moftah, N. H. (2021). Updates in surgical treatment of vitiligo. *Journal of Recent Advances in Medicine*, 2(1), 118-127.
6. Czajkowski, R., Placek, W., Flisiak, I., Krasowska, D., Maj, J., Marchlewicz, M., ... & Rudnicka, L. (2019). Vitiligo. Diagnostic and therapeutic recommendations of the Polish Dermatological Society. *Dermatology Review/Przegląd Dermatologiczny*, 106(1), 1-15.
7. Eleftheriadou, V., Atkar, R., Batchelor, J., McDonald, B., Novakovic, L., Patel, J. V., ... & British Association of Dermatologists' Clinical Standards Unit. (2022). British Association of Dermatologists guidelines for the management of people with vitiligo 2021. *British Journal of Dermatology*, 186(1), 18-29.
8. Falabella, R. (1978). Repigmentation of leukoderma by minigrafts of normally pigmented, autologous skin. *The Journal of Dermatologic Surgery and Oncology*, 4(12), 916-919.
9. Njoo, M. D., Westerhof, W., Bos, J. D., & Bossuyt, P. M. M. (1998). A systematic review of autologous transplantation methods in vitiligo. *Archives of dermatology*, 134(12), 1543-1549.
10. Lahiri, K. (2009). Evolution and evaluation of autologous mini punch grafting in vitiligo. *Indian Journal of Dermatology*, 54(2), 159-167.
11. Chandrashekar, B. S., Madura, C., & Varsha, D. V. (2014). Autologous mini punch grafting: an experience of using motorized power punch in 10 patients. *Journal of cutaneous and aesthetic surgery*, 7(1), 42-45.
12. Mohammad, T. F., & Hamzavi, I. H. (2017). Surgical therapies for vitiligo. *Dermatologic clinics*, 35(2), 193-203.
13. Lahiri, K., Malakar, S., Sarma, N., & Banerjee, U. (2006). Repigmentation of vitiligo with punch grafting and narrow-band UV-B (311 nm)—a prospective study. *International journal of Dermatology*, 45(6), 649-655.
14. Helalat, M., Rawashdeh, B., Odiebat, H., Smadi, R., & Zyod, I. (2012). Punch Minigrafting for Stable Vitiligo: Our Experience at the Jordanian Royal Medical Services. *JR Med. Serv*, 19, 81-86.
15. Salem, S. A. M., Fezeaa, T. A., El Khazragy, N., & Soltan, M. Y. (2021). Effect of platelet-rich plasma on the outcome of mini-punch grafting procedure in localized stable vitiligo: clinical evaluation and relation to lesional basic fibroblast growth factor. *Dermatologic Therapy*, 34(2), e14738.
16. Hirobe, T., & Enami, H. (2018). Excellent color-matched repigmentation of human vitiligo can be obtained by mini-punch grafting using a machine in combination with ultraviolet therapy. *Dermatologica sinica*, 36(4), 203-206.

17. Ragab, M., El Zagh, O., & Farid, C. (2021). Transverse Needling After Autologous Mini-Punch Grafts Improves Repigmentation in Stable Non-Segmental Vitiligo. *Clinical, Cosmetic and Investigational Dermatology*, 827-835.
18. Kiistala, U., & Mustakallio, K. K. (1964). In-vivo separation of epidermis by production of suction blisters. *The Lancet*, 283(7348), 1444-1445.
19. Kar, B. R., & Raj, C. (2018). Suction blister epidermal grafting for vitiligo involving angles of lip: Experience of 112 patients. *Journal of Cutaneous and Aesthetic Surgery*, 11(1), 13-19.
20. Angeletti, F., & Kaufmann, R. (2019). Suction blister epidermal graft (SBEG)—an easy way to apply this method. *JDDG: Journal der Deutschen Dermatologischen Gesellschaft*, 17(4), 468-471.
21. Anbar, T. S., El-Fakahany, H. M., El-khayyat, M. A., Abdel-Rahman, A. T., & Saad, E. K. (2020). Factors affecting the outcome of the suction blisters using two different harvesting techniques in vitiligo patients. *Journal of Cosmetic Dermatology*, 19(7), 1723-1729.
22. Al-Hadidi, N., Griffiths, J. L., Al-Jamal, M. S., & Hamzavi, I. (2015). Role of recipient-site preparation techniques and post-operative wound dressing in the surgical management of vitiligo. *Journal of cutaneous and aesthetic surgery*, 8(2), 79-87.
23. Anbar, T. S., Moftah, N. H., El-Khayyat, M. A., El-Fakahany, H. M., Abdel-Rahman, A. T., & Saad, E. K. (2018). Syringes versus Chinese cups in harvesting suction-induced blister graft: a randomized split-body study. *International Journal of Dermatology*, 57(10), 1249-1252.
24. Gupta, S., Shroff, S., & Gupta, S. (1999). Modified technique of suction blistering for epidermal grafting in vitiligo. *International journal of dermatology*, 38(4), 306-309.
25. Smith, O. J., Edmondson, S. J., Bystrzonowski, N., Hachach-Haram, N., Kanapathy, M., Richards, T., & Mosahebi, A. (2017). The CelluTome epidermal graft-harvesting system: a patient-reported outcome measure and cost evaluation study. *International wound journal*, 14(3), 555-560.
26. Hachach-Haram, N., Bystrzonowski, N., Kanapathy, M., Smith, O., Harding, K., Mosahebi, A., & Richards, T. (2017). A prospective, multicentre study on the use of epidermal grafts to optimise outpatient wound management. *International wound journal*, 14(1), 241-249.
27. Iwanowski, T., Szlązak, P., Rustowska, A., & Sokołowska-Wojdyło, M. (2018). Efficacy of suction blister epidermal grafting with concomitant phototherapy in vitiligo treatment. *Advances in Dermatology and Allergology/Postępy Dermatologii i Alergologii*, 35(6), 592-598.
28. Hann, S. K., Im, S., Bong, H. W., & Park, Y. K. (1995). Treatment of stable vitiligo with autologous epidermal grafting and PUVA. *Journal of the American Academy of Dermatology*, 32(6), 943-948.
29. Kohlhauser, M., Luze, H., Nischwitz, S. P., & Kamolz, L. P. (2021). Historical evolution of skin grafting—a journey through time. *Medicina*, 57(4), 348.
30. Johnson, T. M., Ratner, D., & Nelson, B. R. (1992). Soft tissue reconstruction with skin grafting. *Journal of the American Academy of Dermatology*, 27(2), 151-165.
31. Stephenson, A. J., Griffiths, R. W., & TP, L. H. B. (2000). Patterns of contraction in human full thickness skin grafts. *British journal of plastic surgery*, 53(5), 397-402.
32. Oh, S. J., Kim, S. G., Cho, J. K., & Sung, C. M. (2014). Palmar crease release and secondary full-thickness skin grafts for contractures in primary full-thickness skin grafts during growth spurts in pediatric palmar hand burns. *Journal of Burn Care & Research*, 35(5), e312-e316.
33. Machado Filho, C. D., & Timoner, F. R. (2014). Epidermal curettage technique (ECT) for tissue harvest from the donor area for melanocyte autologous grafting in cases of vitiligo. *Anais brasileiros de dermatologia*, 89, 681-683.
34. Machado Filho, C. D., Almeida, F. A., Proto, R. S., & Landman, G. (2005). Vitiligo: analysis of grafting versus curettage alone, using melanocyte morphology and reverse transcriptase polymerase chain reaction for tyrosinase mRNA. *Sao Paulo Medical Journal*, 123, 187-191.
35. Tyagi, S., Malhotra, S. K., & Kaur, T. (2021). Comparative evaluation of efficacy of non-cultured epidermal cell suspension and epidermal curettage in stable vitiligo. *Journal of Cutaneous and Aesthetic Surgery*, 14(1), 32-40.
36. Kachhawa, D., & Kalla, G. (2008). Keratinocyte-melanocyte graft technique followed by PUVA therapy for stable vitiligo. *Indian journal of dermatology, venereology and leprology*, 74, 622.
37. Krishnan, A., & Kar, S. (2012). Smashed skin grafting or smash grafting—a novel method of vitiligo surgery. *International Journal of Dermatology*, 51(10), 1242-1247.
38. Kar, S., Krishnan, A., & Singh, S. (2018). Smash Grafting. *Vitiligo: Medical and Surgical Management*, 261-265.
39. Park, J. W., Hwang, S. R., & Yoon, I. S. (2017). Advanced growth factor delivery systems in wound management and skin regeneration. *Molecules*, 22(8), 1259.
40. Sharma, S., Garg, V. K., Sarkar, R., & Relhan, V. (2013). Comparative Study of Flip-top Transplantation and Punch Grafting in Stable Vitiligo. *Dermatologic Surgery*, 39(9), 1376-1384.
41. Mapar, M. A., Safarpour, M., Mapar, M., & Haghighizadeh, M. H. (2014). A comparative study of the mini-punch grafting and hair follicle transplantation in the treatment of refractory and stable vitiligo. *Journal of the American Academy of Dermatology*, 70(4), 743-747.
42. Imokawa, G., Yada, Y., & Miyagishi, M. (1992). Endothelins secreted from human keratinocytes are intrinsic mitogens for human melanocytes. *Journal of Biological Chemistry*, 267(34), 24675-24680.
43. BRYSK, M. M., NEWTON, R. C., RAJARAMAN, S., PLOTT, T., BARLOW, E., BELL, T., ... & SMITH, E. B. (1989). Repigmentation of vitiliginous skin by cultured cells. *Pigment Cell Research*, 2(3), 202-207.
44. Gauthier, Y., & Surleve-Bazeille, J. E. (1992). Autologous grafting with noncultured melanocytes: a simplified method for treatment of depigmented lesions. *Journal of the American Academy of Dermatology*, 26(2), 191-194.
45. Narayan, V. S., Van den Bol, L. L. C., van Geel, N., Bekkenk, M. W., Luiten, R. M., & Wolkerstorfer, A. (2021). Donor to recipient ratios in the surgical treatment of vitiligo and piebaldism: a systematic review. *Journal of the European*

- Academy of Dermatology and Venereology*, 35(5), 1077-1086.
46. Olsson, M. J., & Juhlin, L. (1998). Leucoderma treated by transplantation of a basal cell layer enriched suspension. *British Journal of Dermatology*, 138(4), 644-648.
47. Awasti, S., Vinay, K., Thakur, V., Kumar, R., Holla, A. P., Sahni, K., ... & Kanwar, A. J. (2019). Comparison of efficacy of cold trypsinization versus warm trypsinization in preparation of autologous non-cultured epidermal cell suspension for treatment of stable vitiligo. *Journal of the European Academy of Dermatology and Venereology*, 33(6), e237-e239.
48. Rasheed, H. M., Esmat, S. M., Hegazy, R. A., Gawdat, H. I., Bassiouny, D. M., Doss, S. S., ... & Elkhoully, N. S. (2020). Effect of different methods of trypsinization on cell viability and clinical outcome in vitiligo patients undergoing noncultured epidermal cellular suspension. *Dermatologic Surgery*, 46(10), 1307-1314.
49. Van Geel, N., Ongenaes, K., De Mil, M., & Naeyaert, J. M. (2001). Modified technique of autologous noncultured epidermal cell transplantation for repigmenting vitiligo: a pilot study. *Dermatologic surgery*, 27(10), 873-876.
50. Holla, A. P., Kumar, R., Parsad, D., & Kanwar, A. J. (2011). Modified procedure of noncultured epidermal suspension transplantation: changes are the core of vitiligo surgery. *Journal of Cutaneous and Aesthetic Surgery*, 4(1), 44-45.
51. Parambath, N., Sharma, V. K., Parihar, A. S., Sahni, K., & Gupta, S. (2019). Use of platelet-rich plasma to suspend noncultured epidermal cell suspension improves repigmentation after autologous transplantation in stable vitiligo: a double-blind randomized controlled trial. *International journal of dermatology*, 58(4), 472-476.
52. Mulekar, S. V., Ghwish, B., Al Issa, A., & Al Eisa, A. (2008). Treatment of vitiligo lesions by ReCell® vs. conventional melanocyte-keratinocyte transplantation: a pilot study. *British Journal of Dermatology*, 158(1), 45-49.
53. Goh, B. K., Chua, X. M., Chong, K. L., De Mil, M., & van Geel, N. A. (2010). Simplified cellular grafting for treatment of vitiligo and piebaldism: the "6-well plate" technique. *Dermatologic surgery*, 36(2), 203-207.
54. Bhatia, S., Rajput, L., & Gupta, S. (2021). Axillary incubator for cell-based therapies in vitiligo. *Journal of the American Academy of Dermatology*, 85(5), e279-e280.
55. Lamoria, A., Agrawal, A., Rao, P., & Kachhawa, D. (2020). A comparative study between follicular unit transplantation and autologous non-cultured non-trypsinized epidermal cells grafting (Jodhpur technique) in stable vitiligo. *Journal of Cutaneous and Aesthetic Surgery*, 13(3), 204-209.
56. Akshi, B., Shilpa, K., & Harish, P. (2022). A novel point-of-care technique to improve graft uptake in a melanocyte-keratinocyte transplantation procedure for vitiligo of contoured areas such as the external ear. *Journal of the American Academy of Dermatology*, 86(5), e191-e192.
57. Mohanty, S., Kumar, A., Dhawan, J., Sreenivas, V., & Gupta, S. (2011). Noncultured extracted hair follicle outer root sheath cell suspension for transplantation in vitiligo. *British Journal of Dermatology*, 164(6), 1241-1246.
58. Vinay, K., Dogra, S., Parsad, D., Kanwar, A. J., Kumar, R., Minz, R. W., & Saikia, U. N. (2015). Clinical and treatment characteristics determining therapeutic outcome in patients undergoing autologous non-cultured outer root sheath hair follicle cell suspension for treatment of stable vitiligo. *Journal of the European Academy of Dermatology and Venereology*, 29(1), 31-37.
59. Barona, M. I., Arrunátegui, A., Falabella, R., & Alzate, A. (1995). An epidemiologic case-control study in a population with vitiligo. *Journal of the American Academy of Dermatology*, 33(4), 621-625.
60. Liu, W., & Ma, D. L. (2019). Koebner phenomenon in vitiligo after suction blister epidermal grafting. *CMAJ*, 191(35), E968-E968.
61. Sanchez D.P., Sonthalia S. StatPearls [Internet] StatPearls Publishing; Treasure Island, FL, USA: 2022. [(accessed on 10 March 2022)]. Koebner Phenomenon.
62. Mulekar S.V. Koebner Phenomenon in Vitiligo: Not Always an Indication of Surgical Failure. *Arch. Dermatol.*
63. Mineiro dos Santos Garrett, N. F., Carvalho da Costa, A. C., Barros Ferreira, E., Damiani, G., Diniz dos Reis, P. E., & Inocencio Vasques, C. (2021). Prevalence of dermatological toxicities in patients with melanoma undergoing immunotherapy: Systematic review and meta-analysis. *PLoS One*, 16(8), e0255716.

Copyright: ©2024 Professor Al Abadie, et al. This is an open-access article distributed under the terms of the Creative Commons Attribution License, which permits unrestricted use, distribution, and reproduction in any medium, provided the original author and source are credited.