

Central Lancashire Online Knowledge (CLoK)

Title	Livedoid Vasculopathy
Type	Article
URL	https://clock.uclan.ac.uk/54965/
DOI	doi:10.46889/JDR.2025.6107
Date	2025
Citation	Jatana, Gurpoornam, Salih, Hasan, Islam, Lubna, Chopra, Rajan, Forgie, John and Al Abadie, Mohammed (2025) Livedoid Vasculopathy. <i>Journal of Dermatology Research</i> , 6 (1). pp. 1-8.
Creators	Jatana, Gurpoornam, Salih, Hasan, Islam, Lubna, Chopra, Rajan, Forgie, John and Al Abadie, Mohammed

It is advisable to refer to the publisher's version if you intend to cite from the work.
doi:10.46889/JDR.2025.6107

For information about Research at UCLan please go to <http://www.uclan.ac.uk/research/>

All outputs in CLoK are protected by Intellectual Property Rights law, including Copyright law. Copyright, IPR and Moral Rights for the works on this site are retained by the individual authors and/or other copyright owners. Terms and conditions for use of this material are defined in the <http://clock.uclan.ac.uk/policies/>

Case Report

Livedoid Vasculopathy

Gurpoonam Jatana^{1*}, Hasan Salih², Lubna Islam¹, Rajan Chopra³, John Forgie⁴, Mohammed Al Abadie⁵

¹Blackpool Teaching Hospital, United Kingdom

²Dermatology Specialist Doctor, Blackpool Teaching Hospital, United Kingdom

³Consultant Histopathologist, Blackpool Teaching Hospital, United Kingdom

⁴Consultant Dermatologist, Blackpool Teaching Hospital, United Kingdom

⁵Professor, Clinical Director and Consultant Dermatologist, North Cumbria Integrated Care NHS Foundation Trust, University of Central Lancashire, UCLAN Medical School, United Kingdom

*Correspondence author: Gurpoonam Jatana, MD, Blackpool Teaching Hospital, United Kingdom; Email: gurpoonam.jatana@nhs.net

Abstract

Livedoid Vasculopathy (LV) is an uncommon thrombotic occlusive vasculopathy presenting with chronic relapsing-remitting painful skin ulcerations, predominantly affecting the feet and ankles bilaterally. LV can be idiopathic or secondary to varied causes including endothelial, rheological, haemostatic or fibrinolytic pathologies. We describe three LV cases here in with a review of the current literature on its epidemiology, risk factors and management options. It is of quite clinical significance to differentiate the LV from vasculitic disorders, as the management of the latter being based on immunosuppression, whereas LV treatment is mostly based around anticoagulant or antiplatelet therapy.

Keywords: Livedoid Vasculopathy; Vasculitic Disorders; Antiplatelet Therapy

Introduction

Livedoid Vasculopathy (LV) is a chronic cutaneous thrombotic condition that can mimic numerous common skin disorders involving on lower legs. It was originally described in 1955 with an average annual incidence of 1 in 100,000 as per review in 2013 [1]. Clinically, it usually presents as painful recurrent ulcerations on lower legs secondary to vasculopathy and thrombi formation [2]. Most recently, it is characterized as capillary microcirculation occlusive condition that causes local ischemia and infarction [3]. The ulceration is usually associated with extremely painful retiform purpura on the lower legs and ankles, which may affect patient's mental health and quality of life [4]. In addition to ulcers, some patients may develop purpuric plaques followed by atrophie blanche, scars and telangiectasia [5,6].

Management of LV includes general measures such as pain relief, wound care and possible anticoagulant and antiplatelet medication. There are promising new ongoing studies in the use of anti-interleukin 17A biologic therapies in the management of LV [4].

Livedoid vasculopathy is a clinical diagnosis which can be supported by biopsy findings. Histological findings of the skin lesion usually comprise vascular ectasia with hyalinization of superficial dermal vessels accompanied by possible intraluminal fibrin deposition and perivascular infiltrate [5].

Till date, pathogenesis of LV remains unclear. However, some studies show hypercoagulability and thrombotic events contributing to pathogenesis along with an inflammatory response [7]. Some patients may have associated livedo reticularis occasionally can lead to misdiagnosis for this condition [8].

LV is three-fold more common in females to males. There is a higher incidence in summer months. The treatment options are limited and no specific treatment has been described in the literature [9].

Citation: Jatana G, et al. Livedoid Vasculopathy. J Dermatol Res. 2025;6(1):1-8.

<https://doi.org/10.46889/JDR.2025.6107>

Received Date: 23-01-2025

Accepted Date: 28-02-2025

Published Date: 07-03-2025



Copyright: © 2025 by the authors. Submitted for possible open access publication under the terms and conditions of the Creative Commons Attribution (CCBY) license (<https://creativecommons.org/licenses/by/4.0/>).

Case Series

We present 3 cases seen at our dermatology clinics in the last 12 months.

Case 1

A 61-year-old female presented in the Dermatology department with two weeks history of purpuric spots on lower limbs and forearms. No systemic symptoms were present at the time. She later developed a large area of ulcerations involving both legs. Her medical history was Hypertension (HTN) and borderline type 2 diabetes. Initially, the clinical diagnosis was suggestive of leukocytoclastic vasculitis.

Physical examination showed violaceous ulcerated plaques confined to both legs (Fig. 1). No other examination finding was present. Blood tests including Anti Neutrophil Antibodies (ANCA) and Connective Tissue Disorder (CTD) screening antibodies were negative.

Other investigations including C Reactive Protein (CRP) 11.5 mg/l, eGFR 46 ml/min/1.73m² which was persistently low over the years. Her Albumin Creatinine (ACR) was 2.40 mg/mmol and random urine microalbumin 36.6ug/ml. CRP 23.7. Viral screens including Hepatitis virus B and C were negative. She was initially treated with an oral prednisolone low dose and then switched to high dose for 4-6 weeks, without significant improvement.

A skin incisional biopsy was undertaken with differentials of pyoderma gangrenosum, ecthyma gangrenosum, livedoid vasculopathy, peripheral vascular disease and vasculitis. It showed prominent dermal vascularity with mild thickening of their wall with PASD stain positive material which suggested livedoid vasculopathy; no thrombi or vasculitis were evident.

Following the biopsy results and case discussion at our inflammatory skin MDT; an overall diagnosis of livedoid vasculopathy was favored in this case. She was reviewed in the leg ulcer clinic wherein her TBPI (toe brachial pressure index) was 0.93 mmHg to the left and 1.01 mmHg to the right leg. She was treated with class 2 compression bandages and dressing. Within 3-4 months' time her leg ulcers improved significantly. Furthermore, in the interim, she had CT angiogram which revealed Pulmonary embolism, as a result, she was prescribed with the warfarin for life, which has possibly helped with the healing of the leg ulcers.

Case 2

A 79-year-old male with history of asthma, Hypertension (HTN), chronic venous insufficiency, acquired hypothyroidism, gout and osteoarthritis. He initially presented to the dermatology clinic with bilateral erythematous non-blanching pruritic rash in both legs. Given the background of chronic venous insufficiency, he was initially treated as stasis dermatitis with emollients and topical corticosteroids. He later reviewed in our leg ulcer clinic for weeping rash extending on both legs whereupon he was managed with dressing and antibiotics.

Later, he was urgently admitted to the hospital with generalized pruritic eruption. His Full blood count showed WCC 7.6, Hb 138, but his CRP 61.5. He had negative serology tests which included connective tissue antibodies (CTA), Beta 2 glycoprotein 1, Anti CCP antibody, ANCA screen, Anticardiolipin antibody 1.5, Myositis antigen profile and lupus anti-coagulant. Prothrombin Time (PT) and activated partial thromboplastin time (APTT) were within normal range and complement tests (C3 1.50 and C4 0.52). The viral screen showed positive for Hepatitis B core antibodies, which was further reviewed by gastroenterology and indicated past hepatitis B infection.

On clinical examination, there were erythematous oedema extending to the mid-shin, with multiple superficial ulcers, purplish discoloration and granulation tissue formation in both legs (Fig. 2).

Skin biopsies were undertaken during hospital examination for light microscopy and DIF (Direct Immunofluorescence) were taken; the DIF was negative for immune-reactants. The biopsy result showed focal partial erosion of the epidermis associated with the prominence of superficial dermal vascularity. The vessel walls were uniformly thickened by the presence of eosinophilic hyalin-like material in their wall accompanied by focal microthrombi (Fig. 2). This hyalinised material was positive for PASD (Periodic Acid-Schiff-diastase stain) and it was negative for amyloid by Congo red stain and was also negative for fibrin with MSB (Martius Scarlet Blue) stain. These findings favoured livedoid vasculopathy in this case.

His Ankle Brachial Pressure Index (ABPI) on right and left leg were 1.08 and 1.07 respectively. He was treated with appropriate compression stockings which showed some improvements. Few months later, his leg ulcers started to get worse, therefore, he was commenced on pentoxifylline and topical antibiotics. However, the patient didn't show any noticeable improvement. As a result, he was tried on one of the Direct Oral Anticoagulants (DOACs) for 3 months, which showed better results in the severity of leg ulcers.

Case 3

A 67-year female was being seen in the dermatology department, for the skin lesions of prurigo nodularis. Months later, she presented with the painful leg ulcerations over both shins, with erythematous to violaceous base; healing with a cribriform-like scarring on background of leg oedema. She also had small punched-out ulcers associated with reticular purpura (Fig. 3).

Blood tests including cryoglobulins, antiphospholipid antibodies, coagulation profile and autoimmune profile came back within normal limits. ANCA (Antineutrophil Cytoplasmic Antibodies), ANA (antinuclear antibody), Anti-cardiolipin antibodies were also negative.

Her past medical history included seropositive rheumatoid arthritis, anti-Cyclic Citrullinated Peptide (anti-CCP) positive, generalized osteoarthritis, cervical and lumbar spondylosis, Eczema.

A skin biopsy was undertaken which showed ulcerated surface with inflammatory slough; underlying which the oedematous dermis contained mildly prominent ectatic vascularity. Many of the superficial vascular channels had mild uniform stiffening of vessel wall contain bright eosinophilic material which was positive for PASD (Periodic ACID-SCHIFF DIASTASE) stain; it was negative for amyloid by Congo red stain; and was also negative for fibrin with MSB (Martius Scarlet Blue) stain (Fig. 3). A few superficial vascular channels also contained thrombi No convincing vasculitis evident in this biopsy. These findings suggested livedoid vasculopathy.

Patient couldn't tolerate pentoxifylline and was switched to one of the direct oral anticoagulants (DOACs) instead. Leg ulcers were treated with topical emollients and dressing, with compression stocking. With this management, it took months to achieve remission in this case.

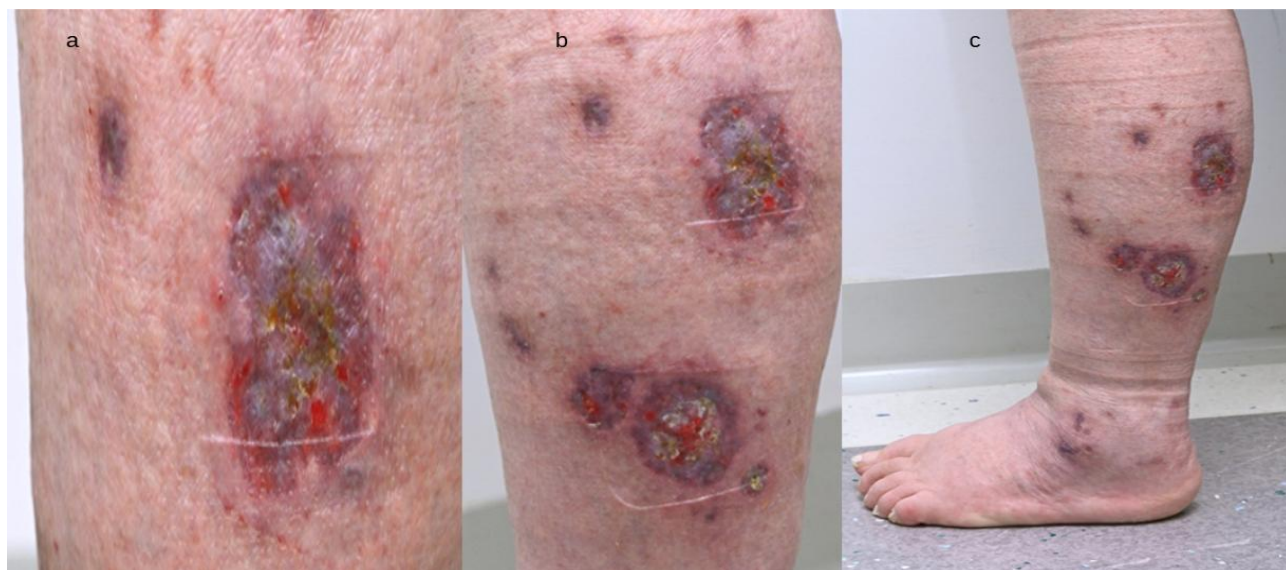

Figure 1: (a) Purple ulcers in a close up on the left leg; (b) Non healing ulcers as well as scarring of the previous healed ulcers on the left leg; (c) Shows close-up view of violaceous to purplish ulcers on left leg along with hyperpigmented scarring seen both on left leg and foot.

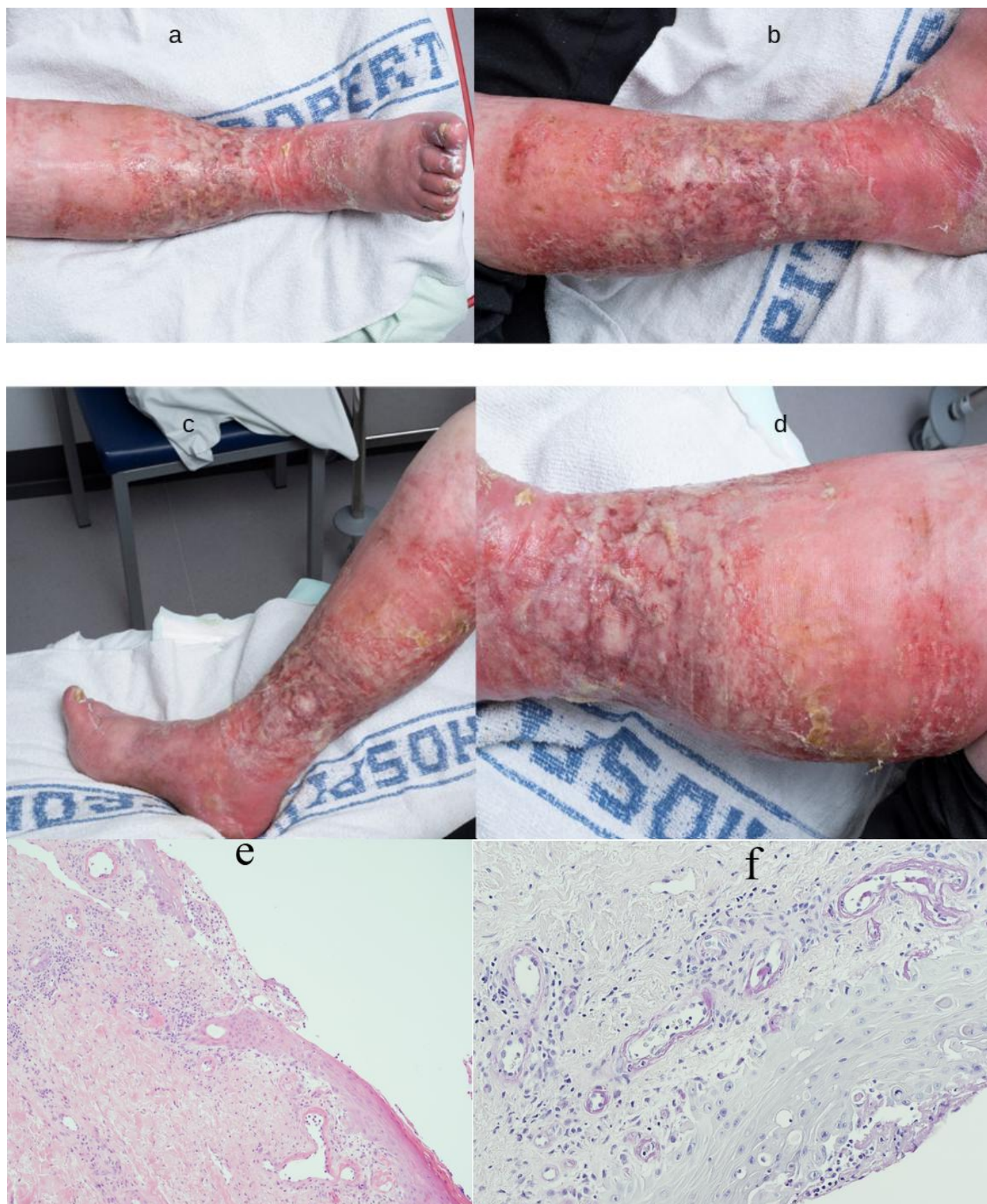


Figure 2: Erythematous and swollen right lower limb with superficial confluent painful plaques and granulation tissue formation over a few areas (anterior view); (a): Small ulcer seen over the middle of the lower limb; (b): Erythematous and swollen left leg with superficial ulceration and granulation tissue formation (lateral view); (c): Erythematous and swollen right

leg with confluent painful plaques formation and the thrombophlebitis; (d): Close up of erythematous and swollen right leg with superficial ulceration and granulation tissue formation; (e): Partial skin erosion with livedoid vasculopathy, hyalinised material in wall, H & E 100X; (f): Livedoid vasculopathy, PASD positive material in vessel wall, PASD 200X.

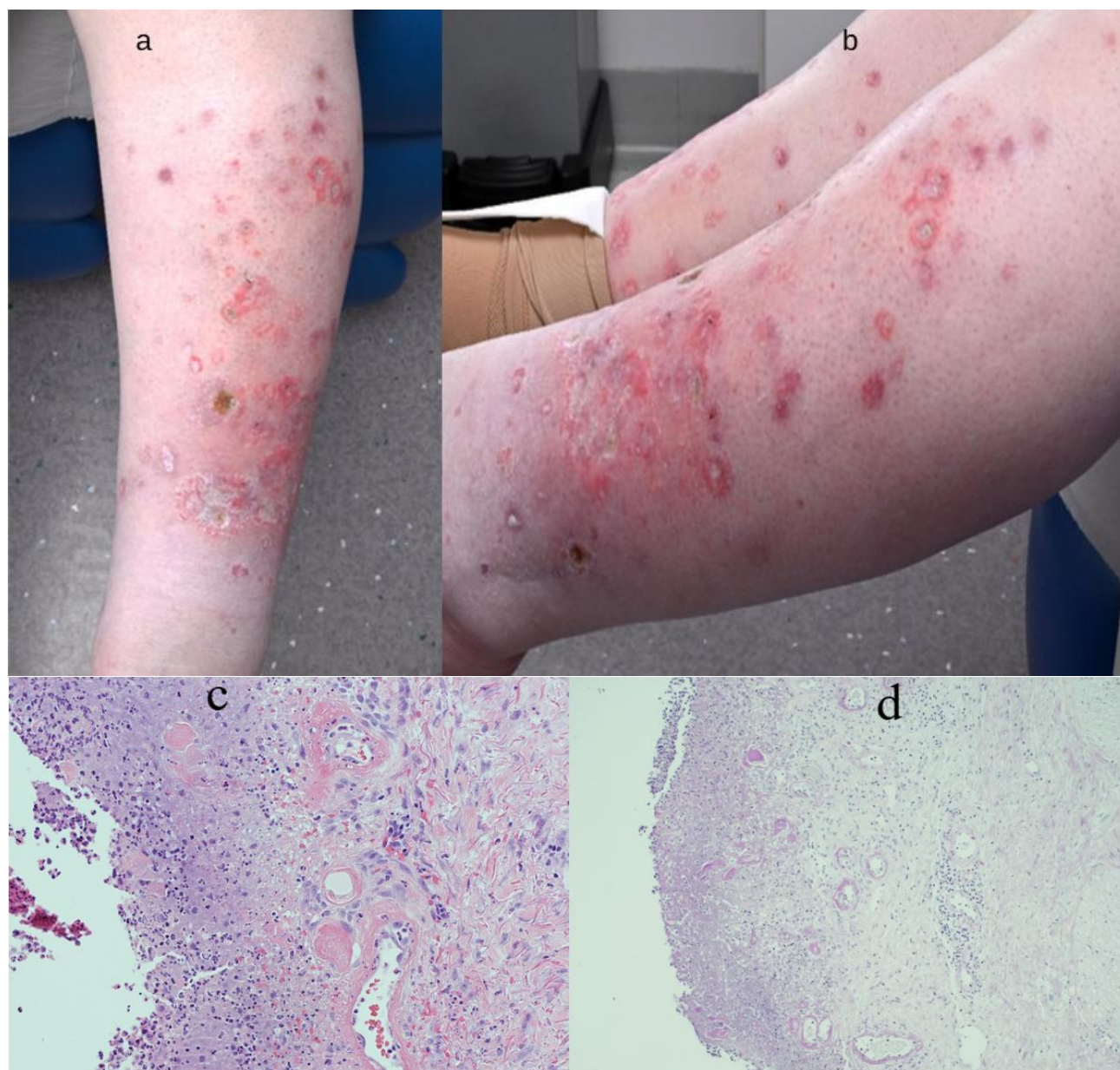


Figure 3: (a,b): Show punch out ulcers with an erythematous ring with white atrophic scarring at various places on both legs; (c): Skin erosion with livedoid vasculopathy, hyalinised material in wall and thrombi H & E 200X; (d): Skin erosion with livedoid vasculopathy, hyalinised material in wall and thrombi PASD 100X

Discussion

LV is a chronic, relapsing-remitting dermatosis characterized by micro-thrombosis of dermal vessels that leads to ischemic skin lesions and painful ulcerations of the lower limbs. It is a rare disease with an estimated incidence of 1:100,000 inhabitants per year in the United States (0) and predominantly affecting the middle-aged females, with a sex ratio of 3:1 [11,12].

The pathophysiology of Livedoid Vasculopathy (LV) is distinct from vasculitis but remains poorly understood. This includes disruptions in hemostasis, fibrinolysis defects, autoimmune conditions and rheological disorders [13]. These abnormalities contribute to a prothrombotic state, amplifying the risk of thrombosis and associated complications in LV [14]. Rather than being a unique disease, LV is considered a cutaneous manifestation of various prothrombotic disorders that disrupt one or more

components of Virchow's triad (13 & 14) which includes:

Blood Stasis: Linked to hyper-viscosity syndromes, such as chronic myeloid leukemia, heavy chain diseases and cryoglobulinemia.

Endothelial Injury: Seen in conditions such as systemic lupus erythematosus (especially with anti-cardiolipin antibodies or lupus anticoagulant), rheumatoid arthritis, scleroderma and hyperhomocysteinemia.

Hypercoagulable states: For instance, Leiden factor V mutation, deficiencies in proteins C, S and Z, antithrombin deficiency, elevated Plasminogen Activator Inhibitor type 1 (PAI-1) and lipoprotein(a).

LV can be classified as: Primary (idiopathic) or Secondary: Linked to various underlying mechanisms, such as -

- *Endothelial Dysfunction:* Promotes thrombosis through mechanisms like Nitric Oxide (NO) depletion, which induces vasoconstriction and platelet activation [15].
- *Blood Flow (Rheological) Disorders:* Includes cryoglobulinemia, cryofibrinogenemia and hyperhomocysteinemia.
- *Disorders of Haemostasis or Fibrinolysis:* Examples include antithrombin deficiency, protein C/S deficiency, Factor V Leiden mutation, G20210A prothrombin mutation and antiphospholipid antibodies.
- *Mixed Disorders:* Conditions involving overlapping mechanisms that exacerbate thrombotic risk
- Important differential diagnosis to be considered for LV include gangrenous pyoderma, especially when a secondary infection is present; factitious dermatitis, which presents only with ulcerations (without papules or vesicles); and cutaneous polyarteritis nodosa, which typically starts with painful subcutaneous nodules. Other differential diagnoses include leukocytoclastic vasculitis, pseudo-Kaposi sarcoma or Acroangiokeratitis of Mali, Degos disease and chronic venous stasis [6,16].

To confirm the diagnosis of livedoid vasculopathy and to exclude other entities in the differential diagnoses, biopsy can be helpful. Characteristic histological findings include vessel wall thickening with hyalinization and focal intraluminal thrombosis. These findings can be accompanied by red blood cell extravasation and scarce perivascular lymphocytic infiltration [17].

In the refractory LV, endothelial proliferation and intraluminal hyaline thrombi can be seen in the dermis. In the late-stage LV, scar tissue with obliterated vessels are seen [18-20]. Multiple biopsies could be necessary for definitive diagnosis, but this may cause complications in healing.

LV manifests painful punched out ulcers, livedoid changes, retiform/stellate purpura, white atrophic scars and telangiectasias [21]. These are usually seen on the lower extremities bilaterally; however, involvement of the upper extremities has also been reported. LV is characterized by the clinical triad of Livedo racemosa, very painful ulcers followed by healing as porcelain-white scars, the so-called Atrophie blanche [22]. LV may be accompanied by neuropathic pain secondary to sensitive polyneuritis [23]. Although the best approach to treatment is unclear, general measures (e.g., wound care, smoking cessation, compression and pain management) are important components of LV therapy along with pharmacological treatment. Patients should be encouraged to stop smoking because of the negative effects of smoking on wound healing. Compression therapy is also helpful in patients with venous insufficiency, due to the stimulating effect of compression on fibrinolytic activity and controlling edema. Pain secondary to livedoid vasculopathy can be severe. Nonsteroidal anti-inflammatory drugs tricyclic antidepressants, gabapentin, pregabalin, or carbamazepine may be preferred for neuropathic pain and are valuable for patients with persistent painful ulcerations [24]. The management of LV completely differs from that of vasculitis. Whereas the latter is based on immunosuppression, the treatment of LV is based mainly on antiplatelet drugs, heparins, antivitamin K, DOAC, or intravenous immunoglobulins for refractory cases [25,26].

IL-17 (Interleukin-17A) involvement has been proposed in the pathophysiology of livedoid vasculopathy and biological agents targeting IL-17A are being investigated as therapeutic options. However, despite its known prothrombotic and pro-inflammatory effects, the role of IL-17A remains controversial in the management of this condition [27]. Some studies have reported worsening of new-onset ulcers with uncontrolled pain because of initiating this therapy. It is also important to consider that certain factors, such as diet and vaccines, can impact the efficacy of anti-IL-17A treatments [28]. Another study suggests a limited role of IL-17A inhibition (e.g., Secukinumab) in the treatment of livedoid vasculopathy. At the same time, these studies contribute to a better understanding of the pathogenesis of livedoid vasculopathy, which may help explore further treatment options in the future [28].

Conclusion

Given the chronic and progressive nature of LV, early diagnosis is critical to prevent further complications, including chronic ulceration and scarring. The absence of clear guidelines underscores the urgent need for well-designed clinical trials and consensus-based management strategies to optimize patient outcomes and provide evidence-based recommendations for clinicians managing this challenging disease.

Conflicts of Interest

The authors have carried out the work on their own and the ICMJE form for Disclosure of Potential Conflicts of Interest have been submitted and none were declared.

References

1. Kerk N, Goerge T. Livedoid vasculopathy—a thrombotic disease. *Vasa*. 2013;313-22.
2. Eswaran H, Googe P, Vedak P, Marston WA, Moll S. Livedoid vasculopathy: A review with focus on terminology and pathogenesis. *Vascular Medicine*. 2022;27(6):593-603.
3. Qi F, Jin H. The potential role of tumor necrosis factor- α in thrombosis in livedoid vasculopathy. *Arch Dermatological Res*. 2024;316(5):124.
4. Bilgic A, Ozcobanoglu S, Bozca BC, Alpsoy E. Livedoid vasculopathy: A multidisciplinary clinical approach to diagnosis and management. *Int J Women's Dermatol*. 2021;7(5):588-99.
5. Freitas TQ, Halpern I, Criado PR. Livedoid vasculopathy: a compelling diagnosis. *Autopsy and Case Reports*. 2018;8(3):e2018034.
6. Criado PR, Rivitti EA, Sotto MN, Valente NY, Aoki V, Carvalho JF, et al. Livedoid vasculopathy: An intriguing cutaneous disease. *Anais brasileiros de dermatologia*. 2011;86:961-77.
7. Zhao C, Jing K, Feng S. Clinical analysis of skin lesions in livedoid vasculopathy: A study of 46 Chinese patients. 2023;62(2):212-6.
8. Pincelli MS, Echavarría AM, Criado PR, Marques GF, Morita TC, Valente NY, et al. Livedo racemosa: Clinical, laboratory and histopathological findings in 33 patients. *The Int J Lower Extremity Wounds*. 2021;20(1):22-8.
9. Gardner L. Vasculitis Update *Dermatol*. 2017;12(4):567-72.
10. Huot A, Maniu CM, Bogiatzi S, Hohl D, Alberio L, Stalder G. A case of livedoid vasculopathy: A thrombotic occlusive vasculopathy. *JEADV Clinical Practice*. 2022;1(1):45-8.
11. Criado PR, Rivitti EA, Sotto MN, de Carvalho JF. Livedoid vasculopathy as a coagulation disorder. *Autoimmunity Reviews*. 2011;10(6):353-60.
12. Di Giacomo TB, Hussein TP, Souza DG, Criado PR. Frequency of thrombophilia determinant factors in patients with livedoid vasculopathy and treatment with anticoagulant drugs—a prospective study. *J Euro Acad Dermatol Venereol*. 2010;24(11):1340-6.
13. Freitas TQ, Halpern I, Criado PR. Livedoid vasculopathy: A compelling diagnosis. *Autopsy and Case Reports*. 2018;8(3):e2018034.
14. Gardette E, Moguelet P, Bouaziz JD, Lipsker D, Dereure O, Le Pelletier F, et al. Livedoid vasculopathy: A French observational study including therapeutic options. *Acta Dermato-Venereologica*. 2018;98(9):842-7.
15. Bochenek ML, Schäfer K. Role of endothelial cells in acute and chronic thrombosis. *Hamostaseologie*. 2019;39(2):128-39.
16. Kerk N, Goerge T. Livedoid vasculopathy: A thrombotic disease. *Vasa*. 2013;42(5):317-22.
17. Bard JW, Winkelmann RK. Livedo vasculitis. Segmental hyalinizing vasculitis of the dermis. *Arch Dermatol*. 1967;96:489-99.
18. Qi F, Gao Y, Jin H. Identification of challenging diagnostic factors in livedoid vasculopathy: A retrospective study. *Clin Cosmet Investig Dermatol*. 2024;17:1747-56.
19. Alavi A, Hafner J, Dutz JP, Mayer D, Sibbald RG, Criado PR, et al. Livedoid vasculopathy: An in-depth analysis using a modified Delphi approach. *J Am Acad Dermatol*. 2013;69(6):1033-42.
20. Gonzalez-Santiago TM, Davis MD. Update of management of connective tissue diseases: Livedoid vasculopathy. *Dermatol Ther*. 2012;25:183-94.
21. Goerge T. Livedoid vasculopathy: Pathogenesis, diagnosis and treatment of cutaneous infarction. *Hautarzt*. 2011;62:627.
22. Burg MR, Mitschang C, Goerge T, Schneider SW. Livedoid vasculopathy: A diagnostic and therapeutic challenge. *Front Medicine*. 2022;9:1012178.

23. Toth C, Trotter M, Clark A, Zochodne D. Mononeuropathy multiplex in association with livedoid vasculitis. *Muscle Nerve*. 2003;28(5):634-9.
24. Micieli R, Alavi A. Treatment for livedoid vasculopathy: A systematic review. *JAMA Dermatol*. 2018;154(2):193-202.
25. Kofler K, Strölin A, Geiger V, Kofler L. Intravenous immunoglobulin therapy in livedoid vasculopathy: Retrospective observation of clinical outcome and patient's activity level. *J Cutan Med Surg*. 2021;25:504-10.
26. de Morales JM, Puig L, Daudén E, Cañete JD, Pablos JL, Martín AO, et al. Critical role of Interleukin (IL)-17 in inflammatory and immune disorders: An updated review of the evidence focusing in controversies. *Autoimmunity Reviews*. 2020;19(1):102429.
27. Qi F, Gao Y, Jin H. Anti-interleukin 17A biologic therapy attempts on livedoid vasculopathy: A report of case series. *Clin Cosmetic and Invest Dermatol*. 2024:1043-8.
28. Liu Y, Li T, Shi W. Janus kinase inhibitors and biologics for treatment of livedoid vasculopathy: A systematic review. *J Dermatological Treatment*. 2025;36(1):2451804.

Journal of Dermatology Research



Publish your work in this journal

Journal of Dermatology Research is an international, peer-reviewed, open access journal publishing original research, reports, editorials, reviews and commentaries. All aspects of dermatological health maintenance, preventative measures and disease treatment interventions are addressed within the journal. Dermatologists and other researchers are invited to submit their work in the journal. The manuscript submission system is online and journal follows a fair peer-review practices.

Submit your manuscript here: <https://athenaeumpub.com/submit-manuscript/>