

## Central Lancashire Online Knowledge (CLoK)

Title	Micro-computed tomography evaluation of dentinal microcracks following canal preparation with thermomechanically heat-treated engine-driven files
Type	Article
URL	<a href="https://clock.uclan.ac.uk/37820/">https://clock.uclan.ac.uk/37820/</a>
DOI	<a href="https://doi.org/10.1111/aej.12516">https://doi.org/10.1111/aej.12516</a>
Date	2021
Citation	Arumugam, Sharmini, Yew, Hsu Zenn, Baharin, Safura Anita, Zaman, Jasmina, Muchtar, Andanastuti and Kanagasingam, Shalini (2021) Micro-computed tomography evaluation of dentinal microcracks following canal preparation with thermomechanically heat-treated engine-driven files. <i>Australian Endodontic Journal</i> , 47 (3). pp. 520-530. ISSN 1329-1947
Creators	Arumugam, Sharmini, Yew, Hsu Zenn, Baharin, Safura Anita, Zaman, Jasmina, Muchtar, Andanastuti and Kanagasingam, Shalini

It is advisable to refer to the publisher's version if you intend to cite from the work.  
<https://doi.org/10.1111/aej.12516>

For information about Research at UCLan please go to <http://www.uclan.ac.uk/research/>

All outputs in CLoK are protected by Intellectual Property Rights law, including Copyright law. Copyright, IPR and Moral Rights for the works on this site are retained by the individual authors and/or other copyright owners. Terms and conditions for use of this material are defined in the <http://clock.uclan.ac.uk/policies/>



ORIGINAL RESEARCH

# Micro-computed tomography evaluation of dentinal microcracks following canal preparation with thermomechanically heat-treated engine-driven files

Dr. Sharmini Arumugam, BDS (PIDC, VMU), MFDS RCS (Eng)<sup>1</sup> ; Dr. Hsu Zenn Yew, DDS (UK Mal), DClinDent (Adelaide)<sup>1</sup> ; Associate Professor Dr. Safura Anita Baharin, DDS (Canada), MClintDent (Endodontology) (Lon), MFDS RCS (Eng), Grad-DipCDS (Lon)<sup>1</sup> ; Dr. Jasmina Qamaruz Zaman, BDS (Adelaide), MSc (restorative Dentistry) (Newcastle), MFDS RCS (Eng)<sup>1</sup> ; Professor Dr. Andanastuti Muchtar, B. Eng. (Hons) Mech Eng (Leeds), Ph.D (NUS)<sup>2</sup> ; and Dr. Shalini Kanagasingam, BDS (Mal), MClintDent Endodontology (Lon), MFDS RCS (Eng), MRD RCS (Edin), MFDS RCPS (Glasg), MRestDent RCPS (Glasg)<sup>3</sup>

1 Department of Restorative Dentistry, Faculty of Dentistry, The National University of Malaysia, Kuala Lumpur, Malaysia

2 Department of Mechanical & Manufacturing Engineering, Faculty of Engineering & Built Environment, The National University of Malaysia, Bangi, Malaysia

3 Faculty of Clinical and Biomedical Sciences, School of Dentistry, University of Central Lancashire, Preston, UK

## Keywords

dentinal defects, dentinal microcracks, nickel-titanium, root canal preparation, X-ray microtomography.

## Correspondence

Hsu Zenn Yew, Department of Restorative Dentistry, Faculty of Dentistry, The National University of Malaysia, Jalan Raja Muda Abdul Aziz, Kuala Lumpur 50300, Malaysia. Email: hz\_yew@ukm.edu.my

doi: 10.1111/aej.12516

(Accepted for publication 11 April 2021.)

We would like to affirm that we do not directly or indirectly have any financial relationships (e.g. employment, direct fees, stocks, retainers, consultancy, patent licensing or honorarium arrangements) or association in any corporate organisation which could influence the subject or materials mentioned in this manuscript. The authors do not have any interest to disclose.

The authors would like to declare that we have contributed significantly, and all authors are in agreement with the manuscript.

The sample collection was approved by the National University of Malaysia (UKM) ethics committee [UKM PPI/11/8/JEP-2018-513].

## Abstract

This study aimed to evaluate and compare the frequency of microcracks and its severity at different root canal dentin locations, after preparation with thermomechanically heat-treated engine-driven nickel-titanium instruments. Forty mandibular premolars were assigned to four experimental groups ( $n = 10$ ): ProTaper Next, ProTaper Gold, WaveOne Gold and Reciproc Blue. After pre-instrumentation micro-computed tomography scans, the root canals were prepared to size 25. Following post-instrumentation scans, pre- and post-instrumentation scanned images were analysed for the presence and extent of dentinal defects. A total of 56 500 cross-sectional images were obtained, showing that less than 2.3% with pre-existing dentinal microcracks. No new microcracks were identified during the post-instrumentation analyses. No significant association was found between the types of dentinal defects, file motions and sequences. Thermomechanically heat-treated rotary files did not induce the formation of new microcracks. There was also no association between the kinematic motions and sequences of the rotary instruments to the types of dentinal defects.

## Introduction

Chemo-mechanical root canal preparation is one of the more important steps in endodontic therapy aimed at

eliminating pathogenic microorganisms, dentinal debris and necrotic tissues before the placement of a root canal filling. For root canal preparation process, nickel-titanium is the most notable invention utilised to shape

the root canal. Engine-driven files have offered practitioners the added convenience of preparing the root canal system in a shorter time compared to the hand files (1). Apart from that, rotary files have been reported to improve the canal preparation by maintaining the original canal shape better than the manual preparation technique (2).

In various scientific research, dentinal defects following mechanical root canal preparation with motorised nickel-titanium (NiTi) instruments have been reported (3-5). The removal of dentin during canal preparation occurs when the files come into contact with the dentinal wall to produce the canal shape (6). However, the stress created during root canal instrumentation can potentially damage root dentin. One of the concerns of using rotary instruments is the formation of microcracks within the wall of the root canal due to constant contact by the rotating file inside the canal (7,8). Cassimiro *et al.* (9) proposed that repeated stress and occlusal forces may cause these microcracks and craze lines which could propagate, resulting in vertical root fracture, thereby leading to tooth loss. Wilcox *et al.* (10), in their *in vitro* study, supported the relationship between the application of force inflicted to the root canal wall and intrinsic morphological characteristics that can serve as a trigger point for vertical root fracture development. It was postulated that the more the dentinal structure is removed, the higher the risk of fracture. Over time, the extension of these dentinal defects could lead to microleakage and failure of root canal therapy. Microorganisms can proliferate to form bacterial biofilm on root surfaces through these dentinal defects, which can cause reinfection or persistent root canal infection (11).

In recent years, manufacturers have introduced files which have utilised the post-manufactured thermomechanical thermal treatment, claiming to have a positive impact on the super-elasticity property of NiTi files (12). These pre- and post-manufactured heat-treated files (ProTaper Next™ [Dentsply Maillefer, Ballaigues, Switzerland], ProTaper Gold™ [Dentsply Tulsa Dental Speciality, USA], WaveOne® Gold [Dentsply Maillefer, Ballaigues, Switzerland] and Reciproc® Blue [VDW, Munich, Germany]) have been shown to exhibit greater flexibility given the phase transformation behaviour of the file through heat treatment compared to conventional NiTi files (13).

It is speculated that the thermal treatment provided following the manufacturing of NiTi files considerably improves its strength and flexibility of the recently marketed files. For example, ProTaper Gold™, which undergoes two stages of gold heat treatment. Another generation of a heat-treated NiTi instrumentation system is the single-file system with a reciprocating kinematic

motion that involves the use of a single instrument to clean and shape the root canal. The WaveOne® Gold file (Dentsply Maillefer, Ballaigues, Switzerland) is a post-manufactured thermomechanical repeatedly heat-treated and cooled gold colour file. Furthermore, Reciproc® Blue (VDW, Munich, Germany) is a new type of heat-treated single-file system, having a unique blue colour due to the visible titanium oxide layer and the ability to maintain its given shape.

However, with all the proclaimed advantages of these files, questions remain over whether the increased flexibility of thermomechanical heat-treated files has an effect on the incidence of microcracks following canal preparation. Researchers have reported that the incidence of microcracks was decreased following canal preparation with increased flexibility of the reciprocating single-file system. This was mainly due to the lesser amount of induced stress on the canal wall (12,14). Therefore, it is important to highlight the frequency of microcracks following root canal preparation by these engine-driven files using a valid, reliable and reproducible method of micro-computed tomography (micro-CT) analysis (15,16).

Conflicting results have been reported when comparing the incidence of dentinal microcracks between reciprocating single-file systems with the rotary full-sequence system (8,17,18). Shantiaee *et al.* (18) reported that the reciprocating file system caused more cracks to occur compared to the continuous rotation system. Whereas, according to Aydin *et al.* (8), no differences in the frequency of microcracks were found between the two different kinematic motion of file types (8). Though, the question remains as to whether the newer generation rotary files with purportedly improved file design and metallurgy have a lower risk of dentinal crack formation.

To the best of the authors' knowledge, there are no micro-CT comparisons of microcrack formation following canal preparation using these recently marketed rotary systems, namely ProTaper Next™, ProTaper Gold™, WaveOne® Gold and Reciproc® Blue. Accordingly, this *in vitro* study aims to evaluate and compare the frequency of microcracks and its severity at different root canal dentin locations, following root canal preparation with different types of thermomechanically heat-treated engine-driven NiTi instruments, of different kinematic motions and sequences. The first null hypothesis was that there would be no significant differences in the frequency of microcrack formation between the groups at different root third locations. The second null hypothesis was that there would be no significant association between the types of dentinal defects and the types of kinematic motions and sequences.

## Materials and methods

This *in vitro* study was conducted at the Simulation and Dental Material Laboratory at the Faculty of Dentistry, National University of Malaysia, Kuala Lumpur. Ethical approval was obtained from the National University of Malaysia (UKM) ethics committee [UKM PPI/111/8/JEP-2018-513].

The study by Stringheta *et al.* (15) was used to estimate the effect size of this study. Sample size has been calculated using the G\*Power sample size software version 3.1.9.2 (19). The acceptable level of significance  $\alpha$  was set as 0.05, and the power of the study  $\beta$  was set as 95%. This study is expected to have at least 95% power to infer the result to the population with an effect size of 0.70. A sample size of 10 samples per group was used in this study.

### Sample selection

All samples were collected from patients aged between 20 to 40 years, indicated for either orthodontic purposes or advanced periodontal disease. Qualified general dental practitioners from government and private dental clinics collected the samples. These freshly extracted mandibular first and second premolars were immediately stored in distilled water upon extraction. The samples were collected within two weeks after extraction and disinfected in 0.1% thymol aqueous solution (Thymol 0.1% Aqueous Solution, Gouden Private Limited Company, Malaysia) for 24 h, maintained at a temperature less than 5°C (8).

The single-rooted, matured apices, straight root canals (<5°) and single foramen corresponding to the initial apical file size 20K-file™ (Dentsply Maillefer, Ballaigues, Switzerland) or less, having a tooth length between 19 mm and 22 mm was included in this study (20). Teeth with open apices, sclerosed canal or foramen, pulp stones, calcified canals, dilacerations, presence of external and internal resorptions, any form of caries, restorations, root treated teeth, tooth surface loss and external root surface cracks were excluded from this study.

The calculus on the selected tooth surface was gently debrided using an ultrasonic scaler. The presence of the external root surface cracks and external resorption was also inspected using a transilluminated light stereomicroscope (Leica Zoom 2000, Houston, TX) at a magnification of x30. Lastly, mesiodistal and buccolingual periapical radiographs were taken to determine that the tooth met the inclusion and exclusion criteria.

### Pre-instrumentation micro-CT analysis

Samples were initially dried for 2 h prior to the scanning procedure to remove any signs of moisture from the root canal dentin since it could affect the detection of dental microcracks when subjected to micro-CT analysis (21). A routine flat-field correction was performed before the actual scanning procedure to calibrate the sensitivity variations of camera pixels. The samples were then pre-scanned using a micro-CT scanner (SkyScan 1076; Bruker®, Kontich, Belgium) at a relatively low isotropic resolution (9 µm), 70 kV and 140 µA utilising a 1.0 mm aluminium filter. The teeth were stabilised perpendicular to the X-ray beam on a small polystyrene bed using masking tape to prevent any form of movement during the scanning procedure. The scanning was performed at a rotation of 360° around the vertical axis with a rotation step of 0.5°, camera exposure time of 2900 ms and frame averaging of 3 ms that yielded a scanning time of 2 h per sample. After two-dimensional image acquisition and projection, the cross sections were reconstructed employing the modified Feldkamp cone-beam reconstruction method from NRecon reconstruction software, version 1.7.0.4 (Bruker®, Kontich, Belgium). The procedure included a 40% beam-hardening correction, ring artefact correction of 10 and smoothing of 3 (15), resulting in 1100 to 1600 transverse cross sections per sample from the cemento-enamel junction to the apex of the sample in bitmap format.

### Root canal preparation

Each sample was wrapped with a single layer of aluminium foil around the root portion before embedding in wax boxes filled with auto-polymerising clear acrylic resin (Huge™ Self-Curing, Osmunda, Germany). Once the resin was set, the tooth was then removed, and the foil carefully peeled off. Light body vinyl polysiloxane impression material (Flexceed, GC Corporation, Japan) was manipulated and inserted into this space to simulate the periodontal ligament, and the tooth was then repositioned into the acrylic block (22).

Simple randomisation via [www.random.org](http://www.random.org) was performed to randomly allocate the samples into four experimental groups ( $n = 10$ ): ProTaper Gold™ (PTG), ProTaper Next™ (PTN), WaveOne® Gold (WOG) and Reciproc® Blue (RCPB). The apical patency of each sample was then confirmed with size 10K-file™ (Dentsply Maillefer Ballaigues, Switzerland) and the working length was measured by subtracting 1.0 mm from the length of the same file inserted into the canal from the reference cusp until the file was noticeable at the apical

foramen. The glide path was established with size 15K-file™ (Dentsply Maillefer, Ballaquies, Switzerland).

A single operator prepared the samples for all groups using a dental microscope at a magnification of x1.0 (Zeiss Opmi Pico, Germany). Each file was operated using X-smart plus a speed-controlled motor (Dentsply Tulsa Dental, Tulsa, US), using the contra-angle handpiece and 6:1 reduction ratio according to the manufacturer's recommended protocols. Each rotary file was used for four canals as specified by Hin *et al.* 2013, and all samples in the respective groups were prepared up to an apical size of #25 (23).

#### ProTaper Gold™ (PTG)

SX (#19/0.04), S1 (#18/0.02) and S2 (#20/0.04) were used at 300 rpm with a torque of 3 Ncm for SX and S1 and 1.5 Ncm for S2 in sequence with a brushing motion at the coronal, two-thirds of working length. The S1 and S2 files were brought up to the working length after apical gauging was performed while F1 (#20/0.07), followed by the F2 file (#25/0.08), was brought up to the working length in a 'non-brushing' motion used at 300 rpm with a torque of 1.5 Ncm for F1 and 3 Ncm for F2.

#### ProTaper Next™ (PTN)

The X1 (#17/0.04) file was used followed by X2 (#25/0.08) in a brushing motion away from the canal at 300 rpm with a torque of 2.0 Ncm.

#### WaveOne® Gold (WOG)

Primary single-file (#25/0.07) was used under 'WAVEONE ALL' setting applying gentle inward pressure. The coronal two-third was pre-enlarged with an outwards brushing motion followed by preparing the working length with in-and-out pecking movements.

#### Reciproc Blue® Gold (RCPB)

The R25 (#25/0.08) single-file was used to prepare the coronal two-thirds of the canal applying gentle apical pressure with brushing motion under the setting of 'RECIPROC'. The same file was used to complete the preparation up to working length.

#### General procedure performed for all groups after root canal preparation

During preparation, the apical root portion of all samples was soaked in distilled water to prevent dehydration. The experimental samples were irrigated with 5 ml of 3%

sodium hypochlorite solution (CanalPro®, Coltene, Whaledent, USA) between each file change or every three pecking motions. The samples were then irrigated with 2 ml normal saline solution and dried with sterile paper points. After manipulation, all samples were returned to the distilled water-filled containers.

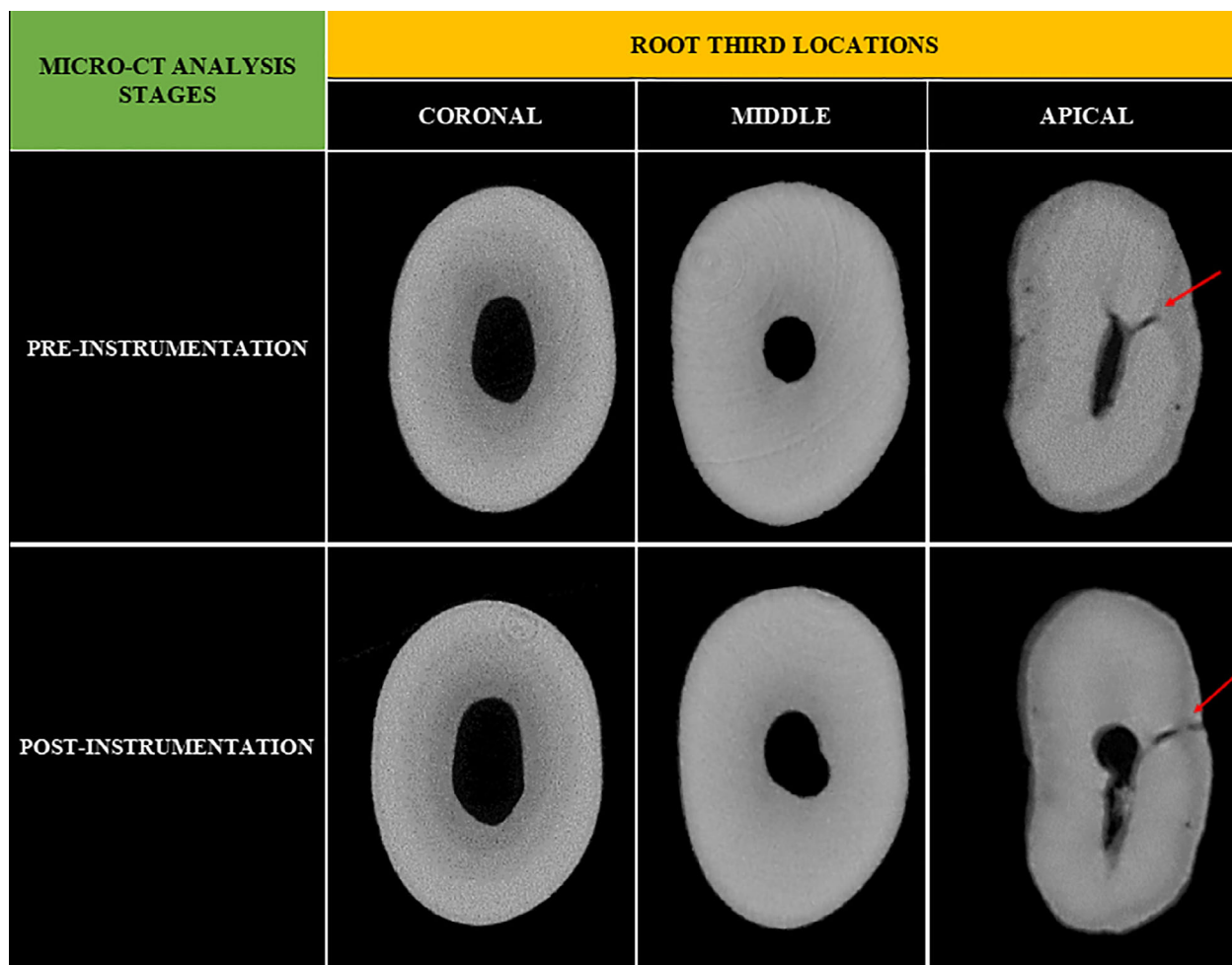
#### Dentinal microcrack evaluation

Post-instrumentation micro-CT scanning and reconstruction parameters were identical with the pre-instrumentation. The data viewer programme (version 1.5.1, [Bruker, Belgium]) aligned the analysis of the micro-CT images. Coronal, sagittal and axial two-dimensional images were obtained for each sample, resulting in 113 000 cross-sectional images. During the analysis of the post-instrumentation images, the frequency of cross section images displaying microcracks or craze lines was reported as coronal, middle and apical. The corresponding pre-instrumentation cross-sectional image was subsequently compared and analysed to verify the presence of pre-existing microcracks or craze lines in the post-instrumentation image.

Simultaneously, the three-dimensional model using the CTvox programme (version 3.2.0, [Bruker®, Belgium]) was also created to visualise the identical position of virtual samples, to verify the presence of any crack lines previously observed. All samples were blind evaluated by concealment of allocated samples into instrument groups. Single (intra) and double-blinded independent (inter) observers (endodontist as gold standard and specialist trainee) examined the validity of the images within a two-week interval. The types of defects observed were scored as; Score 1: craze line (line extending from the outer surface into the dentin but not reaching the canal lumen), Score 2: incomplete crack (a line from the canal wall into the dentin without reaching the outer surface of the root) and Score 3: complete crack (a line from the canal wall to the outer surface of the root) (24). The inter-observer disagreement was resolved by re-evaluating the images and through discussion.

#### Statistical analyses

The number of pre-instrumentation and post-instrumentation microcracks was determined as a percentage for each group according to the different root third locations. Statistical analyses for this study were carried out using IBM's 'Statistical Package for the Social Sciences' (SPSS®) software (version 25; [IBM, Chicago, IL]). Intra and inter-rater reliability were analysed using Cohen's kappa ( $\kappa$ ) test in 10% of the sample. McNemar test was applied to determine the significant differences



**Figure 1** Representative cross-sectional images, showing the existence of dentinal microcrack (red arrows) pre-instrumentation and post-instrumentation with ProTaper Gold™.

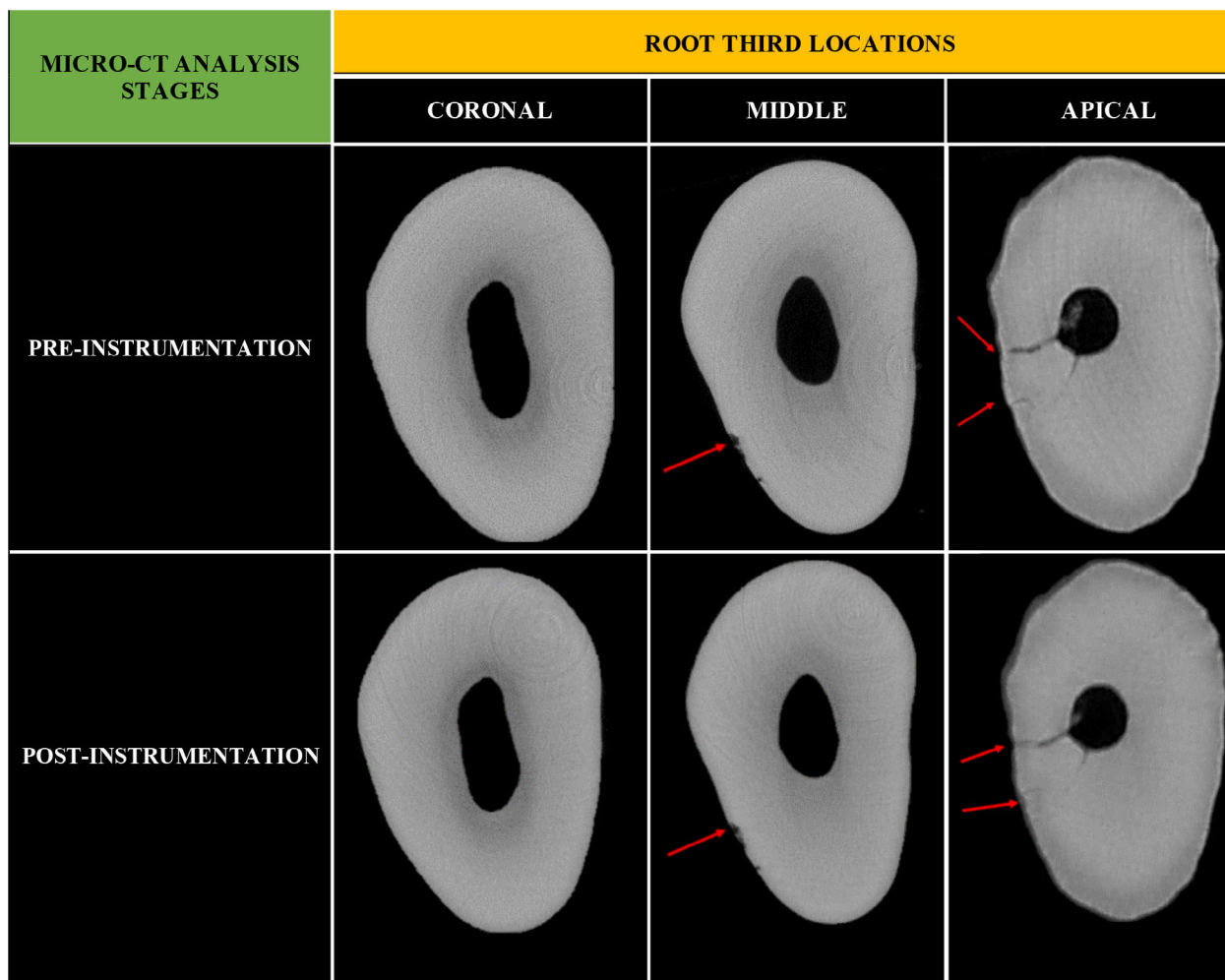
before and after instrumentation, and Fisher's Exact test was undertaken to associate the types of dentinal defects propagated with different types of file motions and sequences. The level of significance was set to  $P < 0.05$ .

## Results

The intra- and inter-rater reliability was excellent ( $\kappa = 0.86$ , [95% CI,  $0.86 \pm 0.19$ ],  $P < 0.001$ ). A total of 40 samples were scanned pre- and post-instrumentation. The pre-instrumentation scans showed the presence of dentinal microcracks in 16.7% ( $n = 5$ ), 13.3% ( $n = 4$ ), 13.3% ( $n = 4$ ) and 13.3% ( $n = 4$ ) of samples in the PTG, PTN, WOG and RCPB groups, respectively. A total of 56 500 cross-sectional pre-instrumentation images were obtained, showing that less than 2.3% of slices with dentinal microcracks. It is also worthy to note that, all groups had pre-existing cracks in the middle and apical root third regions (Figs 1–4). However, while craze line

defects and complete cracks were seen in both locations, no cracks were detected in the coronal third of all the samples.

In the post-instrumentation analysis, the frequency of microcracks at apical and middle root third remained unchanged following canal preparation for all groups. Regarding the slices of microcracks, in the middle region, only the PTN group showed an insignificant increase of 0.2% [ $P = 1.000$ ]. In the apical region, both PTN and WOG groups produced an increase of 0.1% and 0.2% [ $P = 1.000$ ] individually (refer to Table 1). The apical location of PTG and PTN groups as shown in Figures 1 and 2 depicts the complete cracks. The craze line type of defect is showed at the middle and apical locations of WOG and RCPB groups as represented in Figures 3 and 4. The types of dentinal defects observed in the post-instrumentation analysis corresponded to the pre-instrumentation scans with all the systems.



**Figure 2** Micro-CT images ProTaper Next™ file group showing the existence of pre-instrumentation and post-instrumentation dentinal defects (red arrows).

Further analysis showed that there were no statistically significant differences between all the four rotary systems tested. The association between the types of dentinal defects and the rotary systems (continuous rotation full-sequence versus reciprocating single-file) ( $n = 120$ ) is shown in Table 2. The result indicates no significant association between the types of dentinal defects, file motions and sequences [ $\chi^2(2) = 0.2, P > 0.975$ ].

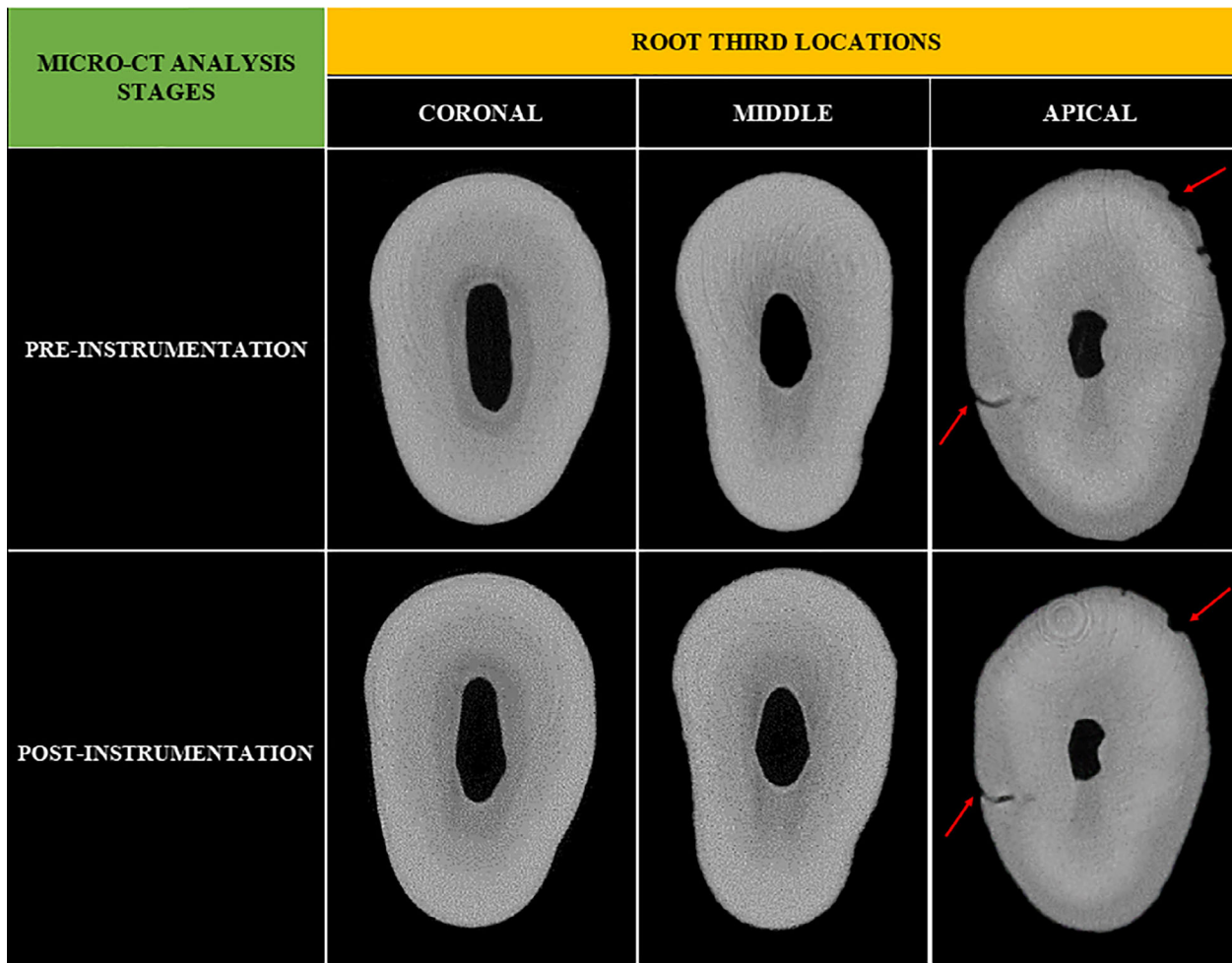
## Discussion

This research aimed to compare the microcrack incidences during the biomechanical preparation of a root canal using different thermomechanically heat-treated rotary files with different kinematic motions and sequences. The first null hypothesis was accepted given there were no significant differences observed in the

frequency of microcrack formation among the groups at different root third locations. This result is corroborated by Aksoy et al. (3), who found that there were no significant differences in the incidence of dentinal defects at apical, middle and coronal using Reciproc® Blue. Similarly, in the studies conducted by Bayram et al. and De-Deus et al. (25,26), ProTaper™ file systems were found not to form new dentinal microcracks. For the WOG group, identical findings were also reported by Aydin et al. (8).

Although all the file systems used in this present study have different tapers, cross-sectional designs and metallurgy, these parameters seem not to affect the development and propagation of microcracks. Nevertheless, most crack propagation was found in the apical region for PTN and WOG groups only. This observation could be due to the anatomical configuration of the canal at the apical





**Figure 3** Representative cross-sectional images, showing the existence of dentinal microcrack (red arrows), pre-instrumentation and post-instrumentation with WaveOne<sup>®</sup> Gold group.

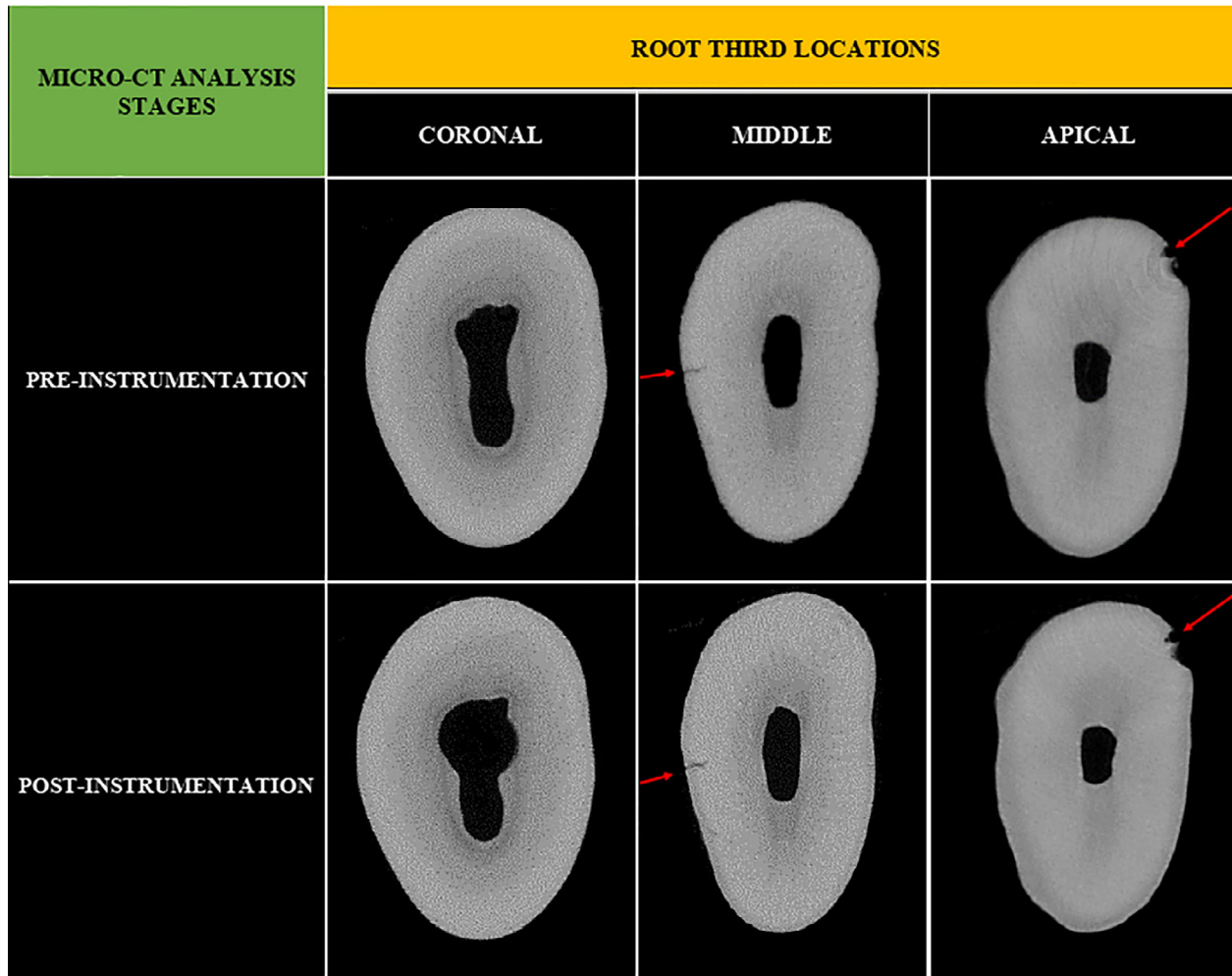
part (narrow and smaller lumen size), resulting in extra contact with the instrument during preparation. In addition, it could be speculated that the rectangular and parallelogram cross section of the above-mentioned files may contribute to the worsening of the cracks. Surprisingly, files with larger apical taper (PTG and RCPB) did not influence the development and propagation of cracks at that region.

On the other hand, contradictory findings were reported in several studies where the high frequency of microcracks was noted after canal preparation (5,7,27). The conventional sectioning and stereomicroscope analysis were utilised in these studies. One of the drawbacks of this method is the potential dentinal defect formation induced by the sectioning procedure itself. Furthermore, the presence of pre-instrumentation microcracks could not be identified via this technique. The present study utilised the non-destructive high-resolution micro-CT

technology, in order to enable visualisation of pre-existing dentinal defects at pre- and post-instrumentation stages, thereby enhancing the internal validity of the experiment. Seventeen samples were identified to have pre-existing dentinal microcracks through micro-CT imaging. This finding may be attributed to factors such as the extraction process, the ultrasonic removal of calculus during the tooth preparation procedure, storage medium and sterilisation methods (28).

The current study employed a higher scanning resolution at 9  $\mu\text{m}$ , which agrees with Huang *et al.* (29), who suggested the superiority of using higher micro-CT scan resolution for examining the probabilities of microcracks leading to vertical root fracture. High-resolution micro-CT scanning can yield several hundred thousand slices, which may prevent the risk of disregarding the dentinal defect. In the present study, microscopic crack propagation was detected in the post-instrumentation slices.





**Figure 4** Representative cross-sectional images, showing the existence of dentinal microcracks (red arrows), both pre-instrumentation and post-instrumentation with Reciproc® Blue group.

**Table 1** Number and percentage of roots and slices with microcracks according to different micro-CT analysis stages between four groups of instruments tested across different root third locations

Group	Root third location	Samples with microcracks (%)		Total slices	Slices of microcracks (%)	
		Pre-instrumentation	Post-instrumentation		Pre-instrumentation	Post-instrumentation
PTG	C	0 (0)	0 (0)	4900	0 (0.0)	0 (0.0)
	M	1 (10)	1 (10)	4900	21 (0.4)	21 (0.4)
	A	4 (40)	4 (40)	4900	95 (2.0)	96 (2.0)
PTN	C	0 (0)	0 (0)	4588	0 (0.0)	0 (0.0)
	M	2 (20)	2 (20)	4588	68 (1.5)	77 (1.7)
	A	2 (20)	2 (20)	4588	49 (1.1)	56 (1.2)
WOG	C	0 (0)	0 (0)	4592	0 (0.0)	0 (0.0)
	M	2 (20)	2 (20)	4592	48 (1.3)	49 (1.3)
	A	2 (20)	2 (20)	4592	111 (2.3)	121 (2.5)
RCPB	C	0 (0)	0 (0)	4753	0 (0.0)	0 (0.0)
	M	1 (10)	1 (10)	4753	41 (0.8)	41 (0.8)
	A	3 (30)	3 (30)	4753	104 (2.2)	107 (2.2)

A, Apical; C, Coronal; M, Middle; PTG, ProTaper Gold™; PTN, ProTaper Next™; RCPB, Reciproc® Blue; WOG, WaveOne® Gold.

**Table 2** Association between the types of dentinal defects and two different types of file motions and sequences of systems

Motions and Sequences	Score 1 (Craze line)		Score 2 (Incomplete crack)		Score 3 (Complete crack)		$\chi^2$ (df)	P-value
	n	(%)	n	(%)	n	(%)		
Continuous rotation full-sequence files	1	(33.3)	0	(0.0)	2	(66.7)	0.2 (2)	>0.975
Reciprocating single-files	2	(50.0)	0	(0.0)	2	(50.0)		

However, there was no progression in the severity of dentinal defects. The clinical significance of these microscopic changes in the dentinal defects is yet to be determined.

The second null hypothesis was also accepted, as there was no significant association between the types of dentinal defects and types of file motions and sequences. This finding is in line with previous micro-CT studies which disproved the association of the dentinal defects and different kinematic motions of NiTi systems (28,30). It is interesting to note that, studies which reported contrasting results employed the traditional sectioning method (31). For the reasons explained above, the cracks seen may result from the sample preparation instead of the effect of the file motion or sequence. However, in the present study, the higher percentage of the craze line defect was demonstrated in samples prepared with reciprocating single-file systems. The screwing effect of the single, largely tapered instrument in the above systems is thought to contribute to the formation of microcracks during the preparation of the root canal, especially at the apical part of the root (18).

This study could only be applied to teeth with reduced root curvature. Hence, the data obtained from this study should be carefully extrapolated to clinical situations where complex canal anatomy may be present. Moreover, the current study only analysed the formation of crack after a single stage of the endodontic procedure. Other endodontic stages, such as obturation and post-space preparation, may contribute to crack initiation (32,33).

## Conclusion

Within the limitations of this study, it can be concluded that biomechanical canal preparation with the thermomechanically heat-treated rotary files did not induce the formation of new microcracks. Additionally, only negligible microscopic crack propagation was detected upon close examination of micro-CT slices which may be clinically insignificant. It also appears that the use of the tested rotary systems did not worsen the pre-existing cracks. No association was

determined between the kinematic motions and sequences of the rotary instrument with regards to the types of dentinal defects observed on the extracted mandibular premolars. Therefore, the selection of the rotary file systems to be used in a clinical setting would depend on other factors such as shaping ability, cost and clinician preference.

## Acknowledgements

This work was supported by the provision of funding from the National University of Malaysia Research Grant [grant number GUP-2018-051]. The authors would like to acknowledge Associate Professor Dr Lau Seng Fong from the Faculty of Veterinary Medicine, University Putra Malaysia, Serdang, Malaysia, for her guidance and expertise on diagnostic imaging of micro-CT. The authors would also like to acknowledge Mr Y.S. Chan, Senior Service Engineer from Interscience Sdn Bhd® (Bruker®, Kontich, Belgium)'s technical team who provided technical assistance and guidance during the scanning and reconstruction procedure.

## References

1. Pasqualini D., Scotti N., Tamagnone L., Ellena F., Berutti E. Hand-operated and rotary ProTaper instruments: a comparison of working time and number of rotations in simulated root canals. *J Endod* 2008; 34: 314–7.
2. Sonntag D., Delschen S., Stachniss V. Root-canal shaping with manual and rotary Ni-Ti files performed by students. *Int Endod J* 2003; 36: 715–23.
3. Aksoy Ç., Keriş E. Y., Yaman S. D., Ocak M., Geneci F., Çelik H. H. Evaluation of XP-Endo Shaper, Reciproc Blue, and ProTaper Universal NiTi systems on dentinal microcrack formation using micro-computed tomography. *J Endod* 2019; 45: 338–42.
4. Mandava J., Yelisela R. K., Arikatla S. K., Ravi R. C. Micro-computed tomographic evaluation of dentinal defects after root canal preparation with hyflex edm and vortex blue rotary systems. *Journal of Clinical and Experimental Dentistry*. 2018; 0–0. <http://dx.doi.org/10.4317/jced.54853>

5. Saxena D., Saha S. G., Vijaywargiya N., Saha M. K., Bharadwaj A., Dubey S. Evaluation of the incidence of microcracks caused by Mtwo and ProTaper next rotary file systems versus the self-adjusting file: A scanning electron microscopic study. *Journal of Conservative Dentistry*. 2017; 20: 5: 355. [http://dx.doi.org/10.4103/jcd.jcd\\_70\\_17](http://dx.doi.org/10.4103/jcd.jcd_70_17)
6. Rose E., Svec T. An Evaluation of Apical Cracks in Teeth Undergoing Orthograde Root Canal Instrumentation. *Journal of Endodontics*. 2015; 41: 12: 2021–2024. <http://dx.doi.org/10.1016/j.joen.2015.08.023>
7. Bürklein S., Tsotsis P., Schäfer E. Incidence of dentinal defects after root canal preparation: reciprocating versus rotary instrumentation. *J Endod* 2013; 39: 501–4.
8. Aydın Z. U., Keskin N. B., Özyürek T. Effect of Reciproc Blue, XP-Endo shaper, and WaveOne Gold instruments on dentinal microcrack formation: a micro-computed tomographic evaluation. *Microsc Res Tech* 2019; 82: 856–60.
9. Cassimiro M., Romeiro K., Gominho L., de Almeida A., Silva L., Albuquerque D. Effects of Reciproc, ProTaper Next and WaveOne Gold on root canal walls: a stereomicroscope analysis. *Iran Endod J* 2018; 13: 228–33. <http://www.ncbi.nlm.nih.gov/pubmed/29707020>
10. Wilcox L. R., Roskelley C., Sutton T. The relationship of root canal enlargement to finger-spreader induced vertical root fracture. *J Endod* 1997; 23(23): 533–4.
11. Siqueira J. F., Rôças I. N. Clinical Implications and Microbiology of Bacterial Persistence after Treatment Procedures. *Journal of Endodontics*. 2008; 34: 11: 1291–1301.e3. <http://dx.doi.org/10.1016/j.joen.2008.07.028>
12. Bayram H. M., Bayram E., Ocak M., Uzun M. B., Geneci F., Celik H. H. Micro-computed Tomographic Evaluation of Dentinal Microcrack Formation after Using New Heat-treated Nickel-titanium Systems. *Journal of Endodontics*. 2017; 43: 10: 1736–1739. <http://dx.doi.org/10.1016/j.joen.2017.05.024>
13. Yahata Y., Yoneyama T., Hayashi Y., Ebihara A., Doi H., Hanawa T., Suda H. Effect of heat treatment on transformation temperatures and bending properties of nickel-titanium endodontic instruments. *International Endodontic Journal*. 2009; 42: 7: 621–626. <http://dx.doi.org/10.1111/j.1365-2591.2009.01563.x>
14. Abou El Nasr H. M., Abd El Kader K. G. Dentinal Damage and Fracture Resistance of Oval Roots Prepared with Single-file Systems Using Different Kinematics. *Journal of Endodontics*. 2014; 40: 6: 849–851. <http://dx.doi.org/10.1016/j.joen.2013.09.020>
15. Stringheta C. P., Pelegrine R. A., Kato A. S., Freire L. G., Iglecias E. F., Gavini G., Bueno C. E. S. Micro-computed Tomography versus the Cross-sectioning Method to Evaluate Dentin Defects Induced by Different Mechanized Instrumentation Techniques. *Journal of Endodontics*. 2017; 43: 12: 2102–2107. <http://dx.doi.org/10.1016/j.joen.2017.07.015>
16. De-Deus G., Cavalcante D. M., Belladonna F. G., Carvalhal J., Souza E. M., Lopes R. T., Versiani M. A., Silva E. J. N. L., Dummer P. M. H. Root dentinal microcracks: a post-extraction experimental phenomenon?. *International Endodontic Journal*. 2019; 52: 6: 857–865. <http://dx.doi.org/10.1111/iej.13058>
17. Ahn S., Kim H., Kim E. Kinematic Effects of Nickel-Titanium Instruments with Reciprocating or Continuous Rotation Motion: A Systematic Review of In Vitro Studies. *Journal of Endodontics*. 2016; 42: 7: 1009–1017. <http://dx.doi.org/10.1016/j.joen.2016.04.002>
18. Shantiaee Y., Dianat O., Mosayebi G., Namdari M, Tordik P. Effect of root canal preparation techniques on crack formation in root dentin. *J Endod* 2019; 45: 447–52.
19. Faul F., Erdfelder E., Lang A., Buchner A. G\*Power 3: A flexible statistical power analysis program for the social, behavioral, and biomedical sciences. *Behavior Research Methods*. 2007; 39: 2: 175–191. <http://dx.doi.org/10.3758/bf03193146>
20. Schneider Sam W. A comparison of canal preparations in straight and curved root canals. *Oral Surgery, Oral Medicine, Oral Pathology*. 1971; 32: 2: 271–275. [http://dx.doi.org/10.1016/0030-4220\(71\)90230-1](http://dx.doi.org/10.1016/0030-4220(71)90230-1)
21. Rödiger T., Müller C., Hoch M., Haupt F., Schulz X., Wiegand A., Rizk M. Moisture content of root canal dentine affects detection of microcracks using micro-computed tomography. *International Endodontic Journal*. 2018; 51: 3: 357–363. <http://dx.doi.org/10.1111/iej.12850>
22. Adorno C. G., Yoshioka T., Suda H. The effect of working length and root canal preparation technique on crack development in the apical root canal wall. *International Endodontic Journal*. 2010; 43: 4: 321–327. <http://dx.doi.org/10.1111/j.1365-2591.2010.01684.x>
23. Hin E. S., Wu M., Wesselink P. R., Shemesh H. Effects of Self-Adjusting File, Mtwo, and ProTaper on the Root Canal Wall. *Journal of Endodontics*. 2013; 39: 2: 262–264. <http://dx.doi.org/10.1016/j.joen.2012.10.020>
24. Monga P., Bajaj N., Mahajan P., Garg S. Comparison of incidence of dentinal defects after root canal preparation with continuous rotation and reciprocating instrumentation. *Singapore Dental Journal*. 2015; 36: 29–33. <http://dx.doi.org/10.1016/j.sdj.2015.09.003>
25. Bayram H. M., Bayram E., Ocak M., Uygun A. D., Celik H. H. Effect of ProTaper Gold, Self-Adjusting File, and XP-endo Shaper Instruments on Dentinal Microcrack Formation: A Micro-computed Tomographic Study. *Journal of Endodontics*. 2017; 43: 7: 1166–1169. <http://dx.doi.org/10.1016/j.joen.2017.02.005>
26. De-Deus G., Belladonna F. G., Souza E. M., Silva E. J. N. L., Neves A. A., Alves H., Lopes R. T., Versiani M. A. Micro-computed Tomographic Assessment on the Effect of ProTaper Next and Twisted File Adaptive Systems on Dentinal Cracks. *Journal of Endodontics*. 2015; 41: 7: 1116–1119. <http://dx.doi.org/10.1016/j.joen.2015.02.012>

27. Kesim B., Sagsen B., Aslan T. Evaluation of dentinal defects during root canal preparation using thermomechanically processed nickel-titanium files. *European Journal of Dentistry*. 2017; 11: 02: 157–161. [http://dx.doi.org/10.4103/ejd.ejd\\_254\\_16](http://dx.doi.org/10.4103/ejd.ejd_254_16)
28. De-Deus G., Silva E. J. N. L., Marins J., Souza E., Neves A. A., Gonçalves Belladonna F., Alves H., Lopes R. T., Versiani M. A. Lack of Causal Relationship between Dentinal Microcracks and Root Canal Preparation with Reciprocation Systems. *Journal of Endodontics*. 2014; 40: 9: 1447–1450. <http://dx.doi.org/10.1016/j.joen.2014.02.019>
29. Huang C. C., Chang Y. C., Chuang M. C., Lin H. J., Tsai Y. L., Chang S. H., Chen J. C., Jeng J. H. Analysis of the Width of Vertical Root Fracture in Endodontically Treated Teeth by 2 Micro-Computed Tomography Systems. *Journal of Endodontics*. 2014; 40: 5: 698–702. <http://dx.doi.org/10.1016/j.joen.2013.12.015>
30. De-Deus G., César de Azevedo Carvalhal J., Belladonna F. G., Silva E. J. N. L., Lopes R. T., Moreira Filho R. E., Souza E. M., Provenzano J. C., Versiani M. A. Dentinal Microcrack Development after Canal Preparation: A Longitudinal in Situ Micro-computed Tomography Study Using a Cadaver Model. *Journal of Endodontics*. 2017; 43: 9: 1553–1558. <http://dx.doi.org/10.1016/j.joen.2017.04.027>
31. Ashwinkumar V., Krithikadatta J., Surendran S., Velmugan N. Effect of reciprocating file motion on microcrack formation in root canals: an SEM study. *International Endodontic Journal*. 2014; 47: 7: 622–627. <http://dx.doi.org/10.1111/iej.12197>
32. Nikhil V., Singh V., Bansal P. Induction of dentinal microcracks during postspace preparation: A comparative microcomputed tomography study. *Journal of Conservative Dentistry*. 2018; 21: 6: 646. [http://dx.doi.org/10.4103/jcd.jcd\\_227\\_18](http://dx.doi.org/10.4103/jcd.jcd_227_18)
33. Azmaz N., Aydinbelge H., Yilmaz M. Dentinal crack formation after different obturation techniques. *Saudi Journal of Oral Sciences*. 2019; 6: 1: 3. [http://dx.doi.org/10.4103/sjos.sjoralsci\\_2\\_18](http://dx.doi.org/10.4103/sjos.sjoralsci_2_18)