



Contents lists available at ScienceDirect

JPRAS Open

journal homepage: www.elsevier.com/locate/jpra

Correspondence

Indications for the DIEP flap in extra-mammary complex wounds: From head to extremity reconstruction

Lay summary

Free tissue transplant taken from the lower abdomen provides large volumes of tissue with a hidden donor site scar. These characteristics allow it to be used for reconstruction of many sites and defects other than the breast. We describe the use of the flap in a variety of clinical settings focusing on technical considerations.

Dear Editor,

Introduction

The deep inferior epigastric perforator (DIEP) flap^{1,2} is the gold standard for autologous breast reconstruction because it provides large volumes of skin and subcutaneous tissue, leaving the patient with minimal donor site morbidity, concealed scars, and the benefits of an abdominoplasty. Its long pedicle and reliable vascular anatomy allow for its easy positioning in congenital, post-traumatic and post-radiotherapy defects where there may be no reliable adjacent recipient vessels. In this case series, we report on the use of the DIEP flap for reconstruction of a wide variety of extra-mammary sites to underline its versatility.

Case presentations

Between 2009 and 2024, we undertook seven non-breast DIEP flap reconstructions (Table 1). All patients underwent pre-operative computed tomography angiogram for mapping of DIEP flap perforators and suitability of lower limb recipient vessels. For the upper limbs, an Allen's test was undertaken. In raising the flaps, we harvested the pedicle up to its origin and the maximum possible length of the superficial inferior epigastric veins (SIEV). There were no flap failures.

Due to concerns about the bulk of the flaps and the risk of vascular compromise, the recipient sites underwent delayed closure for patients two, three, five, and six. On post-operative day-1, patient one was returned to theatre owing to venous flap congestion which was rescued by an additional anastomosis—SIEV to posterior tibial artery venae comitantes via a long saphenous vein graft. Despite the use of a DIEP flap for reconstruction, the lower limb defects for patients one to three were so large that they still had deficiencies of skin and soft-tissue after flap inset. Therefore, the DIEP skin-paddles of these patients were expanded after transfer. Patient two underwent placement and inflation of their right popliteal fossa expander without issue. One of the two expanders placed within patient three's forearm was removed after 1 month due to extrusion. Patient one also underwent a series

<https://doi.org/10.1016/j.jpra.2025.03.008>

2352-5878/© 2025 The Author(s). Published by Elsevier Ltd on behalf of British Association of Plastic, Reconstructive and Aesthetic Surgeons. This is an open access article under the CC BY-NC-ND license (<http://creativecommons.org/licenses/by-nc-nd/4.0/>)

Table 1

Case information for patients undergoing free deep inferior epigastric perforator flap reconstruction

Patient #	Age (years)/ Gender	Aetiology	Defect	Anastomoses	Complications	Secondary procedures	Follow-up (months)
1	31 F	RTA, burns	L leg circumferential secondary skin graft contracture and unstable graft	R DIEA e2s posterior tibial a. R DIEV e2e posterior tibial a. vc + e2e distal superficial leg v. L DIEV with v. graft (R SSV) e2e proximal superficial leg v. R SIEV with v. graft (R LSV) e2e posterior tibial a. vc (5 anastomoses)	Venous congestion – additional anastomosis (SIEV to posterior tibial a. vc) Fat necrosis – debridement + skin graft	Tissue expansion Flap thinning Umbilicoplasty Free ALT flap (right donor) to anterior knee	185
2	43 M	RTA	R distal thigh / popliteal fossa secondary skin graft contracture; leg extension deficit	R + L DIEA e2s SFA R + L DIEV e2e SFA vc (4 anastomoses)	Discharging sinus – negative exploration	Delayed inset Tissue expansion External distraction frame to knee	28
3	53 M	Burns	R hand / forearm secondary skin graft contracture; hypertrophic scarring, forearm extension deficit, webspace creep	L DIEA e2s radial a. L DIEV e2s cephalic v. + e2e superficial radial v. R DIEA e2s brachial a. R DIEV e2s basilic v. (5 anastomoses)	-	Delayed inset Tissue expansion Flap thinning Webspace releases	50
4	68 M	Sarcoma	R dorsal forearm wide local excision (Figure 1)	L DIEA e2s radial a. L DIEV e2e radial a. vc (2.5 mm coupler) + e2e cephalic v. branch (2.5 mm coupler) L SIEV e2e basilic v. branch (2.0 mm coupler) R SIEV e2e cephalic v. branch (2.0 mm coupler) (5 anastomoses)	-	Flap thinning Tendon transfer – index to middle finger EDC	6

(continued on next page)

Table 1 (continued)

Patient #	Age (years)/ Gender	Aetiology	Defect	Anastomoses	Complications	Secondary procedures	Follow-up (months)
5	73 F	Necrotising fasciitis	R olecranon unstable skin graft	R DIEA e2s brachial a. R DIEV e2s radial a. vc R DIEV e2e radial a. vc (3 anastomoses)	Wound breakdown – conservative management	Delayed inset + skin graft Flap thinning, umbilicoplasty, abdominal dog ear revision	7
6	45 M	Sarcoma	L popliteal fossa wide local excision	R + L DIEA e2s popliteal a. R + L DIEV e2s popliteal v. (4 anastomoses) ^a	-	Delayed inset + skin graft Liposuction Flap thinning	34
7 ^b	31 F	Hemifacial microsomia	L facial contour deformity	R DIEA e2e superior thyroid a. R DIEV e2e retromandibular v. (2.5 mm coupler) + e2e external jugular v. branch (3 anastomoses)	-	Mandibular reconstruction with rib graft Osseointegrated bone anchors for ear prosthesis	2

Abbreviations: a; artery, ALT; anterolateral thigh, DIEA; deep inferior epigastric artery, DIEV; deep inferior epigastric vein, e2e; end-to-end, e2s; end-to-side, EDC; extensor digitorum communis, L; left, LSV; long saphenous vein, R; right, RTA; road traffic accident, SFA; superficial femoral artery, SIEV; superficial inferior epigastric vein, SSV; short saphenous vein, v; vein, vc; venae comitantes.

Footnotes: Except where stated, all microvascular anastomoses were hand-sewn.

^a Indocyanine green angiography was used to determine flap perfusion and pedicle patency following microvascular anastomoses.

^b DIEP flap was de-epithelised and buried since the recipient site only lacked volume.

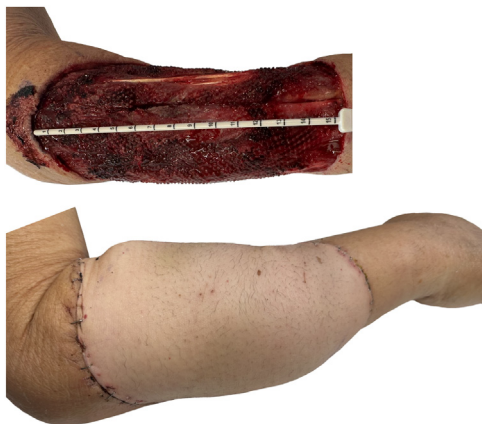


Figure 1. Post-sarcoma resection defect and subsequent reconstruction with a free deep inferior epigastric perforator flap of the right upper limb.

of additional operations over the next 14-years owing to the large size of the primary defect (which involved the left distal thigh, knee, and leg), multiple pregnancies, and personal choice. Over this period, tissue expanders were placed in three further locations – twice in the leg (x1 extrusion), once in the calf, and twice at the ankle. This patient further underwent an anterolateral thigh free-tissue transfer to the knee with subsequent placement of another tissue expander on three occasions (x1 extrusion, x1 infection), and two expanders within the thigh.

Discussion

In this case series, the DIEP flap proved to be very reliable, providing a large surface area of skin and soft-tissue volume for coverage of a wide variety of anatomical sites, with minimal donor site morbidity. The size of the DIEP flap made it easy to tailor the skin-paddle to fit into even the most complex of defects. Although we used a standard abdominoplasty approach for all cases, oblique, vertical, or customised paddle designs have previously been described.³ However, since flap length is often more important than width, a higher-placed or an asymmetric oblique abdominal scar may follow.

Understanding the vascular anatomy of the DIEP flap was important to avoid circulatory problems, as an extended flap beyond zone IV may be required. In one case we utilised indocyanine green angiography to determine flap perfusion and pedicle patency following anastomosis to the popliteal vessels. In the majority of cases, we based our flaps on both pedicles but paid particular attention to preserving the SIEVs and harvesting the maximum pedicle length possible. This allowed flexibility in skin-paddle design, flap orientation, and choice of recipient vessels. Similarly, this approach has been utilised in lower extremity reconstruction with successful outcomes.⁴ Moreover, another group has described the benefit of a bipedicle technique in prolonging survival of an extended flap beyond the angiosome of a single perforator, particularly in patients with a moderate-to-high body mass index who have sustained major degloving injuries.⁵ Although the extended latissimus dorsi (LD) flap can be used for large reconstructive defects, this is not without challenges – owing to the morbidity of a functional muscle sacrifice, conspicuous scarring, and often the most distal aspect of the flap (and most unreliable) may be the most critical part in covering important structures and so a combined LD supercharged with a groin flap pedicle may be required.⁶

One of the challenges of the DIEP flap is controlling its thickness. Although it is possible to undertake immediate flap thinning,⁷ we previously found this to be a risky strategy since our primary goal was to resurface the maximum area possible. Since most of our cases employed at least four vascular anastomoses we opted to prioritise successful wound healing over aesthetics – especially for

those with sarcoma as the aetiology for surgery. Once healed, secondary thinning procedures were then employed on an ambulatory basis.

As with any complex reconstruction, it was important to ensure that our patients were fully informed of the reasons for selecting a DIEP flap for their treatment. This made it easier for patients to understand and accept the need for tissue expansion of their skin-paddles, especially in the extremities, which was associated with considerable risk of extrusion and a prolonged post-operative journey.

When patients present with large, complex, extra-mammary defects, it is likely that they have already consulted a number of surgeons and may have exhausted multiple donor sites. Regardless of the anatomical site, our experience suggests that the DIEP flap should be used more often as a first-choice for reconstruction, especially if surgeons use both pedicles, avoid early thinning of the skin-paddle and consider using adjunctive procedures such as tissue expansion.

Conflict of interest statement

None.

Funding

None.

Ethical approval

None required.

References

1. Koshima I, Soeda S. Inferior epigastric artery skin flaps without rectus abdominis muscle. *Br J Plast Surg.* 1989;42(6):645–648.
2. Allen RJ, Treece P. Deep inferior epigastric perforator flap for breast reconstruction. *Ann Plast Surg.* 1994;32(1):32–38.
3. Guinier C, de Clermont-Tonnerre E, Tay JQ, Ng ZY, Jr Cetrulo CL, Lellouch AG. The deep inferior epigastric artery perforator flap: a narrative review on its various uses in non-breast reconstruction. *Ann Transl Med.* 2023;11(2):130.
4. Van Landuyt K, Blondeel P, Hamdi M, Tonnard P, Verpaele A, Monstrey S. The versatile DIEP flap: its use in lower extremity reconstruction. *Br J Plast Surg.* 2005;58(1):2–13.
5. Berkane Y, Giorgino R, Ng ZY, Dukan R, Lellouch AG. Alternative flap options for upper extremity reconstruction. *Hand Clin.* 2024;40(2):291–299.
6. Nikkhah D, Bhat W, Williams A, Bourke G. Upper limb salvage following near skeletalisation. *J Plast Reconstr Aesthet Surg.* 2012;65(6):836–837.
7. Lee SY, Seok MC, Park BY. Surgical considerations of one-stage reconstruction of large extremity defects using a thin deep inferior epigastric perforator flap. *Arch Plast Surg.* 2023;50(6):586–592.

Abdulla Ibrahim

Department of Plastic and Reconstructive Surgery, Royal Free Hospital, London NW3 2QG, United Kingdom

Department of Plastic and Reconstructive Surgery, St Thomas' Hospital, London SE1 7EH, United Kingdom

Petko Shtarbanov*

Division of Surgery and Interventional Science, University College London, Royal Free Hospital, London NW3 2QG, United Kingdom

Sam Astanehi

University of Central Lancashire, School of Medicine and Dentistry, Preston PR1 7BH, United Kingdom

Dariusz Nikkhah, Norbert Kang

Department of Plastic and Reconstructive Surgery, Royal Free Hospital, London NW3 2QG, United Kingdom

*Corresponding author.

E-mail address: petko.shtarbanov.20@ucl.ac.uk (P. Shtarbanov)